

Radicular cyst involving maxillary sinus: A report of rare case

Anusha R.L.^{1*}, Subhas Babu G², Priya Sara Thomas³, Renita L Castelino⁴

¹Reader and HOD, ²Professor and HOD, ³Senior Dental Review Officer, ⁴Reader, ^{1,2,4}Dept. of Oral Medicine and Radiology, ¹Century International Institute of Dental Science and Research Centre, Poinachi, Kerala, India ^{2,4}A.B Shetty Memorial Institute of Dental Sciences, NITTE University, Mangalore, Karnataka, India, ³National Health Insurance Company- Daman, Abu Dhabi, United Arab Emirates

***Corresponding Author: Anusha R.L.**

Email: dr.anusharl@gmail.com

Abstract

A pathological cavity lined by epithelium containing either fluid or semifluid substance is termed as cyst. The cyst associated with the teeth is called as odontogenic cyst. The periapical cyst or Radicular cyst is one among the odontogenic cysts which is most prevalent and associated with a dead or non-vital tooth. The epicentre of these cysts is mostly the apices of the involved non-vital teeth, however they may also be found on the lateral aspects of the roots in relation to lateral accessory root canals. They are inflammatory in nature. Most of the radicular cysts are small in size, but sometimes it can extend to displace maxillary sinus. In this situation, careful examination with the use of computed tomography (CT) helps you to distinguish the pathology arising from maxillary sinus itself or is it odontogenic origin causing displacement of the sinus. This article is highlighting the importance of advanced diagnostic aids like computed tomography in managing a rare case of massive radicular cyst involving the maxillary sinus in 52 year female which was treated surgically.

Keywords : Radicular cyst, Maxillary sinus, Computed tomography.

Introduction

A cyst is defined as an epithelial lined pathologic cavity that may contain fluid or a semisolid material. They are classified as Odontogenic from remnants of enamel epithelium, Non-odontogenic cyst from lines of fusion and Pseudocysts which are nonepithelial and lined only by connective tissue.¹ Most cysts of the jaws arise from odontogenic epithelium. Among all odontogenic cysts radicular cysts are the most prevalent accounting approximately 62% of in the jaw bones, which is a sequel of infection of pulp leading to necrosis of it.² The pathogenesis of this cyst is mainly due to the toxins produced by the micro-organisms which has infected the pulp. These toxins penetrate through the apex of the tooth leading to infection in the periapical region. This inflammation in turn stimulates the epithelial rests of Malassez which is typically seen in the periodontal ligament causing periapical granuloma or periapical cyst. Because of this, the tooth will be necrosed or non-vital.³ Based on the size of the radiolucency seen on the radiograph, it is classified as periapical granuloma which is usually less than 2 cms and if its more than that, we call it as periapical cyst.^{4,5} But exact size is not established as many authors have different opinions about it. Sometimes these cysts may reach large size causing destruction of the surrounding anatomical structures. Hereby we are reporting a rare occurrence of massive radicular cyst involving the maxillary sinus in a 52 year old female which was managed using the advanced radiographic aid that is computed tomography.

Case Report

A 52 year old female reported to the Department of Oral Medicine with complaints of swelling on the right middle one third of the face since a month which was associated with mild, intermittent, non-radiating type of pain and pus discharge. The swelling was gradually increased to

the present size over the time. The medical history was non-contributory. The head and neck examination revealed diffuse swelling in the right middle third of the face measuring approximately 3 by 2cms in size which was soft and tender. Left submandibular lymphadenopathy was also noticed. Whereas, a well-defined solitary oval intra oral swelling was noticed in the right maxillary posterior region which was causing bicortical expansion and it was soft and non-tender (Fig. 1). Intra orally, parulis was noticed at the apex of right maxillary first premolar, which was decayed and was mobile. The electric pulp vitality (EPT) showed that the right maxillary premolars and first molar were non-vital. Fine needle aspiration was negative. The Provisional diagnosis of chronic dentoalveolar abscess was proposed with the differential diagnosis of infected radicular cyst, odontogenic keratocyst.

The radiographic investigation (IOPA) showed well defined periapical radiolucency with root resorption of the premolars and molars. The floor of the right maxillary sinus couldn't be appreciated (Fig. 2). The maxillary occlusal radiograph showed thinning of the buccal cortex (Fig. 3). Panoramic Radiograph showed (Fig. 4) diffuse hazy uniform radiopacity in the right maxillary sinus and the floor of the sinus was unable to appreciate compared to the left side. Because we were not able to appreciate exact extension of the pathology we took help of the CT. Computed Tomography scan (Fig. 5) showed lesion was involving right maxillary sinus with the expansion of sinus and inferiorly invading the hard palate, superiorly eroding the orbital floor and medially nearing the nasal septum and the uniformity was suggestive of benign lesion: Mucocele of maxillary sinus or benign odontogenic tumor – ameloblastoma or adenomatoid odontogenic tumor. Surgical Excision of the lesion was done and sent for histopathological examination which revealed cystic lesion lined by 2-6 layers of non keratinized, flattened cells with a

hyperchromatic nucleus in most areas with thickening and proliferation of the epithelium in areas of inflammation. The connective tissue wall shows fibrous tissue with mainly chronic inflammatory cell infiltration, extravasated RBCs and hemosiderin pigment suggestive of radicular cyst. Hence the final diagnosis of radicular cyst involving right maxillary sinus was considered. The patient was showed significant healing on periodic follow up (Fig. 6).

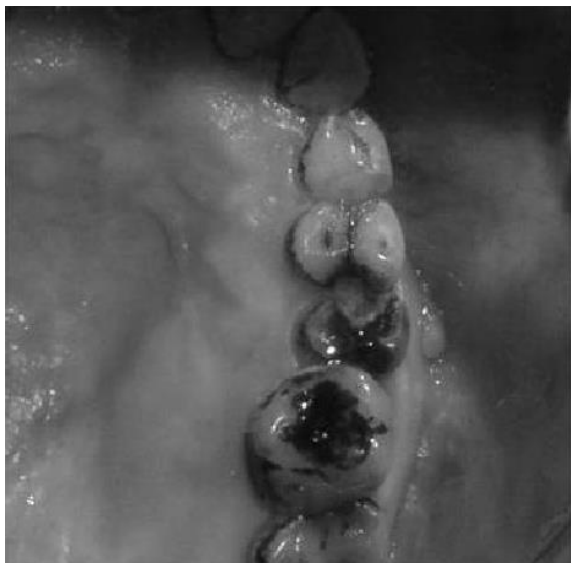

Fig. 1: A well-defined solitary, oval swelling noticed in the right maxillary posterior region intraorally

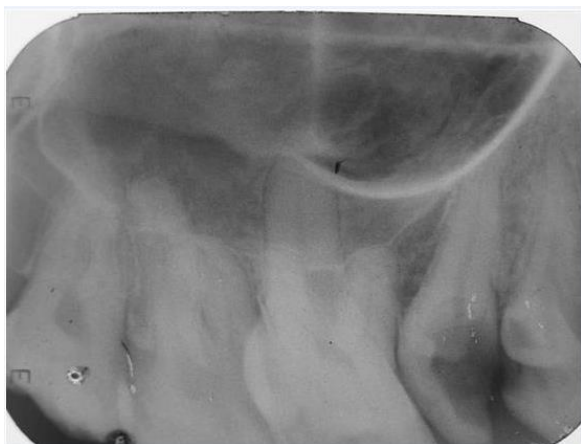


Fig. 2: IOPAR showing periapical radiolucency with loss of lamina dura and root resorption of the premolars, first and second molars. The floor of the maxillary sinus was unable to appreciate

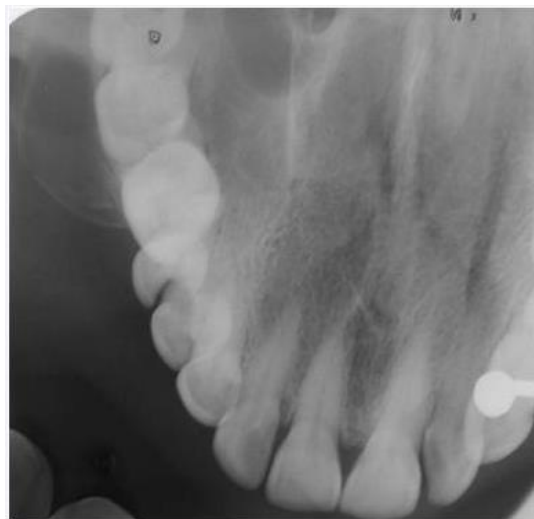


Fig. 3: The maxillary occlusal radiograph showed thinning of the buccal cortex

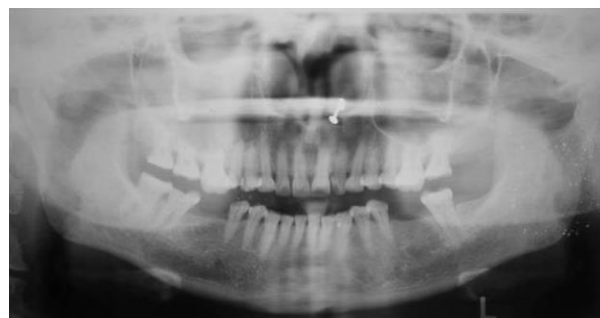

Fig. 4: Panoramic Radiograph showed diffuse hazy uniform radiopacity in the right maxillary sinus and the floor of the sinus was unable to appreciate compared to the left side

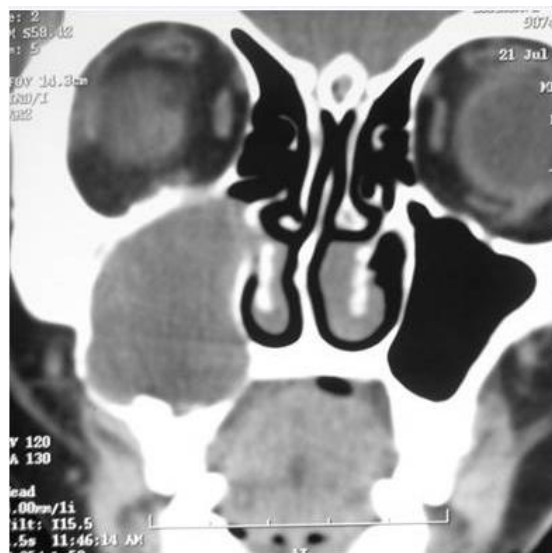

Fig. 5: Computed Tomography scan showed lesion was involving right maxillary sinus with the expansion of sinus and inferiorly invading the hard palate, superiorly eroding the orbital floor and medially nearing the nasal septum

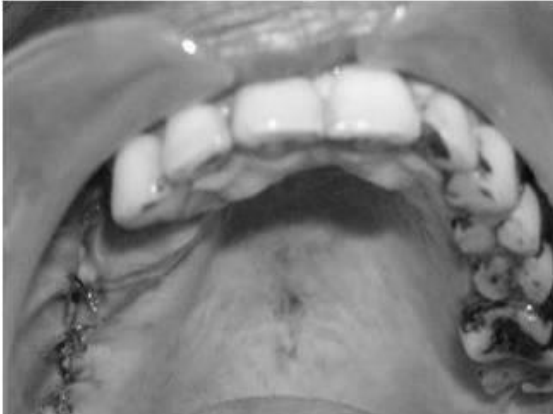

Fig. 6: Post-operative photograph

Discussion

The radicular cyst is an inflammatory odontogenic cyst seen at the root apex of dead pulp. These cysts are most common among other odontogenic cyst may be because of high incidence of pulpal pathology in the oral cavity. On intra oral examination, it will be caused either due to carious tooth or previous improperly restored tooth or traumatised teeth or seen in root canal failure cases.⁶ In the present case, the carious teeth was the prime cause for occurrence of the radicular cyst. They often remain asymptomatic even when very large. They are slow growing and may cause bony expansion as well as involvement of the adjacent teeth and root resorption.⁷ Similar clinical features were noticed in the case presented here with bicortical expansion, involvement of maxillary sinus, erosion of orbit and nasal septum as well as hard palate. Root resorption was also noticed.

Coming to the cysts of maxillary sinus, it can be divided into two types: one derived within the antra termed as “intrinsic” and if it is from odontogenic source it is called as “extrinsic”. The intrinsic type includes retention cyst and mucoceles whereas extrinsic type consists of radicular cysts followed by dentigerous cysts, keratocystic odontogenic tumours, residual radicular cysts and calcifying cystic odontogenic tumours in accordance to its prevalence.⁸ Here it was a case of extrinsic type.

Histopathologically it shows cystic lumen, lined with a thin epithelial lining supported by a fibrocellular connective tissue stroma, showing dense chronic inflammatory cell infiltrate with few cholesterol clefts.^{1,2,9}

Radiographically, the radicular cyst is a unilocular radiolucent lesion with well-circumscribed radiopaque sclerotic borders. Rarely does it present as multilocular. It is seen in the periapex with diameter more than 2 cms.^{4,5} But if it is large, it can protrude into the antrum, elevating its floor and causing it to appear as a thin plate of bone covering the lesion as seen in our case. This radiographic feature helps us to arrive whether the lesion is intrinsic or extrinsic type.¹⁰

The treatment modality varies from case to case. If it is smaller in size, removal of the microbial infection of root canal, thereby reducing the invasion of microbes into the periapical region can be carried out by root canal treatment.

If the infection is present in the periapical region, apicectomy can be carried out. If both fail, then extraction of that tooth followed by curettage of the periapical region is advised. But if the cyst is larger in size, we need to consider surgical procedures like enucleation, marsupialization.¹¹⁻¹³

Conclusion

Radicular being the most common one in tooth bearing area are generally smaller in size seen at the apex of the dead tooth. But rarely it can grow slowly to larger size causing destruction of adjacent vital structures. This article report a rare case of radicular cyst involving the maxillary sinus, eroding the orbital floor and encroaching the nasal septum and hard palate.

Conflict of Interest: None.

References

1. Rajendran R, Sivapathasundharam B. editors 2007. Shafer's Textbook of Oral Pathology. 5th ed. Elsevier.
2. Neville BW, Damm DD, Allen CM, Bouquot JE. In: Oral and Maxillofacial Pathology. 2005. 2nd ed. Pub: Saunders: an imprint of Elsevier.
3. Goaz PW, White SC. Oral radiology: principles and interpretation 3rd ed. St Louis, Mo: Mosby-Year Book, 1994.
4. Shear, M. Radicular and residual cysts. In: cysts of the oral region. 3rd edition. Briston: wright 1992; p 136-162.
5. Cawson, R.A, Odell E.W, Porter S. Cawson's essentials of oral pathology and oral Medicine; 7th edition. Churchill Livingstone 2002; p 1-2-121.
6. Quadri A, Keerthi R, Khan TA. Unusual Aggressive Large Radicular Cyst Invading Maxillary Sinus: A Case Report. *Int J Sci Stud* 2016;4(7):180-3.
7. Elango I, Devinder Kaur Baweja. Radicular Cyst Associated with Deciduous Molar Following Pulp Therapy: A Case Report. *Dent Res J* 2008;5:95-8.
8. MJ Amos, A Dalghous, J Alkhabuli, and KD Mizen. Massive maxillary radicular cyst presenting as facial fracture and abscess, a case report. *Libyan J Med* 2007;2:211-3.
9. Kandhari Archana, Shenoi Pratima. Surgical enucleation of radicular cyst using operating microscope: A case report & overview on use of microscope. *Endodontol* 2009;64-7.
10. Gurel K, Sanal SK, Gurel S. Two maxillary lesions containing bony/calcified shells. *Dentomaxillofac Radiol* 2009;38:296-300.
11. Nalini Ms, Balasubramanya S. Management of infected maxillary periapical (Radicular) cyst through Nasal Anthrostomy. *J Health Sci Res* 2016;7(2):58-62.
12. Balaji TS. Management of infected radicular cyst by surgical decompression. *J Conserv Dent* 2010;13:159-61.
13. Lagares, Juan J. Segura-Egea. Treatment of a Large Maxillary Cyst with Marsupialization, Decompression, Surgical Endodontic Therapy and Enucleation. *J Can Dent Assoc* 2011;77:b87.

How to cite this article: Anusha RL, Babu SG, Thomas PS, Castelino RL. Radicular cyst involving maxillary sinus: A report of rare case. *Int J Maxillofac Imaging* 2019;5(1):19-21.