



## Letter to Editor

# Can long-term bisoprolol therapy trigger hypothyroidism?

Nabeel Salim Mussian<sup>1\*</sup>, Ahmed Salem Basabbea<sup>1</sup>

<sup>1</sup>Hadhramout University, College of Medicine, Yemen



## ARTICLE INFO

### Article history:

Received 30-10-2024

Accepted 30-11-2024

Available online 13-12-2024

This is an Open Access (OA) journal, and articles are distributed under the terms of the [Creative Commons Attribution-NonCommercial 4.0 International](https://creativecommons.org/licenses/by-nc/4.0/), which allows others to remix, and build upon the work non-commercially, as long as appropriate credit is given and the new creations are licensed under the identical terms.

For reprints contact: [reprint@ipinnovative.com](mailto:reprint@ipinnovative.com)

Bisoprolol is a selective beta1-blocker medication utilized for the management of hypertension, congestive heart failure, and chronic stable angina. Its administration is associated with a reduction in morbidity and mortality following myocardial infarction, as well as a decreased risk of stroke and coronary artery disease in individuals with heart conditions.<sup>1,2</sup> Bisoprolol, along with other selective Beta1-blockers, can lead to negative impacts on the heart's contractions and rate. As a result, bisoprolol diminishes the oxygen demand of myocardial cells, alleviating the workload on the heart and subsequently contributing to a reduction in morbidity and mortality rates after a myocardial infarction.<sup>2</sup> Considering the data indicating that prolonged use of beta blockers influences serum levels of T4, T3, and rT3 in euthyroid patients suffering from ischemic heart disease,<sup>3</sup> it is pertinent to inquire whether long-term beta blocker therapy may trigger hypothyroidism in these individuals. In this context, we present a case involving a male patient who was diagnosed with ischemic heart disease and later developed hypothyroidism following prolonged treatment with bisoprolol.

A 68-year-old Yemeni man from Hadhramout Governorate with a known case of ischemic heart disease (IHD) on the following medications: Bisoprolol 5mg, Atorvastatin 20 mg and aspirin 100 mg for 6 years, presented to the outpatient clinic for medical fitness to do tooth extraction. History taking revealed no new

complaint except toothache. His clinical examination was unremarkable except for severe bradycardia with a heart rate of 32 beats per minute. Routine blood tests, including a complete blood count, blood urea, and random blood glucose levels, were found to be within normal limits. A 12-lead electrocardiogram revealed significant sinus bradycardia, with no evidence of inferior myocardial infarction (Figure 1).

The preliminary assessment indicated that the sinus bradycardia was likely a result of bisoprolol administration. A transthoracic echocardiogram revealed normal findings. To exclude alternative causes of sinus bradycardia, a thyroid function test (TFT) was performed. The results demonstrated a significantly elevated TSH level and a low FT4, which are indicative of primary hypothyroidism. Thyroid ultrasound was normal with negative anti-thyroperoxidase antibodies. Upon further inquiry regarding any prior thyroid conditions or related symptoms, the patient reported no history of thyroid disease; however, he noted cold intolerance over the last two months. A subsequent clinical examination revealed a delayed ankle reflex. The patient was subsequently admitted to the hospital. The dosage of bisoprolol was gradually reduced, and treatment with 50 microgram levothyroxine tablets was commenced. Upon discharge, the patient was in stable condition, exhibiting a heart rate of 68 beats per minute.

Some studies showed that that prolonged treatment with atenolol, alprenolol, and metoprolol leads to a significant reduction in serum triiodothyronine (T3) levels, primarily

\* Corresponding author.

E-mail address: [najjed2020@gmail.com](mailto:najjed2020@gmail.com) (N. S. Mussian).

through the inhibition of 5'-monodeiodinase, the enzyme responsible for converting thyroxine (T4) into the more biologically active T3.<sup>3,4</sup> Although the impact of prolonged bisoprolol treatment on serum T3 levels has not been thoroughly studied, it is logical to assume that it could lead to a comparable result. Consequently it is pertinent to inquire whether long-term bisoprolol therapy may trigger hypothyroidism in these individuals. Our patient developed hypothyroidism after almost 6 years of bisoprolol treatment. However, it remains unclear whether this association is coincidental or causal. Our patient had not undergone prior investigation for thyroid dysfunction; therefore, we hypothesized that the patient may have had subclinical hypothyroidism that progressed to overt hypothyroidism following prolonged treatment with bisoprolol.

This case carries significant clinical implications. It underscores that sinus bradycardia, which can occur as an adverse effect of bisoprolol, may obscure the presence of hypothyroidism. Therefore, it is prudent to consider the possibility of hypothyroidism in patients with a history of ischemic heart disease who experience severe bradycardia while on bisoprolol therapy. Could long-term bisoprolol therapy be considered a triggering factor for hypothyroidism?

### 1. Consent

Written informed consent was obtained from the patient for the publication of this case report.

### 2. Authors' Contribution

All authors contributed to the completion of this work. The final manuscript was read and approved by all authors.

### 3. Source of Funding

None.


### 4. Conflict of Interest


None.

### References

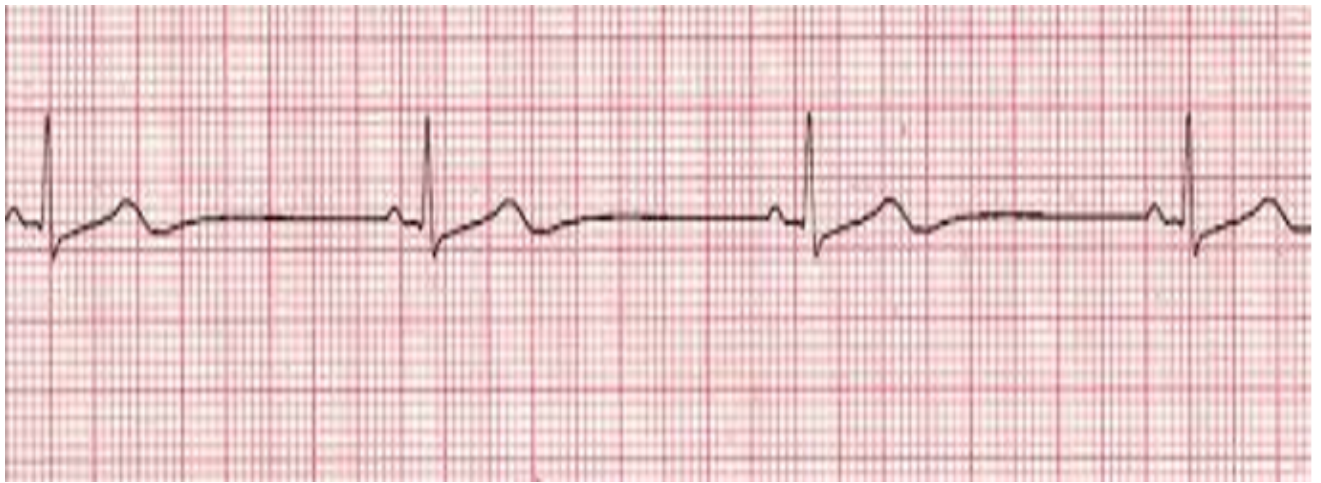1. Poldermans D, Boersma E, Bax JJ, Thomson IR, Paelinck B, Van De Ven L, et al. Dutch Echocardiographic Cardiac Risk Evaluation Applying Stress Echocardiography Study Group. Bisoprolol reduces cardiac death and myocardial infarction in high-risk patients as long as 2 years after successful major vascular surgery. *Eur Heart J*. 2001;22(15):1353–61.
2. Cruickshank JM. Beta-blockers and heart failure. *Indian Heart J*. 2010;62(2):101–11.
3. Perrild H, Pedersen F, Rasmussen SL, Jørgensen HJ, Skovsted L. Long-term alprenolol treatment affects serum T4, T3 and rT3 in euthyroid patients with ischaemic heart disease. *Acta Endocrinol (Copenh)*. 1984;105(2):190–3.
4. Pedersen F, Perrild H, Rasmussen SL, Skovsted L. Low T3-syndrome" in acute myocardial infarction—relationship to beta-adrenergic blockade and clinical course. *Eur J Clin Pharmacol*. 1984;26(6):669–73.

### Author's biography

**Nabeel Salim Mussian**, Associate Professor  <https://orcid.org/0009-0007-1989-0807>

**Ahmed Salem Basabbea**, Assistant Professor  <https://orcid.org/0009-0003-4147-857X>

**Cite this article:** Mussian NS, Basabbea AS. Can long-term bisoprolol therapy trigger hypothyroidism?. *Yemen J Med* 2024;3(3):276-278.



**Figure 1:** Showssinus bradycardia