



Short Communication

Transurethral band a rare aetiology of bladder outlet obstruction

Abdullahi Khalid^{1*}, Abubakar Isiyaku¹, John Solomon Marcus²,
Abubakar Sadiq Muhammad¹, Abdullah Abdulwahab Ahmed¹

¹Dept. of Surgery, Tefund Centre of Excellence in Urology and Nephrology, Institute of Urology, Sokoto, Nigeria

²Dept. of Surgery, Federal Medical Centre, Gusau, Nigeria



ARTICLE INFO

Article history:

Received 03-10-2024

Accepted 06-11-2024

Available online 13-12-2024

This is an Open Access (OA) journal, and articles are distributed under the terms of the [Creative Commons Attribution-NonCommercial 4.0 International](#), which allows others to remix, and build upon the work non-commercially, as long as appropriate credit is given and the new creations are licensed under the identical terms.

For reprints contact: reprint@ipinnovative.com

1. Introduction

Herein were two patients who presented to our facility with bladder outlet obstruction. The first case, a 38-year-old man presented with progressively worsening voiding and storage lower urinary tract symptoms (LUTS) of 18 months duration. The LUTS was preceded by a 6-week history of falling astride with a history suggestive of urethral injury. He declined the initial intervention because he was able to void. He had a history of urethral bourginage or dilation at a secondary health facility before presentation to our facility due to worsening voiding and storage LUTS and associated episode of urinary retention relieved by successful urethral catheterization. Physical examination and laboratory findings were unremarkable. The contrast imaging was inclusive (Figure 1A and 1B). The urethroscopy confirmed the diagnosis of the transurethral band located at the bulbar urethra (Figure 1C). He was treated endoscopically by septotomy with a satisfactory outcome (Figure 1D).

The second case, a 65-year-old man presented with voiding and storage LUTS of 2 years duration after open simple transvesical prostatectomy for Benign Prostatic Hyperplasia (BPH). There were associated recurrent episodes of urinary retention initially relieved

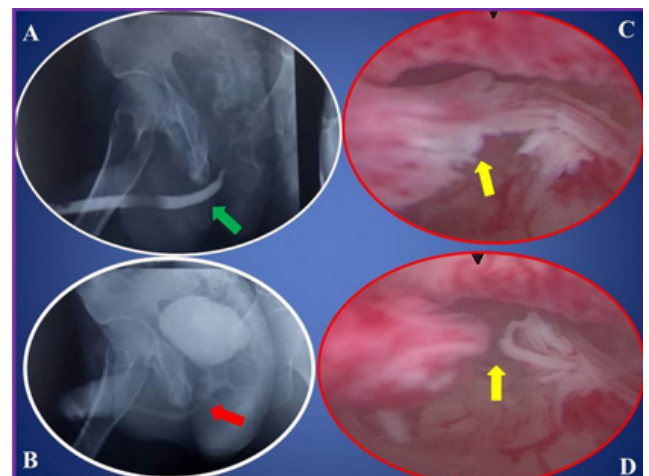


Figure 1: Anterior transurethral band located at the bulbar urethra
A: Retrograde urethrocystogram (RUCG) demonstrating normal anterior urethra (green arrow), B: Voiding cystourethrogram (VCUG) showing anterior and posterior urethra with a filling defect at proximal bulbar urethra (red arrow), C: Bulbar urethra band at commencement of septotomy using cold knife urethrotome (yellow arrow), D: Septotomy completed using cold knife incision (yellow arrow).

* Corresponding author.

E-mail address: kalabduka@gmail.com (A. Khalid).

by urethral catheterization but subsequently failed warranting suprapubic cystostomy. Physical examination and laboratory findings were unremarkable. The contrast imaging was inclusive (Figure 2A and 2B) but suggested poor prostatic urethral opening on the voiding cystourethrogram. The urethroscopy confirmed the diagnosis of the transurethral band located at the prostatic urethra (Figure 2C). He was treated endoscopically by the transurethral resection of the transurethral band with a satisfactory outcome.

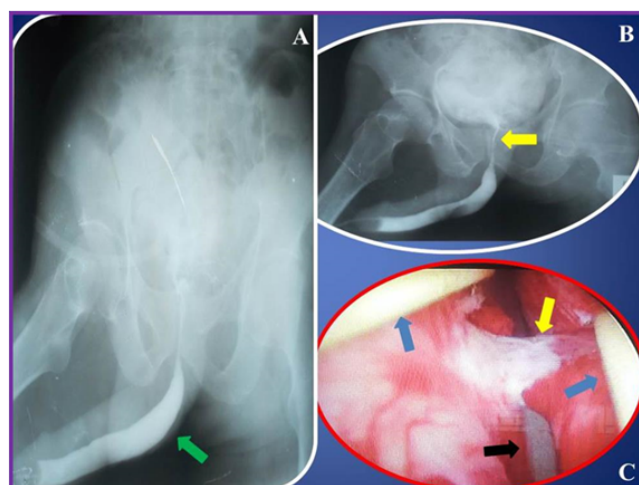


Figure 2: Posterior urethral band located at the prostatic urethra. **A:** Retrograde urethrocystogram (RUCG) demonstrating normal anterior urethra (green arrow), **B:** Voiding cystourethrogram (VCUG) showing anterior and posterior urethra with poor distension or opening of the prostatic urethra during voiding (yellow arrow), **C:** Prostatic urethra septum (yellow arrow), dividing the prostatic urethral lumen into cephalad and caudad parts with resection loop (blue arrows), and guide wire (black arrow), in situ respectively (yellow arrow) before commencement of transurethral resection of the septum.

The transurethral band is an abnormal fibromuscular structure that traverses the urethral lumen and attaches to the inner urethral wall. Its presence hampers the normal urethral compliance needed during the act of voiding. Consequently, it manifests with Lower urinary tract symptoms (LUTS) or bladder outlet obstruction which is difficult and indistinguishable from other infravesical pathologies such as urethral strictures and benign prostatic enlargement. It can be congenital or acquired and may involve any part of the entire urethral length. Due to its rarity, there is a paucity of literature on this clinical entity. There are cases of congenital septum reported in the literature to involve urogynecological organs such as the bladder and vaginal but not similar to transurethral band.^{1,2} The acquired transurethral band can result from trauma to the urethra or urethral instrumentation or surgery. Its diagnosis may require a combination of clinical evaluation, contrast imaging and endoscopy.

Contrast imaging is relatively cheap, readily available, and recommended by American Urological Association (AUA) guidelines for diagnosing urethral diseases such as urethra stricture, a possible differential diagnosis in index cases.³ It also has a role in the evaluation of urethral diverticulum, and stones amongst other differentials. Urethrography is regarded as the gold standard modality and has been documented to have sensitivity and specificity ranging from 75-100% and 72-97% in the diagnosis of urethral stricture respectively.⁴ Despite this it is poor in the assessment and diagnosis of transurethral band as shown in Figure 1A and 1B, likewise Figure 2A and 2B.

The role of endoscopy in contemporary urological practice cannot be overemphasized. Where available, it has a role in the diagnosis of common and rare infravesical pathologies namely urethral stricture, and benign prostatic enlargement among other aetiologies. This modality offers a superior advantage in the diagnosis of transurethral band because it provides real-time visual assessment of a urethral pathology which may otherwise have been missed by other investigative modalities including contrast imaging as shown in Figure 1C and 2C. Beyond its diagnostic potential, it can be extended in the same sitting for therapeutic purposes as seen in the index cases.⁵

The transurethral band is a rare cause of lower urinary tract symptoms and bladder outlet obstruction. It is a diagnosis of exclusion in patients with LUTS. The role of contrast imaging of the urethra is very limited in its diagnosis. The value of endoscopic urethral examination employing urethroscopy cannot be overemphasized in the complete evaluation of a patient with transurethral band, because it can serve both diagnostic and therapeutic roles and benefits in the same sitting.⁵

1.1. Learning points

1. Urologists should be aware of the transurethral band as an infravesical cause of lower urinary tract symptoms and bladder outlet obstruction.
2. They should have in mind transurethral band whenever the contrast imaging is inconclusive in a patient thought to have urethral strictures.
3. Endoscopic examination should be considered early whenever the contrast imaging is inconclusive in a patient thought to have urethral strictures.

2. Consent for Publication

Written informed consents were obtained from the patients for the publication of this manuscript and all accompanying images. The patients understand that while every effort is made to maintain the confidentiality of their identity, names, and initials, anonymity cannot be guaranteed.

3. Author's Contributions

All authors contributed to the completion of this work. The final manuscript was read and approved by all authors.

4. Source of Funding

None.


5. Conflict of Interest

None.

References

1. Laughlin VC, Derian GH, Boyd PF. Incomplete frontal septum of bladder complicated by congenital urethral valves and complete reduplication of upper left urinary tract. *J Urol*. 1952;68(1):289–96.
2. Amer MI, Ahmed MES, Ali AH. Congenital urethrovaginal fistula with transverse vaginal septum. *J Obstet Gynaecol Res*. 2016;42(8):1042–7.
3. Bayne DB, Gaither TW, Awad MA, Murphy GP, Osterberg EC, Breyer BN, et al. Guidelines of guidelines: a review of urethral stricture evaluation, management, and follow-up. *Transl Androl Urol*. 2017;6(2):288–94.
4. Maciejewski C, Rourke K. Imaging of urethral stricture disease. *Transl Androl Urol*. 2015;4(1):2–9.
5. Tveter KJ, Taksdal S, Mathisen W. Duplication of the male urethra treated by septotomy. A case report. *Scand J Urol Nephrol*. 1976;10(1):84–7.

Author's biography

Abdullahi Khalid, Consultant Urologist  <https://orcid.org/0000-0001-5984-3553>

Abubakar Isiyaku, Consultant Urologist

John Solomon Marcus, Principal Medical Officer

Abubakar Sadiq Muhammad, Consultant Urologist

Abdullah Abdulwahab Ahmed, Professor

Cite this article: Khalid A, Isiyaku A, Marcus JS, Muhammad AS, Ahmed AA. Transurethral band a rare aetiology of bladder outlet obstruction. *Yemen J Med* 2024;3(3):271-273.