

Content available at: <https://www.ipinnovative.com/open-access-journals>

IP Journal of Diagnostic Pathology and Oncology

Journal homepage: <https://www.jdpo.org/>

## Case Report

## Deciphering a diagnosis of crystallizing galactocoele on FNAC

Manjari Kishore <sup>1</sup>\*<sup>1</sup>Dept. of Pathology, GS Medical College and Hospital, Hapur, Uttar Pradesh, India

## ARTICLE INFO

## Article history:

Received 27-10-2024

Accepted 28-11-2024

Available online 13-12-2024

## Keywords:

Fibroadenoma

Milky-white aspirate

Crystals

Micelles

Cystic lesion breast

## ABSTRACT

Crystallizing galactocoele is a rare, benign cystic lesions of breast, usually noted in pregnant and lactating females. However, due to formation of crystals and being hard in long-standing cases, they may mimic malignancy sometimes. Correct and early diagnosis is mandatory for proper management of such cases.

We present such case in a 25-year-old female who presented with swelling in right breast during pregnancy and lactation. Clinically the lesion was firm, round and mobile. Sonography gave a diagnosis of fibroadenoma [BIRADS-III] and cytological evaluation was advised.

Fine needle aspiration yielded milky white aspirate and on subsequent evaluation of stained smears, a diagnosis of Crystallizing Galactocoele was made. The case report reiterates the importance of a simple and economical investigative modality, i.e., Fine needle aspiration cytology (FNAC) in making a diagnosis of such uncommon entity.

This is an Open Access (OA) journal, and articles are distributed under the terms of the [Creative Commons Attribution-NonCommercial-ShareAlike 4.0 License](#), which allows others to remix, tweak, and build upon the work non-commercially, as long as appropriate credit is given and the new creations are licensed under the identical terms.

For reprints contact: [reprint@ipinnovative.com](mailto:reprint@ipinnovative.com)

## 1. Introduction

Galactoceles are common benign cystic lesions of breast.<sup>1-3</sup> These can be seen often during pregnancy and lactation period. It has been noted that if such swelling remain over a period, then crystal formation may occur in these cystic lesions.<sup>2,3</sup> Sometimes the swelling can become so firm to hard that it can mimic malignancy on clinical and radiological evaluation.

Herein we report a rare case of Crystallizing Galactocoele in a 25-year-old female who developed this swelling during her later part of pregnancy. The present case justifies the role of minimally invasive procedure like FNAC which is also simple, fast and economical.

## 2. Case Presentation

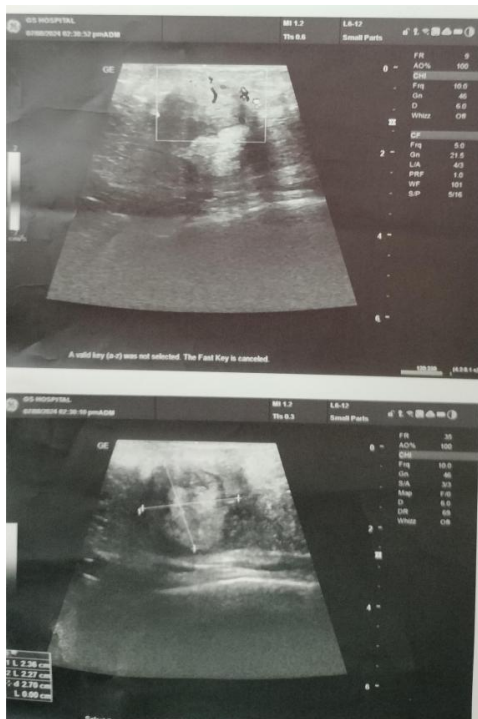
A 25-year-old female presented with swelling in the right breast for last 2 years. She noticed this swelling during her third trimester of pregnancy which has gradually increased in size over the period of last 2 years. The patient had this swelling during her pregnancy and lactational period. After delivery, she had been lactating since then. There was no history of trauma, or any kind of serous/bloody discharge from the nipple. On physical examination, a round to oval swelling was noted in the right breast in upper and outer quadrant. The swelling was mobile, non-tender, with smooth margin and no fixity to overlying skin and underlying chest. Nipple and areola were unremarkable. A clinical diagnosis of fibroadenoma was made.

The patient was advised for ultrasound breast and fine needle aspiration cytology from the swelling in the right breast. Ultrasound showed a well-defined heterogeneously hypoechoic to hyperechoic lesion of size measuring 2.3 x 2.2 cms in right breast at 10'o'clock position, 5-6 cm away

\* Corresponding author.

E-mail address: [drmanjarik@gmail.com](mailto:drmanjarik@gmail.com) (M. Kishore).

nipple-areola complex with minimal vascularity [BIRADS-III]. A possibility of Fibroadenoma was given.(Figure 1)

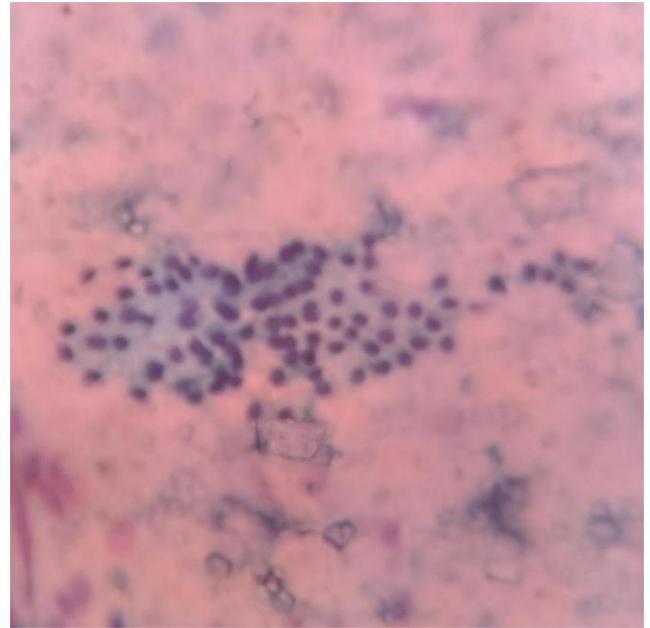


**Figure 1:** USG breast showing a well-defined mass in right breast, suggestive of Fibroadenoma.

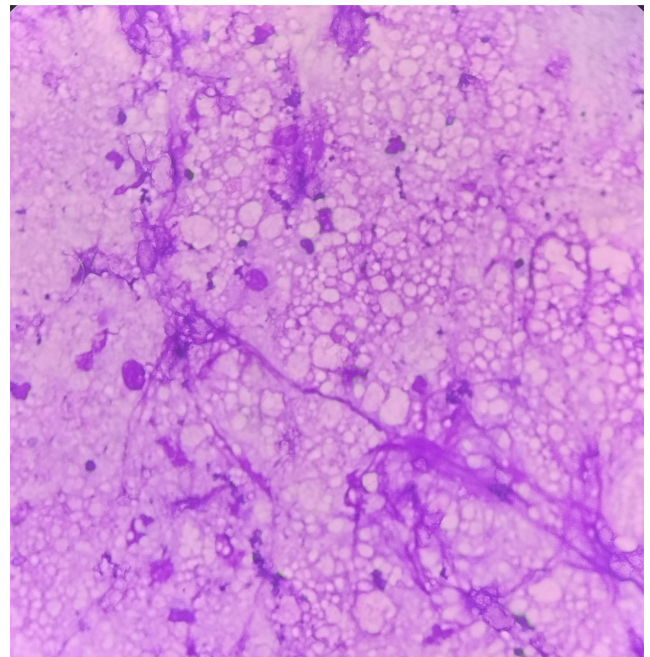


**Figure 2:** On FNAC, milky white material was aspirated.

Fine needle aspiration yielded milky white fluid with whitish flake like material(Figure 2). Smears were

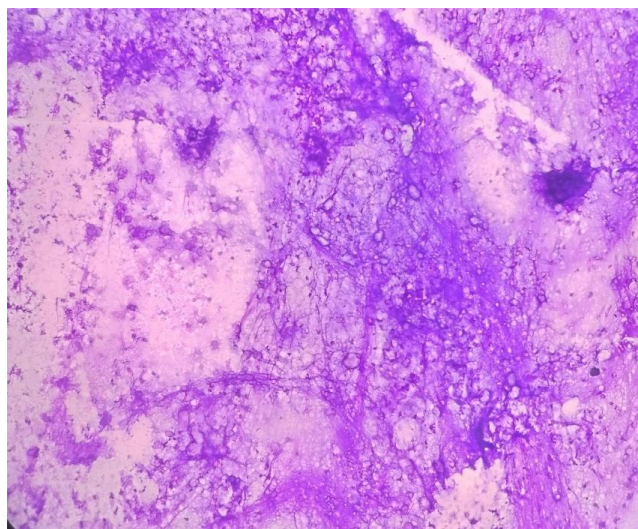


**Figure 3:** Smear showing group of benign ductal epithelial cells along with variably shaped crystals in background [Pap, 200X].

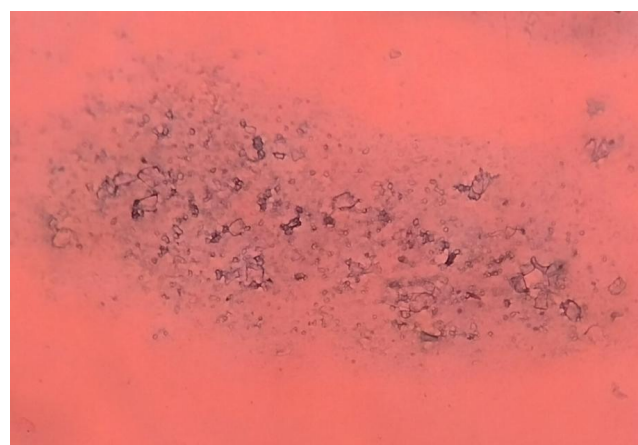

**Figure 4:** Smear showing amorphous granular proteinaceous material with frothy appearing micelles [Giemsa, 200X].

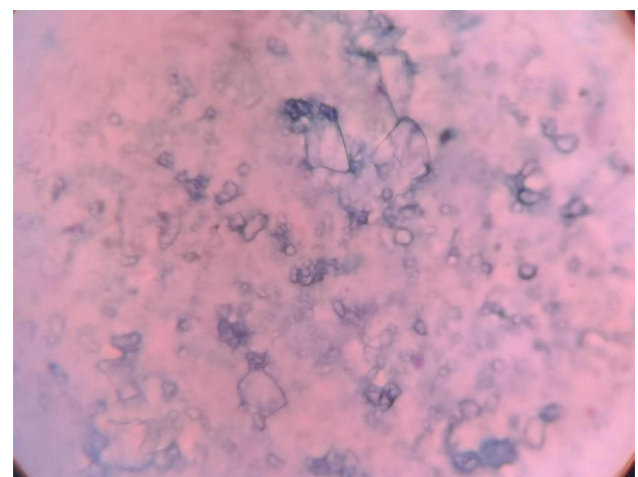




**Figure 5:** Smear showing granular amorphous background with scattered crystals [Giemsa, 100X].



**Figure 6:** Angulated & oval shaped crystals [Giemsa, 100X].



**Figure 7:** High power image showing variably sized crystals [Pap, 400X].

stained with Giemsa and Papanicolaou stain. Smears examined showed occasional groups of benign ductal epithelial cells along with few scattered bipolar nuclei (Figure 3. Background showed many macrophages along with amorphous granular proteinaceous material and frothy appearing micelles (Figures 4 and 5). Smears also showed angulated and oval shaped crystals along with foci of fibromyxoid stroma (Figures 6 and 7). Based on a detailed cytomorphological findings, a diagnosis of Crystallizing Galactocele was given.

### 3. Discussion

Swelling in the breast is a common finding in females in all age groups.<sup>2-4</sup> There are certain benign conditions which at times may mimic malignancy as well. These could be due to some internal physiological and pathological changes in the swelling. Such is a condition, termed as Galactocele of breast.<sup>2-4</sup> It is a benign cystic lesion, more frequently noted in pregnancy and lactation, as was noted in our patient. Why this entity is usually found in these groups of female? These could be numerous factors like, stimulation by prolactin during pregnancy, because of secretory breast epithelium, obstruction of lactiferous ducts, etc.<sup>3-6</sup> Rarely it can be noted in nulliparous women with features of prolactinaemia and also in post-menopausal women.<sup>3-7</sup>

Galactocele is basically a cystic collection of milk products that is lined by flattened cuboidal epithelium. Clinically, it presents as solitary, freely mobile lumps, usually in subareolar region. Due to physiological changes occurring in breast during pregnancy and lactation, its diagnosis becomes a challenging task.<sup>2-7</sup> Clinically, the lump gives an impression of fibroadenoma or lactating adenoma. Radiologically, depending on its contents, it can resemble an abscess, fibroadenoma, lactating adenoma or pregnancy-associated breast cancer.<sup>4-8</sup> Hence, a pathological diagnosis is always needed to confirm the diagnosis for an early intervention and waive off the undue tension in the patient.<sup>6-8</sup> With a proper pathological evaluation; using a very simple, minimally invasive and cost-effective diagnostic tool, i.e., FNAC, these entities can be rightly diagnosed.

Now comes the rare finding in the fact that, when these galactoceles become long-standing, crystallization can occur in these galactoceles. Very few cases of crystallizing galactocele of breast have been reported in literature on FNAC.<sup>2-11</sup> In all cases no definitive opinion could be given on clinical and radiological grounds.<sup>4-11</sup> Milky fluid acts as a bed for these crystal formation in long-standing cases. These secretions are composed of acid and neutral mucins, lipids, lysozyme, albumin, IgA, etc. Under acidic environment, supersaturation of these substances can lead up in formation of tyrosine or calcium crystals. Gradually they become more firm to hard and at times they can mimic malignancy as well.<sup>9-11</sup> Hence timely diagnosis is

warranted.

Grossly, it is a collection of inspissated lactational secretions, mainly fat and proteins. On cytological evaluation, we see dense amorphous proteinaceous material along with oval to angulated crystals of varying sizes and shapes. These crystals show birefringence on polarising microscopy. Special stains like per-iodic acid Schiff and von Kossa technique can be used to highlight these crystals.<sup>4,11</sup>

The course and outcome of crystallizing galactoceles is benign and smooth without requiring major surgical intervention. They resolve of their own, sometimes therapeutic aspiration may be required depending the degree of symptoms and internal crystallization.<sup>4-11</sup> We report this condition to highlight the detailed cytological features of crystallizing galactocoele and also advocating to keep it as an important differential diagnosis while evaluating a breast mass in pregnant & lactational age group.

#### 4. Conclusion

To conclude, during evaluation of breast swelling in pregnant and lactating females, differential diagnosis of crystallizing galactocoele should always be kept. A simple, minimally invasive diagnostic tool can help in making a diagnosis of this rare phenomenon, thereby waiving off unnecessary surgical intervention in the patient.

##### 4.1. Key points

1. Crystallizing galactocoele of breast (CGB) should be considered an important differential in evaluation of breast mass in pregnant and lactating females.
2. Only clinical and radiological findings are not sufficient to arrive at a definitive diagnosis.
3. Pathological diagnosis is mandatory.
4. Course and management of CGB is smooth without surgical intervention in majority of cases.

#### 5. Source of Funding

None.


#### 6. Conflict of Interest

None.

#### References

1. Hassan MJ, Sharma M, Khetrpal S, Khan S, Jetley S. Cytological diagnosis of crystallizing galactocoele - report of an unusual case. *Breast Dis.* 2018;37(3):159–61.
2. Jyothi K, Baliga V. Crystallizing Galactocoele -A cytological dilemma: case report. *Sch J App Med Sci.* 2015;3:129–59.
3. Shetty A, Narasimha A, Jayalakshmi VJ. Crystallizing galactocoele: Report of a rare variation. *Breast Dis.* 2016;36(2-3):111–4.
4. Zaman S, Gupta R, Gupta S. Crystallizing galactocoele of the breast masquerading as a malignancy: Report of a rare case with cytological diagnosis. *Diagn Cytopathol.* 2022;50(8):236–9.
5. Varshney B, Bharti JN, Saha S, Sharma N. Crystallising galactocoele of the breast: a rare cytological diagnosis. *BMJ Case Rep.* 2021;14(5):242888.
6. Singla T, Singla G, Singla S, Singh M. FNAC Diagnosis of Crystallizing Galactocoele- An Unusual Presentation. *J Cytol.* 2020;37(3):149–50.
7. Umasankar P, Priya UL, Sideeqe A. Crystallizing Galactocoele: A rare entity-report of two cases. *Diagn Cytopathol.* 2018;46(10):873–5.
8. Taib NA, Rahmat K. Benign Disorders of the Breast in Pregnancy and Lactation. *Adv Exp Med Biol.* 2020;1252:43–51.
9. Gurumurthy RY, Shankar NS. Crystallizing galactocoele-histopathological diagnosis of an enigmatic entity. *Int J Curr Adv Res.* 2017;6:2496–9. doi:DOI: <http://dx.doi.org/10.24327/ijcar.2017.2499.0036>.
10. Raj S, Baunhiyal A, Shah S, Thapliyal N. Axillary crystallizing galactocoele masquerading malignancy: A rare case report and review of literature. *IP Arch Cytol Histopathol Res.* 2021;6(3):142–4.
11. Ang WGB, Ananta MG, Yan Z. Approach to the growing breast lump during lactation. *BMJ Case Rep.* 2023;16(8):254750.

#### Author's biography

**Manjari Kishore**, Associate Professor  <https://orcid.org/0000-0003-0801-7651>

**Cite this article:** Kishore M. Deciphering a diagnosis of crystallizing galactocoele on FNAC. *IP J Diagn Pathol Oncol* 2024;9(4):254-257.