

Content available at: <https://www.ipinnovative.com/open-access-journals>

IP Journal of Diagnostic Pathology and Oncology

Journal homepage: <https://www.jdpo.org/>

Case Report

Choriocarcinoma induced thyrotoxicosis

Chaitanya Munshi^{1*}, Murtaza Bohra², Shraddha Mahindra¹, Kishor Deshpande¹

¹Dept. of Laboratory Medicine, National Cancer Institute, Nagpur, Maharashtra, India

²Dept. of Medical Oncology, National Cancer Institute, Nagpur, Maharashtra, India



ARTICLE INFO

Article history:

Received 03-10-2024

Accepted 08-11-2024

Available online 13-12-2024

Keywords:

HCG (Human chorionic gonadotropin)

TSH (Thyroid stimulating hormone)

GTN (Gestational trophoblastic neoplasm)

Choriocarcinoma

Hyperthyroidism 1

ABSTRACT

Paraneoplastic hyperthyroidism, although uncommon, is a known phenomenon in Germ cell tumors. Trophoblastic thyroidian hyperfunction is a complication of Choriocarcinoma.

Choriocarcinoma is associated with high levels of Human Chorionic Gonadotropin (HCG). HCG is a glycoprotein produced by the placenta. It is structurally almost identical to Thyroid Stimulating Hormone (TSH). At high levels HCG can stimulate the TSH receptor causing Hyperthyroidism.

This is a case of a 25 year old female diagnosed with metastatic Choriocarcinoma and concomitant Hyperthyroidism. After the first cycle of chemotherapy, the concentration of HCG decreased significantly. Simultaneously patient's thyroid function test values normalized dramatically and the patient became euthyroid.

The two known causative mechanisms are, enhanced thyrotropic activity by HCG and the molecular mimicry between HCG and TSH which causes release of Thyroxine from the thyroid gland.

This is an Open Access (OA) journal, and articles are distributed under the terms of the [Creative Commons Attribution-NonCommercial-ShareAlike 4.0 License](#), which allows others to remix, tweak, and build upon the work non-commercially, as long as appropriate credit is given and the new creations are licensed under the identical terms.

For reprints contact: reprint@ipinnovative.com

1. Introduction

Choriocarcinoma is a malignant disease arising from the placenta and trophoblastic villi. Gestational trophoblastic neoplasia (GTN) occur in 1 : 40,000 pregnancies and are more common in South East Asia as compared to Europe and North America.

Invasive mole and Choriocarcinoma are the most common GTN, producing high levels of HCG and are known to be responsive to chemotherapy.

HCG is used as a marker for diagnosis, monitoring the therapy and follow up of these patients. HCG is a glycoprotein produced by placenta and has an intrinsic thyroid stimulating activity.¹ Structural resemblance of TSH and HCG causes release of Thyroxine from the thyroid gland.

The first case of Hydatidiform mole and Thyrotoxicosis was reported in 1955 by Tisne and colleagues.²

Since then several cases of Gestational trophoblastic disease induced Hyperthyroidism have been reported in literature.³⁻⁸

2. Case Presentation

A 25 year old female, diagnosed case of GTN (Choriocarcinoma) was admitted to our tertiary cancer care centre for chemotherapy and supportive care.

2.1. Case history

Patient was G2P0A1 (Obstetric score). She had history of one abortion more than a year back. No other details were available. She presented to us with complaints of pain in abdomen, bleeding per vaginum (PV) and breathlessness.

* Corresponding author.

E-mail address: chaitanyamunshi@gmail.com (C. Munshi).

2.2. General examination

1. General condition was moderate.
2. Patient was afebrile.
3. Pulse 142/min, BP 110/70,
4. Respiratory rate 20/min,
5. SpO₂ 98 % on room air.

2.3. Systemic examination

Cardiovascular(CVS) and Central Nervous System(CNS) examination were normal.

2.4. Radiological investigations

Revealed extensive bilateral metastatic nodules in lung Parenchyma (Figure 1).

PET CT revealed hypermetabolic, heterogeneously enhancing solid cystic mass lesion involving the uterus and cervix. (Site of primary malignancy) (Figure 1).

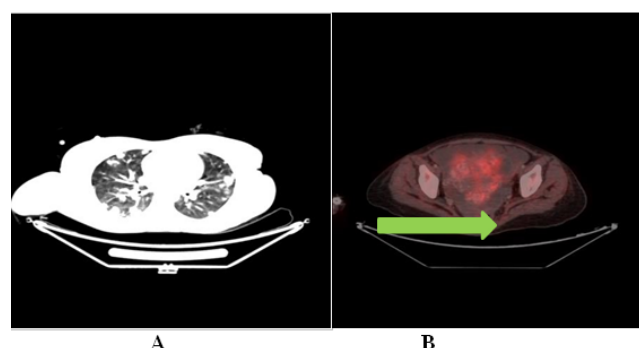


Figure 1: Radiological Investigations. **A):**CT lung (Extensive bilateral metastatic nodules in lung parenchyma)

B):PET-CT(Hypermetabolic, heterogeneously enhancing solid cystic mass lesion involving the uterus and cervix. (Site of primary malignancy)).

2.5. CT Brain

Normal. No evidence of metastasis.

2.6. Blood Investigations revealed: (Table 3)

1. Serum Beta-HCG level was 6,88,748 mIU/ml (Normal range: 0 to 10 mIU/ml).
2. Thyroid function tests showed Serum T3 to be 6.30 nmol/l (Normal range: 0.92 to 2.33 nmol/l).
3. Serum T4 was 975 nmol/l (Normal range: 62 to 120 nmol/l).
4. Serum TSH was less than 0.25 uIU/ml (Normal range: 0.25 to 5.00 uIU/ml).

Other Haematological and Biochemical parameters like Complete Blood Count(CBC), Kidney function tests (KFT) and liver function tests (LFT) were all within normal limits.

2.7. Diagnosis

Patients Score 35 –Impending thyroid storm (Table 2)

Final Diagnosis: Gestational trophoblastic neoplasm (Chorio carcinoma, High Risk FIGO grade III).

(Table 1) with pulmonary metastases and hyperthyroidism (Impending Thyroid storm) (Table 2).

2.8. Treatment aspect

Chemotherapy was started: EMACO Day 1 and Day 8, 6 cycles.

Patient had Biochemical as well as Clinical Hyperthyroidism. Burch- Wartofsky score for patient was 35 which indicated impending thyroid storm. (Table 2)

Patient was put on Neomercazol 5 mg BD. Other supportive care was initiated.

Patients Beta-HCG levels were monitored weekly. There was marked decline in serum BHCG levels. At one month, Beta-HCG was 711 mIU/ml and Thyroid function normalized. T3 was 2.0 nmol/l, T4 was 101 nmol/l and TSH was 1.80 uIU/ml. (Table 3)

Patient's Anti thyroid medication i.e Neomercazol was stopped. Patient was monitored on monthly basis for serum B HCG levels. At one year follow up, Patients Beta-HCG level was 0.3 mIU/ml.

Patient was Euthyroid without any anti thyroid medication and doing well.

3. Discussion

Choriocarcinoma is the most aggressive form of GTN, characterized by vascular invasion and wide spread metastases. The most common metastatic sites are lung (80 %), vagina (30 %) brain (10 %) and liver (10 %).⁹

The pathophysiology of thyroid disease in GTN is related to the secretion of HCG from the trophoblastic tissue. The effect of HCG on thyroid gland is thought to occur due to molecular mimicry between HCG and TSH.

The two known mechanisms are increased thyrotropic activity by HCG and structural resemblance with TSH causing release of thyroxine from thyroid gland.¹⁰

Cave and colleagues¹¹ examined serum from patients with metastatic choriocarcinoma. By using gel filtration, a single peak coinciding with HCG was demonstrated. This suggested that the thyrotropin of choriocarcinoma was HCG. The similarity in structure between HCG and TSH can cause cross reactivity of each receptor.

Various studies have shown prevalence of hyperthyroidism with high levels of HCG. Lockwood et al. found suppressed TSH in 100 % specimen with HCG concentration > 40,000 IU/l.¹² Glinioer estimated that any

Table 1: Prognostic scoring index for GTN (NCCN guidelines version 3.2020).

Prognostic Factor	Risk Score			
	0	1	2	4
Age (Yrs)	< 40	≥ 40	-	-
Antecedent pregnancy	Hydatidi form mole	Abortion	Term Pregnancy	
Interval from Index Pregnancy (months)	< 4	4 to 6	7 to 12	> 12
Pretreatment HCG levels Iu/l	< 103	103 to < 104	104 to 105	≥ 105
Largest tumor size including uterus (cm)	< 3	3 to 5	> 5	-
Site of Metastases	Lung	Spleen,Kidney	GIT	Brain,Liver
No. of metastases identified	0	1 to 4	5 to 8	> 8
Previous Failed chemotherapy	-	-	Single drug	Two or more drugs
Total Score	12			

FIGO Score: Low risk < 7 , High Risk > 7

Table 2: BurchWartofsky point scale.

Temperature ()		Cardiovascular dysfunction	
99-99.9	5 points	Tachycardia (beats/min)	
100-100.9	10	99-109	5
101-101.9	15	110-119	10
102-102.9	20	120-129	15
103-103.9	25	130-139	20
≥104.0	30	≥140	25
		Atrial fibrillation	10
Central Nervous System effects		Heart Failure	
Absent	0	Mild (pedal edema)	5
Mild(agitation)	10	Moderate (bibasilar rales)	10
Moderate(delirium, psychosis, extreme lethargy)	20	Severe (pulmonary edema)	15
Severe (seizure, coma)	30		
Gastrointestinal-hepatic dysfunction		Precipitant history	
Moderate(diarrhea, nausea/vomiting, abdominal pain)	10	Positive	0
Severe (unexplained jaundice)	20	Negative	10
Total: <25, storm unlikely, 25-45, impending storm, >45, thyroid storm			

Table 3: Summary of HCG, TFT measurements.

Test	Ref.Value s	At presentation	One month	Six months	One year
B-HCG	0 to 10 mIU/ml	6,88,748	711	130	0.3
TSH	0.25 to 5.00 uIU/ml	Less than 0.25	1.80		1.14
T3	0.92 to 2.33 nmol/l	6.30	2.00		1.2
T4	62 to 120 nmol/l	975	101		66
F T3	2.30 to 4.20 pg/ml				3.26
F T4	0.89 to 1.76 ng/dl				0.81
Neomercazole		Neomercazole 5 mg BD	Neomercazole 5mg BD	Without Neomercazole	Without Neomercazole

increase 10,000 Iu/l for HCG will be followed by increase in FT4 by

ng/dl and reduction in TSH by 0.1 mIU/ml.^{13–15}

Although there is no precise threshold at which HCG causes Thyrotoxicosis, thyroid function should be measured in all patients with HCG > 50,000 Iu/L regardless of the cause of elevation.^{16,17}

Choriocarcinoma is sensitive to chemotherapy and choice of regimen is based on WHO (World Health Organisation) Prognostic Scoring System and the International Federation of Gynecology and Obstetrics (FIGO) anatomic staging system.

In patients having Biochemical and Clinical Hyperthyroidism, Burch- Wartofsky score should be assessed for presence of Thyroid storm and treatment should be initiated accordingly. Unless there are symptoms of severe thyrotoxicosis, treatment of hyperthyroidism is not needed, as chemotherapy for Choriocarcinoma should effectively bring down the HCG levels alleviating the hyperthyroidism.

4. Conclusion

1. Choriocarcinoma is not only associated with Hyperthyroidism, but also can induce thyroid storm.
2. GTD induced thyroid storm should be considered in any female of child bearing age with signs and symptoms of Thyrotoxicosis.
3. High levels of HCG are directly proportional to the clinical manifestation of Hyperthyroidism.
4. Thyroid function must be measured in all patients with HCG levels > 50,000 Iu/L.
5. In patients having Biochemical and clinical hyperthyroidism, Burch- Wartofsky score should be assessed for presence of Thyroid storm and treatment should be initiated accordingly.
6. Unless there are symptoms of severe thyrotoxicosis, Treatment of hyperthyroidism is not initiated.
7. Thyroid function is expected to return to normal once the HCG levels come down.
8. Awareness of this condition is important for diagnosis and treatment of GTD.
9. GTD induced thyroid storm should be considered in any female of child bearing age with signs and symptoms of thyrotoxicosis.

5. Source of Funding

None.

6. Conflict of Interest

None.

References

1. Clain HJ, Pannall PR, Kotasek D, Norman RJ. Choriogonadotropin-mediated thyrotoxicosis in a man. *Clin Chem*. 1991;37(6):1127–31.
2. Tisne L, Barzelatto J, Stevenson C, Am J Pathol. Estudio de function tireoldeaduranteleestado gravid- puerperalconelyodoradioactivo. *Bot S*. 1955;20:246.
3. Nisula BC, Taliadouros GS. Thyroid function in gestational trophoblastic neoplasia: Evidence that the thyrotropic activity of chorionic gona- dotropin mediates the thyrotoxicosis of choriocarcinoma. *Am J Obstet Gynecol*. 1980;138(1):77–85.
4. Myers WP. An analysis of medical problems in cancer. *Med Clin North Am*. 1961;45:563–83.
5. Cohen JD, Utiger RD. Metastatic choriocarcinoma associated with hyperthyroidism. *J Clin Endocrinol Metab*. 1970;30(4):423–9.
6. Morley JE, Jacobson RJ, Melamed J, Hershman JM, 1. Choriocarcinoma as a cause of thyrotoxicosis. *Am J Med*. 1976;60(7):1036–40.
7. Odell WD, Bates RW, Rivlin RS. Increased thyroid function without clinical hyperthyroidism in patients with choriocarcinoma. *J Clin Endocrinol Metab*. 1963;23:658–64.
8. Miyai K, Tanizawa O, Yamoto T, Azukizawa M, Kawai Y. Pituitary-thyroid function in trophoblastic disease. *J Clin Endocrinol Metab*. 1976;42(2):254–9.
9. Zanetta G, Maggi R, Colombo M, Bratina G, Mangioni C, et al. Choriocarcinoma coexistent with intrauterine pregnancy: two additional cases and a review of the literature. *Int J Gynecol Cancer*. 1997;7(1):66–77.
10. Pereira JVB, Lim T. Hyperthyroidism in gestational trophoblastic disease-a literature review. *Thyroid Res*. 2021;14(1):1.
11. Cave WT, Dunn JT. Choriocarcinoma with hyperthyroidism: Probable identity of the thyrotropin with human chorionic gonadotropin. *Ann Intern Med*. 1976;85(1):60–3.
12. Lockwood CM, Grenache DG, Gronowski AM. Serum human chorionic gonadotropin concentrations greater than 400,000 IU/L are invariably associated with suppressed serum thyrotropin concentrations. *Thyroid*. 2009;19(8):863–8.
13. Cooper DS, Braverman LE. Trophoblastic tumor in Werner Ingbar's. The thyroid: A fundamental and clinical text. Philadelphia, Lippincott Williams Wilkins; 2013. p. 409–13.
14. Meister L, Hauck PR, Graf H, Carvalho GA. Hyperthyroidism due to secretion of human chorionic gonadotropin in a patient with metastatic choriocarcinoma. *Arq Bras Endocrinol Metabol*. 2005;49(2):319–22.
15. Walkington L, Webster J, Hancock BW, Everard J, Coleman R. Hyperthyroidism and human chorionic gonadotropin in gestational trophoblastic disease. *Br J Cancer*. 2011;104(11):1665–9.
16. Oosting SF, Hass ECD, Links TP, Bruin DD, Sluiter WJ, Jong IJD, et al. Prevalence of paraneoplastic hyperthyroidism in patients with metastatic non-seminomatous germ-cell tumors. *Ann Oncol*. 2010;21(1):104–8.
17. Heda P, Cushing G. Testicular choriocarcinoma presenting as hyperthyroidism. *Am J Med*. 2013;126(11):1–2.

Author's biography

Chaitanya Munshi, Consultant

Murtaza Bohra, Consultant Medical Oncologist

Shraddha Mahindra, Junior Consultant

Kishor Deshpande, Consultant

Cite this article: Munshi C, Bohra M, Mahindra S, Deshpande K. Choriocarcinoma induced thyrotoxicosis. *IP J Diagn Pathol Oncol* 2024;9(4):247–250.