

Content available at: <https://www.ipinnovative.com/open-access-journals>

Indian Journal of Pathology and Oncology

Journal homepage: [www.ijpo.co.in](http://www.ijpo.co.in)**Case Report****Subretinal neurocysticercosis: A lesser explored manifestation of a fairly common condition**Arpit Varshney<sup>1</sup>, Ruquiya Afrose<sup>1</sup>, Gourik Gangopadhyay<sup>1</sup>, Sayeedul Hasan Arif<sup>1</sup>, Avadh Vihari Lal Sharma<sup>1\*</sup><sup>1</sup>Dept. of Pathology, Jawaharlal Nehru Medical College, AMU, Aligarh, Uttar Pradesh, India**ARTICLE INFO***Article history:*

Received 09-10-2024

Accepted 14-11-2024

Available online 12-12-2024

*Keywords:*

Subretinal cysticercosis

Photophobia

Tapeworm

**ABSTRACT**

Cysticercosis in humans is the most common parasitic zoonotic diseases worldwide with an estimated prevalence greater than 50 million persons infected. Cysticercosis is the infection caused by the larval form of the cestode tapeworm *Taenia solium*, also termed as *Cysticercosis cellulosae*. It is the most common parasitic cerebral infection encountered in worldwide neurosurgical practice. The condition has been estimated to affect nearly 2.5 to 8.3 million people annually accounting for a global burden of 2.8 million disability adjusted life years. Endemic to all continents, the condition is particularly more prevalent in Central and South America, India, Africa and China. In India, the ocular adnexa has been found to be the most common site of neurocysticercosis but the condition is underreported and not diagnosed until full-fledged retinal detachment or blindness sets in. Cysticercosis must be kept in the mind in patients presenting with decreased vision, photophobia, redness of the eye as is notorious for the chronicity.

This is an Open Access (OA) journal, and articles are distributed under the terms of the [Creative Commons Attribution-NonCommercial-ShareAlike 4.0 License](https://creativecommons.org/licenses/by-nc-sa/4.0/), which allows others to remix, tweak, and build upon the work non-commercially, as long as appropriate credit is given and the new creations are licensed under the identical terms.

For reprints contact: [reprint@ipinnovative.com](mailto:reprint@ipinnovative.com)**1. Introduction**

Cysticercosis is the infection caused by the larval form of the cestode tapeworm *Taenia solium*, also termed as *Cysticercosis cellulosae*. It is the most common parasitic cerebral infection encountered in worldwide neurosurgical practice.<sup>1</sup> In India, the ocular adnexa has been found to be the most common site of neurocysticercosis<sup>2–4</sup> but the condition is underreported and not diagnosed until full-fledged retinal detachment or blindness sets in. The cyst can lodge itself either in the extraocular tissues including eyelid, subconjunctival space, extraocular muscles, optic nerve or in the intraocular tissues including the anterior chamber, vitreous chamber and the subretinal space.<sup>5,6</sup> According to a previous case reports, 35% of the cysts were found to be occurring in the subretinal space, 22% in the vitreous chamber, 22% in the subconjunctival space, 5% in

the anterior chamber and only 1% in the bony orbit.<sup>7</sup> The rupture or death of the cyst with the release of chemical toxins induces severe inflammatory reaction and can cause severe vision loss.<sup>8</sup> Early diagnosis of the condition is of paramount importance as it can lead to progressive painless blindness within 3-5 years. Therefore early surgical removal is the treatment of choice.<sup>9</sup>

Hereby, we present an interesting case of a 27 year old male who presented to Jawaharlal Nehru Medical College and Hospital, Aligarh Muslim University, with floaters and diminished vision with diagnostic dilemma that was solved by prompt and early histopathological examination.

**2. Case Report**

A 25 year old male presented to the Ophthalmology OPD of Jawaharlal Nehru Medical College, Aligarh Muslim University with decreased vision, photophobia, redness of the Right eye along with progressively worsening headache

\* Corresponding author.

E-mail address: [sharmaavadh03@gmail.com](mailto:sharmaavadh03@gmail.com) (A. V. L. Sharma).

for the past 2 months and floaters for the past 14 days. There was no history of seizures. The patient had a history of consuming cut fruit and vegetable salad regularly from a local vendor for the past 5 years. On examination, Best Corrected Visual Acuity (BCVA) was found out to be 6/24 in OD and 6/12 in the OS. On Slit Lamp Examination, Anterior Chamber was found to be unremarkable, Vitreous Chamber showed the presence of 2+ cells in OD. A 4.5 X 3.5 disc diameter colloidal cyst was identified in the inferotemporal quadrant of the retina in the OD. However, no scolex or hook like structure could be visualized clearly. MRI Brain was also largely unremarkable other than vague high intensity areas of calcification in the periventricular region. Complete Blood Count showed eosinophilia, while the ESR of the patient was increased. The patient was maintained on Corticosteroid therapy for 2 weeks, following which Pars Plana Vitrectomy was done. A transparent cystic structure was removed and was immediately sent to the histopathology laboratory of JNMCH, AMU in 10 % Neutral Buffered Formalin.

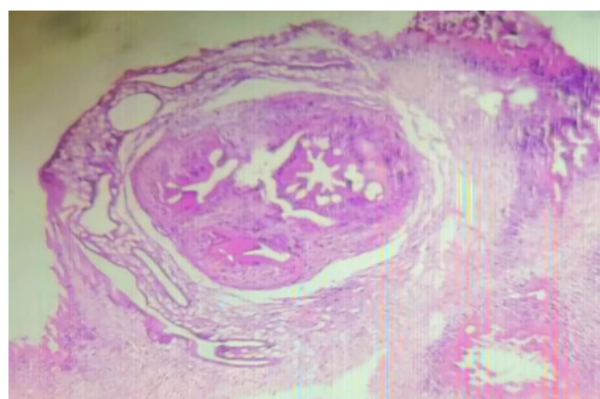
On gross examination, a single creamish white soft to firm globular tissue piece received, measuring 1.0x0.6 cm. The tissue piece has grape like consistency. The specimen was given as such for tissue processing and examined histopathologically.

On microscopic examination, (Figure 1) H and E stained section showed cuticular structure having aggregates of subcuticular cells with identification of suckers along with mixed inflammatory infiltrate. Therefore, the diagnosis of Subretinal Neurocysticercosis was confirmed histopathologically.

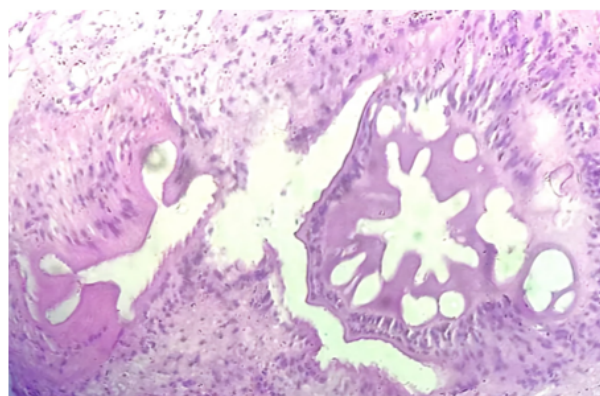
### 3. Discussion

Cysticercosis infection can occur not just on the consumption of uncooked pork meat as has been regarded conventionally, but also from fruits and vegetables that have been washed in water contaminated by the eggs of the larva. The larva enters the subretinal space via the short posterior ciliary arteries, and then breaks through the retina to enter into the vitreous chamber.<sup>8</sup>

Neurocysticercosis has been traditionally associated with the central nervous system, and is more prone to initiate symptoms like seizures. However, isolated ophthalmological manifestations of the condition also need to be taken into consideration. It can also be a prelude to ominous CNS involvement. Hence a high degree of clinical suspicion index and prompt confirmatory diagnosis are essential to prevent substantial eye damage which occurs by the release of inflammatory mediators.. This release of inflammatory mediators occurs when the parasite die and antigens get exposed to host immunity. Cysticerci can persist in infected tissues for extended periods without causing symptoms. The clinical phase begins when the host's immune response is triggered by the larva's death,



A) (10x magnification)



B) (40X magnification)

**Figure 1:** H and E stained section showed cuticular structure having aggregates of subcuticular cells with identification of suckers along with mixed inflammatory infiltrate (10X and 40X magnification respectively)

usually about 18 months after the initial infection. The high occurrence of focal or generalized seizures in this condition is due to the oncospheres localizing primarily in the cerebral cortex, which is prone to generating seizures. They can also invade the ventricular system and basal cisterns, leading to a unique form of infection called "racemose" cysticercosis, which may obstruct cerebrospinal fluid flow, resulting in hydrocephalus and increased intracranial pressure. Ocular involvement by cysticercosis has been on a rise worldwide as well india and accounts for many cases of the same.

Neuroimaging often reveals multiple, rim-enhancing cysts in the brain, suggesting the need for both diagnosis and treatment with antiparasitic drugs. However, some patients have only a single lesion, where the host's response to the dying parasite can cause the cyst to appear as a solid pseudotumor. Neurosurgical procedures might be avoided if cerebrospinal fluid or blood tests detect antibodies or antigens specific to cysticercosis, though these tests can yield false negatives, particularly in cases with only one

cyst. When there is involvement of retina, ophthalmoscopy and other modalities reveal multiple subretinal cysts along with the presence of scolex in atleast one cyst.

When extracted without being significantly altered by inflammation, the gross appearance of cysticerci is almost diagnostic. The cysts are small, surrounded by a firm fibrous capsule, and contain a single scolex, a small gray-white nodule of 3–4 mm. In contrast, other parasitic cysts, such as those from *Multiceps multiceps*, have multiple scolices, and *Echinococcus granulosus* cysts are larger with a distinctive laminated wall. Microscopically, the fibrous capsule surrounding cysticerci is typically infiltrated by lymphocytes and plasma cells, sometimes containing eosinophils and forming granulomas. The degenerated scolex remains covered by a resilient cuticle and contains reticular tissue with calcospherites. Intact scolices have a pseudoepithelial layer, small muscle fibers, and four suckers with birefringent hooklets. Racemose cysticerci, found in ventricles or subarachnoid spaces, appear as clusters of interconnected sacs, lacking organized scolices.

#### 4. Conclusion

Neurocysticercosis has been traditionally associated with the central nervous system, and is more prone to imitate symptoms like seizures. However isolated ophthalmological manifestations of the condition also needs to be taken into consideration. It can also be a prelude to ominous CNS involvement. Hence a high degree of clinical suspicion index and prompt confirmatory diagnosis are essential to prevent substantial eye damage which occurs by the release of inflammatory mediators.

#### 5. Source of Funding

None

#### 6. Conflict of Interest

None

#### References

1. Pittella JE. Neurocysticercosis. *Brain Pathol.* 1997;7(1):681–93.
2. Sekhar GC, Lemke BN. Orbital cysticercosis. *Ophthalmology.* 1997;104(10):1599–604.
3. Malik SR, Gupta AK, Choudhry S. Ocular cysticercosis. *Am J Ophthalmol.* 1968;66(6):1168–71.
4. Reddy PS, Satyendran OM. Ocular cysticercosis. *Am J Ophthalmol.* 1964;57:664–6.
5. Junior L. Ocular cysticercosis. *Am J Ophthalmol.* 1949;32(4):523–48.
6. Pushker N, Bajaj MS, Chandra M, Neena. Ocular and orbital cysticercosis. *Acta Ophthalmol Scand.* 2001;79(4):408–13.
7. Kruger-Leite E, Jalkh AE, Quiroz H, Schepens CL. Intraocular cysticercosis. *Am J Ophthalmol.* 1985;99(3):252–7.
8. Kumar V, Surve A, Kumar P, Sharma A, Azad S. Submacular cysticercosis. *Eur J Ophthalmol.* 2020;30(5):NP58–NP61.
9. Das D, Deka S, Islam S, Deuri N, Deka P, Deka AC, et al. Neuro and intraocular cysticercosis: A clinicopathological case report. *Eye Brain.* 2010;2:39–42.

#### Author's biography

**Arpit Varshney**, Junior Resident

**Ruquiya Afrose**, Assistant Professor

**Gourik Gangopadhyay**, Junior Resident

**Sayedul Hasan Arif**, Professor

**Avadh Vihari Lal Sharma**, Senior Resident

**Cite this article:** Varshney A, Afrose R, Gangopadhyay G, Arif SH, Sharma AVL. Subretinal neurocysticercosis: A lesser explored manifestation of a fairly common condition. *Indian J Pathol Oncol* 2024;11(4):443–445.