

Content available at: <https://www.ipinnovative.com/open-access-journals>IP International Journal of Ocular Oncology and
OculoplastyJournal homepage: <https://ijooo.org/>**Case Report****Bilateral episodic rise of intraocular pressure: A case of pigment dispersion syndrome****Arti Singh^{1*}, Upasana Singh², Srishti Nagarajan¹**¹Dept. of Ophthalmology, Regional Institute of Ophthalmology, Prayagraj, Uttar Pradesh, India²Dept. of Pediatric Retina & Ocular Oncology, Aravind Eye Hospital & Postgraduate Institute of Ophthalmology, Coimbatore, Tamil Nadu, India**ARTICLE INFO***Article history:*

Received 14-01-2024

Accepted 07-03-2024

Available online 03-05-2024

Keywords:

Zentmayer's ring

Scheie stripe

Krukenberg spindle

Pigment

ABSTRACT

A 28-year-old male patient presented to our hospital with chief complaints of on and off episodes of coloured halos and blurring of vision in both eyes for 2 years. His best corrected visual acuity in each eye was 6/9 P. On slit lamp examination diffuse corneal oedema was present. Tablet acetazolamide was prescribed, and patient was followed on next day. Mild corneal edema with 26 mm of Hg IOP was noted. Krukenberg's spindle was seen in both eyes. Upon dilatation, a Zentmayer's ring or Scheie stripe was noted. Fundoscopy revealed cup disc ratio 0.8 and 0.7 in right and left eye respectively. Gonioscopy examination revealed concave configuration or posteriorly bowing of iris, hyperpigmented trabecular meshwork and Sampaolesi line in both eyes. A diagnosis of bilateral pigmentary glaucoma was entertained, and Bimatoprost (0.01%) eye drops once in a day in both eyes was started. There was a significant improvement in corneal edema and the IOP was 16mmHg in both eyes.

This is an Open Access (OA) journal, and articles are distributed under the terms of the [Creative Commons Attribution-NonCommercial-ShareAlike 4.0 License](#), which allows others to remix, tweak, and build upon the work non-commercially, as long as appropriate credit is given and the new creations are licensed under the identical terms.

For reprints contact: reprint@ipinnovative.com**1. Introduction**

Pigment Dispersion Syndrome is an autosomal dominant disorder with onset in mid- 20s¹ characterized by disruption of iris pigment epithelium and deposition of pigment granules on the anterior segment structures. Some clinical signs that are consistently present in white patients such as iris transillumination defects and anterior iris stromal pigment dusting are, however, not as common in blacks. Although most patients experiencing an episode of pigment dispersion are asymptomatic, extreme photophobia, ocular pain, redness, and blurred vision may occur.

2. Case Presentation

A 28-year-old male patient presented to our hospital with chief complaints of on and off episodes of coloured halos and blurring of vision in both eyes for 2 years. His best corrected visual acuity in each eye was 6/9 P. On slit lamp examination diffuse corneal oedema was present hence applanation tonometry done which measured an IOP of 50 mm of Hg in both eyes. Tablet acetazolamide was prescribed, and patient was followed on next day. Mild corneal oedema with 26 mm of Hg IOP was noted. Krukenberg's spindle was seen in both eyes (Figure 1) and mid peripheral iris transillumination defect was absent on slit lamp observation. Examination of anterior chamber revealed increase depth, both in central and peripheral areas with no posterior synechiae, cells and flare. Upon dilatation, a Zentmayer's ring or Scheie stripe (Figure 2a,b) was noted. Fundoscopy revealed cup disc ratio 0.8 and 0.7

* Corresponding author.

E-mail address: artidr2007@yahoo.co.in (A. Singh).

in right and left eye respectively. Gonioscopy examination revealed concave configuration or posteriorly bowing of iris, hyperpigmented trabecular meshwork and Sampaolesi line in both eyes (Figure 3). ASOCT also revealed peripheral concave configuration of iris (Figure 4) with central corneal thickness below the normal range (463 μ m and 471 μ m in right and left eye respectively). A diagnosis of bilateral pigmentary glaucoma was entertained, and Bimatoprost (0.01%) eye drops once in a day in both eyes was started. One-week later, corneal oedema completely disappeared and IOP was 16 mmHg in both eye and he was advised to continue topical medication.




Figure 1: Krukenberg spindle in pigmentary glaucoma (red arrow)

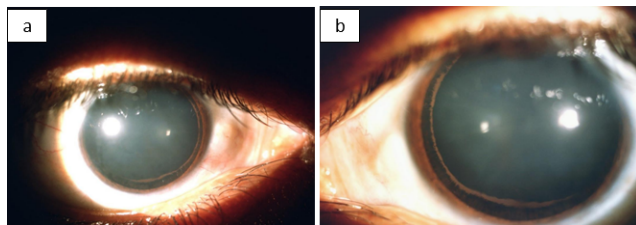


Figure 2: a: Scheie stripe or Zentmayer's ring in right eye; b: Scheie stripe or Zentmayer's ring in left eye.




Figure 3: Hyperpigmented trabecular meshwork with concave iris configuration on gonioscopy

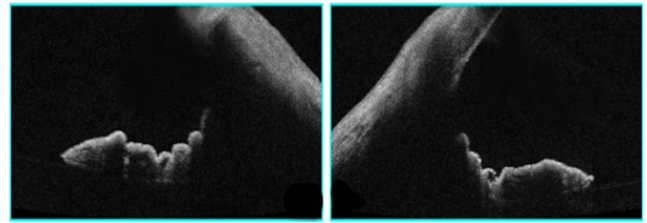


Figure 4: Concave iris configuration on Anterior segment optical coherence tomography.

3. Discussion

Pigment Dispersion Syndrome is an autosomal dominant disorder with onset in mid- 20s¹ characterized by disruption of iris pigment epithelium. The released pigment granules are carried by aqueous convection currents and deposited on anterior segment structures including the corneal endothelium, iris surface, trabecular meshwork (TM), lens surfaces, and zonules.² Although most patients experiencing an episode of pigment dispersion are asymptomatic, extreme photophobia, ocular pain, redness, and blurred vision may occur.³ PDS affects 2–4% of patients during the second to fourth decades of life. The higher prevalence of PDS in young adults makes this group more prone to have POHT. One study has thus reported that after 10 years of progression, the amount of pigment on the posterior surface of the cornea decreased, and in certain patients who had been treated for pigmentary glaucoma, the disease remained stable after discontinuation of treatment. Monitoring the IOP must be rigorous since each 1 mmHg rise above 21 mmHg increases the risk for developing PG by 1.4 times.³ The typical position and the vicinity of the zonular bundles with the mid-peripheral iris and frequent friction with iris movements suggest the cause of loss of pigment from the posterior iris. By means of convective current of the aqueous, pigments get accumulated on the structures of the anterior part of the eye⁴ like corneal endothelium, anterior capsule of lens, trabecular meshwork and pigment deposits on the posterior capsule along the insertion of the zonules are referred to as the Scheie stripe or Zentmayer line.⁵ The diagnostic triad of PDS includes corneal pigmentation (Krukenberg Spindle), mid-peripheral iris transillumination defects and dense trabecular pigmentation.⁶ It can lead to secondary open angle glaucoma called pigmentary glaucoma (PG) with estimated risk between 35% to 50%.⁷ Male gender, black race, severe myopia, and Krükenberg spindles were identified as possible risk factors. It usually affects men at an earlier age and they had a higher proportion in the glaucoma group; and they required more aggressive glaucoma therapy.⁸ The loss of trabecular cells, fusion of trabecular lamellae with collapse of intertrabecular spaces, increase in extracellular material and obliteration of canal in various amounts around the circumference

of eyes can be the cause of rise in intraocular pressure in PDS.⁹ The clinical course of PG is divided into 3 phases¹⁰ i.e. active pigment dispersion, conversion to glaucoma and regression phase. High resolution anterior segment ultrasound biomicroscopy can show mid peripheral iris concavity, irido-zonular contact or irido-ciliary process contact in untreated eyes of PDS.¹¹ Persons with pigment dispersion syndrome also have an abnormally high incidence of lattice degeneration of retina and retinal detachment.¹² Treatment is typically medical which includes prostaglandin analogues, alpha adrenergic agents and beta blockers. Laser trabeculoplasty is more effective in PG.¹³ Laser peripheral iridotomy (PI) has been proposed as a treatment option for PDS but there is no scientific evidence as of yet to associate PI as a treatment for PDS.¹⁴

4. Conclusion

PDS affects 2–4% of patients during the second to fourth decades of life. The higher prevalence of PDS in young adults makes this group more prone to have POHT. Monitoring of IOP therefore becomes an integral part in every follow up.

As the medical treatment proves to be beneficial enough, laser trabeculoplasty can also be sought as an alternative treatment option in Pigmentary Glaucoma.

5. Source of Funding

None.

6. Conflict of Interest

None.

References

- Campbell DG, Schertzer RM. Pathophysiology of pigment dispersion syndrome and pigmentary glaucoma. *Curr Opin Ophthalmol*. 1995;6(2):96–101.
- Roberts DK, Chaglasian MA, Meetz RE. *Optom Vis Sci*. 1997;74(12):993–1006.
- Siddiqui Y, Hulzen RDT, Cameron JD, Hodge DO, Johnson DH. *Am J Ophthalmol*. 2003;135(6):794–9.
- Evans WE, Odom RE, Weenas EJ. Krukengerg's spindle: a study of 202 collected cases. *Arch Ophthalmol*. 1941;26(6):1023–56.
- Niyadurupula N, Broadway DC. Pigment dispersion syndrome and pigmentary glaucoma—a major review. *Clin Exp Ophthalmol*. 2008;38(9):868–82.
- Scuderi G, Contestabile MT, Scuderi L, Librando A, Fenicia V, Rahimi S, et al. Pigment dispersion syndrome and pigmentary glaucoma: a review and update. *Int Ophthalmol*. 2018;39(7):1651–62.
- Niyadurupula N, Broadway DC. Pigment dispersion syndrome and pigmentary glaucoma—a major review. *Clin Exp Ophthalmol*. 2008;38(9):868–82.
- Farrar SM, Shields MB, Miller KN, Stoup CM. Risk factors for the development and severity of glaucoma in the pigment dispersion syndrome. *Am J Ophthalmol*. 1989;108(3):223–9.
- Ritch R. A unification hypothesis of pigment dispersion syndrome. *Trans Am Ophthalmol Soc*. 1996;94:381–405.
- Gandolfi SA, Ungaro N, Mora P, Sangermani C. Pigmentary glaucoma. In: Shaarawy T, Sherwood M, Hitchings R, Crowston J, editors. *Glaucoma: medical Diagnosis and Therapy*. United States: Saunders Ed; 2009. p. 349–60.
- Potash SD, Tello C, Liebmann J, Ritch R. Ultrasound biomicroscopy in pigment dispersion syndrome. *Ophthalmology*. 1994;101(2):332–9.
- Gottanka J, Johnson DH, Grehn F, Lütjen-Drecoll E. Histologic findings in pigment dispersion syndrome and pigmentary glaucoma. *J Glaucoma*. 2006;15(2):142–51.
- Kuchle MK, Nguyen NX, Mardin CY, Naumann GO. Effect of neodymium : YAG laser iridotomy on number of aqueous melanin granules in primary pigment dispersion syndrome. *Graefes Arch Clin Exp Ophthalmol*. 2001;239(6):411–5.
- Buffault J, Leray B, Bouillot A, Baudouin C, Labbé A. Role of laser peripheral iridotomy in pigmentary glaucoma and pigment dispersion syndrome: A review of the literature. *J Fr Ophthalmol*. 2017;40(10):889–97.

Author biography

Arti Singh, Associate Professor  <https://orcid.org/0000-0002-3790-7162>

Upasana Singh, Senior Resident  <https://orcid.org/0000-0002-9848-4546>

Srishti Nagarajan, Senior Resident  <https://orcid.org/0000-0002-8791-0204>

Cite this article: Singh A, Singh U, Nagarajan S. Bilateral episodic rise of intraocular pressure: A case of pigment dispersion syndrome. *IP Int J Ocul Oncol Oculoplasty* 2024;10(1):44–46.