

Content available at: <https://www.ipinnovative.com/open-access-journals>

IP Archives of Cytology and Histopathology Research

Journal homepage: <https://www.achr.co.in/>

Case Report

Fungal bezoar of bladder in type 2 diabetic mellitus patient: A case report

Ranjana Hawaldar¹, Shana Nikhat Khan^{1*}

¹Dept. of Pathology, Sampurna Sodani Diagnostic Clinic, Indore, Madhya Pradesh, India



ARTICLE INFO

Article history:

Received 10-07-2024

Accepted 05-10-2024

Available online 08-10-2024

Keywords:

catheterization

dyslipidemia

histopathological

hyphae

ABSTRACT

A 54 year male, post operated case of bypass surgery presented to a Urologist with acute retention of urine. Patient was relieved by catheterization and bladder irrigation. WBC's and RBC's were increased in Urine. Cystoscopy revealed fungal balls in the bladder which on histopathological examination showed aseptate hyphae and spores. Patient was managed by systemic voriconazole and diluted povidone iodine bladder wash. Predisposing factors were diabetes mellitus and dyslipidemia. This case stresses the importance of considering isolated fungal urinary infections in predisposed individuals.

This is an Open Access (OA) journal, and articles are distributed under the terms of the [Creative Commons Attribution-NonCommercial-ShareAlike 4.0 License](#), which allows others to remix, tweak, and build upon the work non-commercially, as long as appropriate credit is given and the new creations are licensed under the identical terms.

For reprints contact: reprint@ipinnovative.com

1. Introduction

Fungal bezoar in urinary bladder is a rare pathological entity, of which less than 20 previous cases have been described in the literature since the first case was reported in 1961.¹ Fungal bezoars are frequent in immunocompromised individual, hospitalized patients with multiple comorbidities and those with severe illness requiring admission to intensive care units.² Here, we present a case of Urinary bladder fungal balls without disseminated.

2. Case Presentation

In our case, we will discuss a case of urinary fungal bezoar infection that was severe enough to cause acute retention of urine, render the patient anuric. Our patient is a 54 year male, he had undergone bypass surgery two and half months before. Since his surgery, the patient was hospitalized for a long period i.e. for 10 -12 days and received broad spectrum antibiotics. The patient was kept on urinary catheter as it was difficult for him to mobilize. A week after his

discharge from hospital, the patient felt bladder fullness and bilateral flank pain with anuria. Patient was relieved by catheterization and bladder irrigation.

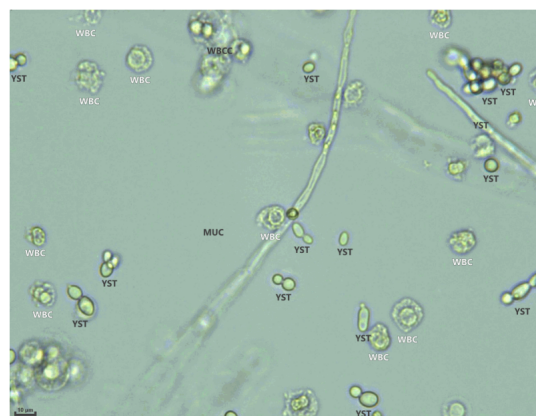


Figure 1: Urine routine microscopy on automated analyzer showing yeast forms and fungal hyphae with pus (WBC) cells.

His urine routine microscopy on Transasia Laura XL Fully automated Urine analyzer reveals increased pus cells 194/hpf and RBC's 27/hpf. Fungal hyphae and yeast forms

* Corresponding author.

E-mail address: drshana.sampurna@gmail.com (S. N. Khan).

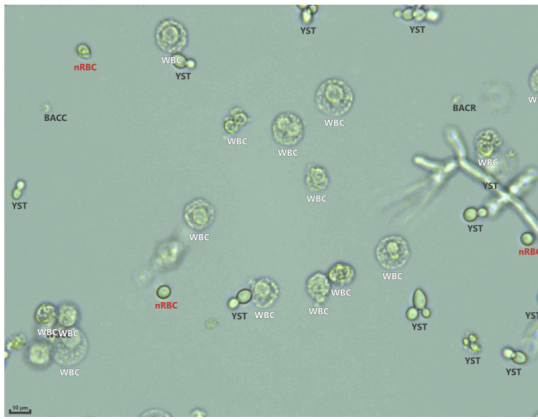


Figure 2: Urine routine microscopy on autoanalyzer showing fungal hyphae and yeast forms with RBC's and WBC's.

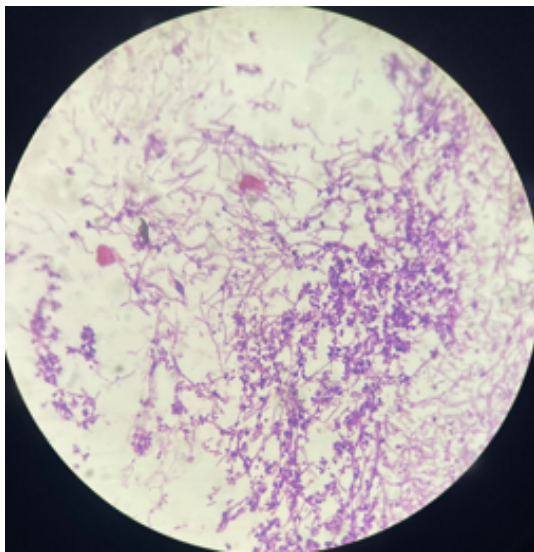


Figure 3: Histopathological examination reveals fungal colonies were aseptate hyphae and spores

were seen on microscopy (Figures 1 and 2).

We also received urine with flakes for histopathological examination. Grossly multiple dirty white color flakes altogether measuring 2.0 x 1.5 x 0.5 cm received. Microscopic examination shows necrosed tissue with dense mixed inflammatory cell exudate with many fungal colonies. These fungal colonies were aseptate hyphae and spores (Figure 3)

3. Discussion

Fungal Urinary tract infections are more likely to develop in patients with predisposing factors such as Urinary catheterization, ICU stay, use of broad-spectrum antibiotics, diabetes and glucocorticoids therapy.^{3–5} Fungal bezoars can be found anywhere in the urinary tract, and so its clinical presentation depends upon site of the bezoars. Urinary tract obstruction at renal pelvis or ureteric bezoars might

elevate renal function test and hydronephrosis. In such cases surgical intervention such as nephrostomy or ureteric stenting is usually necessary.^{6,7} Previous case reports have shown fungal bezoars spreading to both pelvicalyceal systems causing bilateral renal obstruction at the level of renal pelvis and ureters leading to acute renal failure and anuria.^{8,9}

Unlike simple bacterial or fungal UTIs, the treatment of fungal bezoars may require local intervention in addition to systemic therapy with antifungals. Fungal balls could be also directly extracted using flexible ureteroscopy, cystoscopy, PCNL or by surgical exploration in more complicated cases.^{10,11} Urinary microscopy and histopathological examination lead to definitive diagnosis. So as proper treatment of this condition would be essence to prevent further complications and to avoid the need for more invasive measures.

4. Conclusion

Fungal infections of urinary tract even though rare should always be kept as differential diagnosis in patient of persistent UTI, especially in susceptible populations such as hospitalized patients, or one with comorbidities. Urine routine microscopy and histopathological examination play a key role in early diagnosis on fungal bezoars and prevention of further future complication.

5. Conflicts of Interest

The authors declare that they have no conflicts of Interest.

6. Source of Funding


None.

References

1. Chisholm ER, Hutch JA. Fungus ball (Candida albicans) formation in the bladder. *J Urol*. 1961;86(5):559–62.
2. Kobayashi CC, Fernandes OF, Miranda KC, De Sousa E, Silva MRR. Candiduria in hospital patients: a study prospective. *Mycopathologia*. 2004;158(1):48–52.
3. Gharanfoli A, Mahmoudi E, Torabizadeh R, Katirae F, Faraji S. Isolation, characterization, and molecular identification of Candida species from urinary tract infections. *Curr Med Mycol*. 2019;5(2):33–6.
4. Odds FC. Factors that predispose the host to candidosis. Candida and Candidosis. *Bailliere Tindall*. 1988;p. 93–104.
5. Achkar JM, Fries BC. Candida infections of the genitourinary tract. *Clin Microbiol Rev*. 2010;23(2):253–73.
6. Van Merode N, Pat JJ, Wolfhagen M, Dijkstra GA. Successfully treated bilateral renal fungal balls with continuous anidulafulgin irrigation. *Urol Case Rep*. 2021;34:101468. doi:10.1016/j.eucr.2020.101468.
7. Das MK, Pakshi RR, Kalra S, Elumalai A, Theckumparampil N. Fungal Balls Mimicking Renal Calculi: A Zebra Among Horses. *J Endourol Case Rep*. 2019;5(4):167–70.
8. Scerpella EG, Alhalel R. An unusual cause of acute renal failure: bilateral ureteral obstruction due to Candida tropicalis fungus balls. *Clin Infect Dis*. 1994;18(3):440–2.

9. Ku JH, Kim ME, Jeon YS, Lee NK, Park YH. Urinary ascites and anuria caused by bilateral fungal balls in a premature infant. *Arch Dis Child Fetal Neonatal Ed.* 2004;89(1):92–3.
10. Kittaweerat N, Attawettayanon W, Choorit T. Bilateral renal fungal bezoars in a preterm infant: case report and literature review. *J Surg Case Rep.* 2021;(10):436. doi:10.1093/jscr/rjab436.
11. Comiter CV, McDonald M, Minton J, Yalla SV. Fungal bezoar and bladder rupture secondary to candida tropicalis. *Urology.* 1996;47(3):439–41.

Author biography

Ranjana Hawaldar, Consultant Pathologist  <https://orcid.org/0000-0003-4059-0781>

Shana Nikhat Khan, Consultant Pathologist

Cite this article: Hawaldar R, Khan SN. Fungal bezoar of bladder in type 2 diabetic mellitus patient: A case report. *IP Arch Cytol Histopathology Res* 2024;9(3):169-171.