

Content available at: <https://www.ipinnovative.com/open-access-journals>

IP Archives of Cytology and Histopathology Research

Journal homepage: <https://www.achr.co.in/>

## Case Report

# Silent intruder: Identifying a testicular mass in the shadow of prostate carcinoma

Kempula Geethamala<sup>1\*</sup>, Meena N Jadhav<sup>2</sup>, Balina Nirmala<sup>1</sup>, Rekha M Haravi<sup>1</sup>

<sup>1</sup>Dept. of Pathology, Belagavi Institute of Medical Sciences, Belagavi, Karnataka, India

<sup>2</sup>Dept. of Pathology, D Y Patil Medical College, Kolhapur, Maharashtra, India



## ARTICLE INFO

### Article history:

Received 07-08-2024

Accepted 03-09-2024

Available online 08-10-2024

### Keywords:

Adenomatoid tumor

Prostate carcinoma

Immunohistochemistry

Calretinin

## ABSTRACT

Adenomatoid tumors of the testis are rare, benign neoplasms that arise from mesothelial cells. These tumors are usually asymptomatic and are often discovered incidentally during procedures or evaluations for other conditions. We present a case of 86 year male, in whom adenomatoid tumor was incidentally identified in the testis removed during an orchiectomy performed as part of the management for prostatic carcinoma.

This is an Open Access (OA) journal, and articles are distributed under the terms of the [Creative Commons Attribution-NonCommercial-ShareAlike 4.0 License](#), which allows others to remix, tweak, and build upon the work non-commercially, as long as appropriate credit is given and the new creations are licensed under the identical terms.

For reprints contact: [reprint@ipinnovative.com](mailto:reprint@ipinnovative.com)

## 1. Introduction

Adenomatoid tumors of the testis are rare, benign neoplasms that arise from mesothelial cells and are typically located in the testicular and paratesticular region.<sup>1</sup> These tumors are usually asymptomatic and are often discovered incidentally during procedures or evaluations for other conditions.<sup>1,2</sup> In this case, we present an adenomatoid tumor incidentally identified in the testis removed during an orchiectomy performed as part of the management for prostatic cancer.

## 2. Case History

An 86 year old male patient, known case of prostatic carcinoma, diagnosed on transurethral resection of the prostate (TURP), two months back was posted for bilateral orchiectomy as a part of its further hormonal management. Operated specimens received in the department of pathology; grossly both the testes were normal on external surface. On cut-surface, Right testis showed a grey-white, firm, well-circumscribed nodule measuring 1x1 cms on the lower pole of the testis, rest of the right testis and

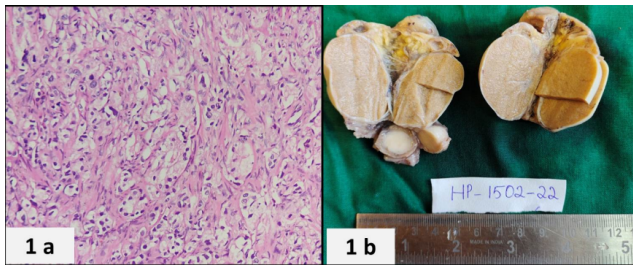
left testis with spermatic cords were unremarkable. On histopathological examination, well encapsulated tumor was seen in right testis composed of gland-like, tubulocystic and slit-like spaces lined by flattened to cuboidal epithelial cells. The cells lining the spaces had bland nuclear features and scant cytoplasm. Atypical mitotic figures and necrosis were absent. The stroma was fibrous and myxoid at places with occasional presence of smooth muscle fibers. Adenomatoid tumor of testis origin was made on histopathology. Immunohistochemical (IHC) markers were used to confirm the mesothelial origin of the adenomatoid tumor and to distinguish it from other tumors. Calretinin showed cytoplasmic and nuclear strong positivity and Cytokeratins (CK5/6 and CK7) cytoplasmic positivity emphasizing the origin as mesothelial cells. Hence the final diagnosis of Adenomatoid tumor in right testis was made.

## 3. Discussion

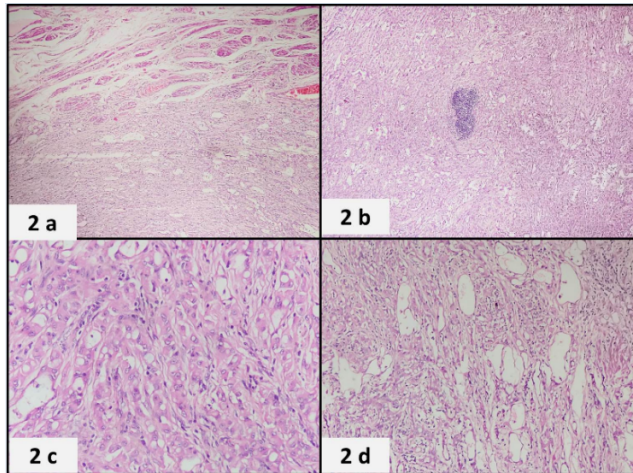
Adenomatoid tumors are uncommon benign neoplasms of mesothelial origin, typically found in both male and female genital tract, including the testis, epididymis, and fallopian tubes.<sup>1,2</sup> The adenomatoid tumor of the testis was first described by Golden and Ash in 1945.<sup>1</sup> They identified and

\* Corresponding author.

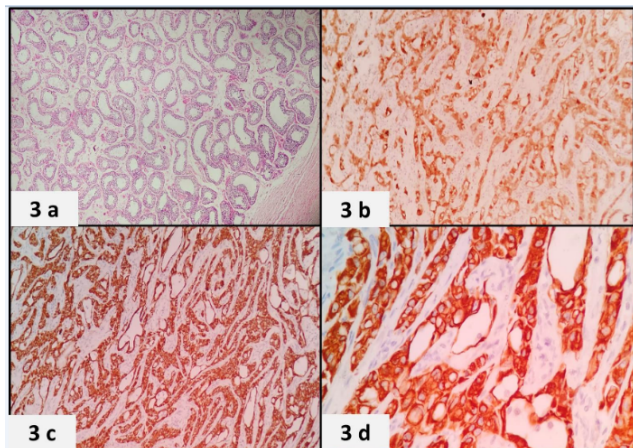
E-mail address: [drgeethamala@gmail.com](mailto:drgeethamala@gmail.com) (K. Geethamala).



**Figure 1:** a: Microscopy of TURP showing prostatic adenocarcinoma (H&E 40X); b: Gross image of bilateral orchidectomy, right testis showing circumscribed lesion



**Figure 2:** a,b,c,d: Microscopy of well encapsulated tumor was seen in right testis composed of gland-like, tubulocystic, and slit-like spaces lined by flattened to cuboidal epithelial cells having bland nuclear features and scant cytoplasm. Atypical mitotic figures were absent. The stroma was fibrous and myxoid at places with occasional presence of smooth muscle fibers. (H&E 40X)



**Figure 3:** a: Microscopy showing unremarkable seminiferous tubules of testis. (H&E 40X); b,c : IHC for Calretinin showing strong cytoplasmic and nuclear positivity emphasizing the origin as mesothelial cells. (IHC 10X); d: IHC for Cytokeratins (CK5/6 and CK7) cytoplasmic strong positivity (IHC 10X & 40X)

characterized this benign mesothelial neoplasm, marking the initial recognition of this tumor type in medical literature. They are also known by the pseudonym of “benign mesothelioma” of the intrascrotal tumors but they usually present as extra testicular masses, they are the most common paratesticular neoplasm and account for approximately 30% of all paratesticular masses.<sup>3,4</sup> Although the histogenesis of this rare neoplasm has been a source of controversy and it is now generally agreed that they are of mesothelial origin. They are generally small, asymptomatic, and often discovered incidentally during surgeries for other conditions, as in the present case where an adenomatoid tumor was identified during an orchiectomy performed for prostatic carcinoma.<sup>3–5</sup>

Adenomatoid tumors show a spectrum of histological patterns as adenoid or tubular glandular, angiomatoid, solid, cystic or transitional patterns. Tumor cells appear as eosinophilic mesothelial cells in pattern of solid cords as well as dilated tubules. The pathognomic feature of the cells is a vacuolated or scant cytoplasm without cytological atypia. Atypical mitotic figures and necrosis is typically absent. In most of the lesions, the stroma is fibrous but may occasionally contain a smooth muscle component. The lack of mitotic activity further supports the benign nature of this tumors.<sup>6–8</sup> IHC is essential for confirming the mesothelial origin of adenomatoid tumors. Key markers include Calretinin, WT-1, D2-40 (Podoplanin) and Cytokeratins (CK5/6 and CK7) markers positive staining supports the diagnosis. HBME-1 and EMA are also often positive, though not specific for the diagnosis.<sup>4</sup>

Differentiating adenomatoid tumors from other testicular and paratesticular neoplasms is crucial for appropriate management. The differential diagnosis includes Sertoli cell tumors, Leydig cell tumors, Metastatic carcinomas and Malignant mesothelioma. The IHC profile helps distinguish adenomatoid tumors from these entities, ensuring correct diagnosis and avoiding unnecessary treatments.<sup>4–8</sup>

The incidental finding of an adenomatoid tumor during orchiectomy for prostatic carcinoma did not impact the management of the primary malignancy. However, it highlights the importance of awareness among pathologists and clinicians regarding the possibility of such incidental findings. Regular follow-up is not typically required for adenomatoid tumors due to their benign nature, but documentation and awareness are important for clinical records and patient education.<sup>8</sup>

#### 4. Conclusion

This case emphasizes the significance of thorough histopathological examination of all surgical specimens. The incidental discovery of an adenomatoid tumor in an orchiectomy specimen from a patient with prostatic carcinoma is a reminder of the diverse pathologies that may be encountered during routine surgical procedures.

Recognizing and accurately diagnosing such tumors are essential to ensure appropriate patient management and to prevent unnecessary interventions.

## 5. Source of Funding

None.

## 6. Conflict of Interest

None.

## References

1. Stephenson TJ, Mills PM. Adenomatoid tumours: an immunohistochemical and ultrastructural appraisal of their histogenesis. *J Pathol*. 1986;148(4):327–35.
2. Elsässer E. Tumors of the epididymis. *Recent Results Cancer Re*. 1977;(60):163–75.
3. Schwartz EJ, Longacre TA. Adenomatoid tumors of the female and male genital tracts express WT1. *Int J Gynecol Pathol*. 2004;23(2):123–8.
4. Delahunt B, Eble JN, King D, Bethwaite PB, Nacey JN, Thornton A, et al. Immunohistochemical evidence for mesothelial origin of paratesticular adenomatoid tumour. *Histopathology*. 2000;36(2):109–15.
5. Park SB, Lee WC, Kim JK, Choi SH, Kang BS, Moon KH, et al. Imaging features of benign solid testicular and paratesticular lesions. *Eur Radiol*. 2011;21(10):2226–34.
6. Amin W, Parwani AV. Adenomatoid tumor of testis. *Clin Med Pathol*. 2009;9(2):17–22.
7. Chen D, Yu Z, Ni L, Gui Y, Yang S, Shi B, et al. Adenomatoid tumors of the testis: a report of two cases and review of the literature. *Oncol Lett*. 2014;7(5):1718–20.
8. Williams SB, Han M, Jones R, Andrawis R. Adenomatoid tumor of the testes. *Urology*. 2004;63(4):779–81.

## Author biography

**Kempula Geethamala**, Assistant Professor

**Meena N Jadhav**, Professor

**Balina Nirmala**, Senior Resident

**Rekha M Haravi**, Professor and HOD

**Cite this article:** Geethamala K, Jadhav MN, Nirmala B, Haravi RM. Silent intruder: Identifying a testicular mass in the shadow of prostate carcinoma. *IP Arch Cytol Histopathology Res* 2024;9(3):155–157.