

Content available at: <https://www.ipinnovative.com/open-access-journals>

IP Archives of Cytology and Histopathology Research

Journal homepage: <https://www.achr.co.in/>

## Case Report

# Primary cervical malignant melanoma: A rare entity case report

Anupam Sarma<sup>1</sup>, Debarata Barmon<sup>1</sup>, Shiraj Ahmed<sup>1</sup>, Swati Sharma<sup>1\*</sup>, Jagannath Dev Sharma<sup>1</sup>

<sup>1</sup>Dept. of Oncopathology, Dr B Borooah Cancer Institute, Guwahati, Assam, India



## ARTICLE INFO

### Article history:

Received 16-07-2024

Accepted 17-09-2024

Available online 08-10-2024

### Keywords:

Melanoma

Cervix

Immunohistochemistry

## ABSTRACT

Primary malignant melanoma of female genital tract is rare, and rarer are those arising from the cervix. Pathogenesis involving BRAF & RAS pathway whether holds true for these tumours as well is a question yet to be answered. Patients come with bleeding PV as their main complain. To reach at the diagnosis of primary malignant melanoma of cervix it is important to have clinical examination with speculum assessment along with pathological evaluation of the lesion. Case presentation: We report a case of 49/F, Para 1, living 1 (PIL1), who was postmenopausal since 13 years with complains of white discharge and bleeding per vaginum since 1 week. Per vaginal examination revealed a greysih white brown growth in the cervix involving vagina. Biopsy and immunohistochemistry showed malignant melanoma (MM). Conclusion: Clinical presentation and spread pattern of primary MM of cervix is similar to that of cervical carcinoma and clinically diagnosing as melanoma is even more difficult when more than 50% tumours are amelanotic. But early diagnosis is need of the hour as these cases have poor prognosis with no standardize treatment protocol available. The FIGO staging system has been accepted by most researchers. Reporting of such cases is pertinent so as to allow the study of this extremely rare tumour for bringing up the correct and new therapies for early treatment.

This is an Open Access (OA) journal, and articles are distributed under the terms of the [Creative Commons Attribution-NonCommercial-ShareAlike 4.0 License](#), which allows others to remix, tweak, and build upon the work non-commercially, as long as appropriate credit is given and the new creations are licensed under the identical terms.

For reprints contact: [reprint@ipinnovative.com](mailto:reprint@ipinnovative.com)

## 1. Introduction

Malignant melanoma covers 1% cases of all cancers and is commonly a neoplasm of skin and mucous membrane. Rarely it can occur in uncommon sites like female genital tract mainly, vulva, vagina and cervix. Out of these cervix is the rarest location to have malignant melanoma, it is five times less common than malignant melanoma of vulva and vagina.<sup>1</sup> Amelanotic melanoma especially poses a challenge for clinical diagnosis as presents in similar manner as cervix carcinoma/sarcoma/lymphoma.<sup>2</sup>

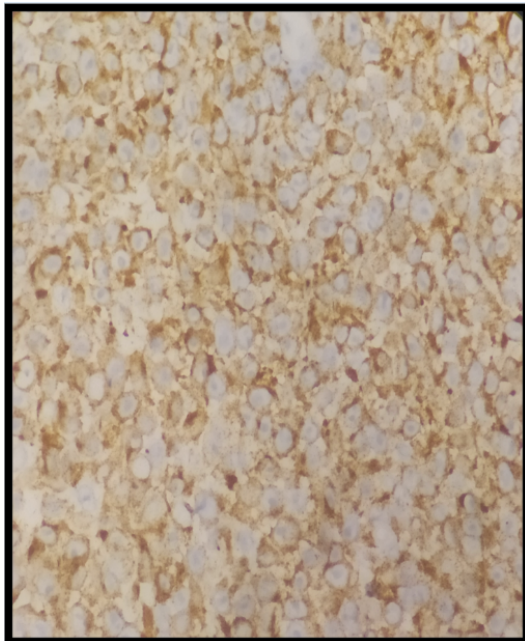
## 2. Case Report

A 49 year old postmenopausal female presented with white discharge and bleeding per vaginum since 1 week. She was PIL1. She had no relevant medical history. She had undergone appendectomy 10 years back. She had history of tobacco chewing. On examination per abdomen was soft. Per vaginum examination showed entire vaginal canal to be obliterated with an ulceroproliferative growth that bleeds on touch. Bilateral parametrium was involved. On basis of clinical examination a diagnosis of carcinoma cervix, stage IIIB was made. The next plan was to do metastatic work up. Her complete blood picture was normal. She was triple H (hepatitis B, hepatitis C and HIV) negative. Her random blood sugar, liver function tests and thyroid function tests were all normal. Biopsy was then taken and sent for

\* Corresponding author.

E-mail address: [drswatisharma.204@gmail.com](mailto:drswatisharma.204@gmail.com) (S. Sharma).

histopathological examination. Meanwhile patient was sent for imaging studies (CECT), which revealed bulky cervix with iso to dense mass. That mass showed heterogenous enhancement after intravenous contrast infusion. Rest of uterus show postmenopausal atrophy. Mass reaches upper third of vagina caudally and no pelvic sidewall extension was seen. Anterior Rectal wall compressed but intervening fascial planes were maintained. Posterior wall of urinary bladder compressed with loss of cleavage planes, but no ureteric compression was seen. Pelvic lymphadenopathy was present. There was no ascites and rest of the abdomen and pelvis was normal. A diagnosis of Carcinoma cervix stage IV with extension into lower vagina, parametrial and anterior rectal wall with prominent bilateral pelvic nodes was made. No other abnormality detected on clinical examination and imaging studies. Meanwhile Biopsy report came and it was reported poorly differentiated malignancy with an advice to get immunohistochemistry (IHC) done, keeping differential diagnosis of carcinoma and melanoma. Histopathology showed tumour cells arranged in loose sheets and discohesive pattern. Individual cells are round to polygonal with moderate to abundant eosinophilic cytoplasm. The nucleus is eccentrically placed showing mild nuclear pleomorphism. Nucleus is vesicular with cherry red conspicuous centrally placed nucleolus. Mitosis is seen. IHC showed- CK to be focally positive, vimentin, and HMB45 diffusely positive; and CD31, CD45 to be negative. Keeping in view of histopathological features and IHC a final diagnosis of primary cervical malignant melanoma with rhabdoid features was made was made.(Figure 1)



**Figure 1:**

### 3. Discussion

MM is originally considered as neoplasm of skin and mucous membrane. The melanomas arising from female genital tract comprises 3-7% of all melanomas and behave aggressively. In the female genital tract vulva is the most common site for getting malignant melanoma in the females of 5<sup>th</sup> to 7<sup>th</sup> decade. In vulva, labia minora, clitoris and inner side of labia majora are the sites which get maximum bulk of the disease.<sup>3</sup> Primary malignant melanoma of cervix waited long enough to become an individual neoplasm. This was so because cervix does not show any melanocytes. So it is of utmost importance to rule out MM anywhere in the body before giving a diagnosis of primary cervical MM.<sup>4</sup>

To aid the diagnosis along with clinical examination histopathological and immunohistochemical examinations play a pivotal role. As suggested by Morris and Taylor there are four criteria to label MM as primary cervical MM, which are- presence of melanin in the normal cervical epithelium, presence of junctional changes in the cervix, metastasis like cervical carcinoma and absence of MM elsewhere in the body.<sup>5</sup>

The common complains patient present with are vaginal discharge, vaginal bleeding and vaginal mass.<sup>6,7</sup> Clinical examination shows a pinkish mass (commonly along with ulceration) in contrast to cutaneous MM which develops from nevus.<sup>8</sup>

On cervical pap smears atypical cells which may be of round or spindle shaped can be seen. Since half of the MM of cervix are amelanotic it is very difficult to differentiate them on H&E from squamous cell carcinoma, adenocarcinoma, rhabdomyosarcoma, leiomyosarcoma and mixed mullerian tumour. Hence it is recommended to use the sensitive marker S100 and specific marker HMB45 to rule out MM.<sup>9</sup>

Due to the rarity of the lesion there are no standardized treatment protocol, but the consensus favors radical hysterectomy with pelvic lymphadenopathy in cases with early stage disease and pelvic exenteration in cases with advanced stage diseases.

### 4. Conclusion

Clinical presentation and spread pattern of primary MM of cervix is similar to that of cervical carcinoma and clinically diagnosing as melanoma is even more difficult when more than 50% tumours are amelanotic. But early diagnosis is need of the hour as these cases have poor prognosis with no standardize treatment protocol available. The FIGO staging system has been accepted by most researchers. Reporting of such cases is pertinent so as to allow the study of this extremely rare tumour for bringing up the correct and new therapies for early treatment.

## 5. Declaration of Patient Consent

The authors certify that they have obtained all appropriate patient consent forms. In the form the patients had given consent for her images and other clinical information to be reported in the journal. The patient understand that her name and initials will not be published and due efforts will be made to conceal their identity, but anonymity cannot be authorized.

## 6. Source of Funding

None.

## 7. Conflicts of Interest

There is no conflict of interest

## References

1. Mousavi AS, Fakor F, Nazari Z, Ghaemmaghami F, Hashemi FA, Jamali M, et al. Primary malignant melanoma of the uterine cervix: Case report and review of the literature. *J Low Genit Tract Dis*. 2006;10(4):258–63.
2. Genton CY, Kunz J, Schreiner WE. Primary malignant melanoma of the vagina and cervix uteri. *Virchows Arch Path Anat Histol*. 1981;393:245–50. doi:10.1007/BF00431080.
3. Dunton CJ, Berd D. Vulvar melanoma, biologically different from other cutaneous melanomas. *Lancet*. 1999;354(9195):2013–4.
4. Negi L, Mardi K, Negi L. Primary amelanotic melanoma of the cervix: A case report with review of literature. *Clin Cancer Investig J*. 2020;9:264–6. doi:10.4103/ccij.ccij\_95\_20.
5. Norris HJ, Taylor HB. Melanomas of the vagina. *Am J Clin Pathol*. 1966;46(4):420–6.
6. Xia L, Han D, Yang W, Li J, Chuang L, Wu X, et al. Primary malignant melanoma of the vagina: a retrospective clinicopathologic study of 44 cases. *Int J Gynecol Cancer*. 2014;24(1):149–55.
7. Cantuaria G, Angioli R, Fernandez-Abril A, Penalver M. Primary malignant melanoma of the uterine cervix: case report and review of the literature. *Prim Care Update Ob Gyns*. 1998;5(4):159–60.
8. Seifried S, Haydu LE, Quinn MJ, Scolyer RA, Stretch JR, Thompson JF, et al. Melanoma of the vulva and vagina: principles of staging and their relevance to management based on a clinicopathologic analysis of 85 cases. *Ann Surg Oncol*. 2015;22(6):1959–66.
9. Deshpande AH, Munshi MM. Primary malignant melanoma of the uterine cervix: report of a case diagnosed by cervical scrape cytology and review of the literature. *Diagn Cytopathol*. 2001;25(2):108–11.

## Author biography

**Anupam Sarma**, Professor and HOD

**Debarata Barmon**, Professor

**Shiraj Ahmed**, Professor

**Swati Sharma**, Oncopathology Trainee

**Jagannath Dev Sharma**, Ex-Professor

**Cite this article:** Sarma A, Barmon D, Ahmed S, Sharma S, Sharma JD. Primary cervical malignant melanoma: A rare entity case report. *IP Arch Cytol Histopathology Res* 2024;9(3):149-151.