


Content available at: <https://www.ipinnovative.com/open-access-journals>

Indian Journal of Clinical and Experimental Ophthalmology

Journal homepage: www.ijceo.org

Case Report

A simple suture technique to repair iatrogenic iridodialysis post cataract surgery: A case report

Kiruthika Sekizhan¹, Premnath Gnaneswaran^{1*}, Shankar Chokkalingam¹, Rajakumari Murugesan¹

¹Dept. of Ophthalmology, Chettinad Academy of Research and Education, Kelambakkam, Tamil Nadu, India



ARTICLE INFO

Article history:

Received 16-11-2023

Accepted 14-02-2024

Available online 30-09-2024

Keywords:

Iridodialysis repair

Suture technique

Iatrogenic

ABSTRACT

Disinsertion of iris from its attachment is called iridodialysis. Symptomatic and large iridodialysis often requires repair. Repair of iridodialysis is complex and often require special instruments and good surgical expertise. We describe a simple suture technique to repair an iatrogenic iridodialysis caused during small incision cataract surgery in a 62 year-old patient. This technique is simple and involves very minimal tissue handling. The primary aim of us doing this procedure is the functional and cosmetic result which can be obtained in the same sitting as the primary procedure with common available instruments.

This is an Open Access (OA) journal, and articles are distributed under the terms of the [Creative Commons Attribution-NonCommercial-ShareAlike 4.0 License](https://creativecommons.org/licenses/by-nc-sa/4.0/), which allows others to remix, tweak, and build upon the work non-commercially, as long as appropriate credit is given and the new creations are licensed under the identical terms.

For reprints contact: reprint@ipinnovative.com

1. Introduction

Iridodialysis is a localized disinsertion of the iris from its attachment to the ciliary body where it is weakest and thinnest.^{1,2} It generally occurs due to ocular trauma³ and intraocular procedures such as cataract surgery.⁴ The incidence of iridodialysis due to small incision cataract surgery stands at 0.2%.⁵ Intervention might not be required when the dialysis is small, but large and symptomatic iridodialysis frequently needs surgical repair. Superior iridodialysis involving 10 O' clock to 2 O' clock position is often less symptomatic as it is covered by the upper eye lid whereas temporal, inferior and large iridodialysis are usually symptomatic. Numerous techniques for iridodialysis repair have been described, most of them being technically challenging.^{4,6,7} We describe a simplified approach of iridodialysis repair using 10-0 non absorbable monofilament polyamide suture (Ethilon) and basic instruments used for a conventional cataract surgery with a favourable outcome.

* Corresponding author.

E-mail address: drprem1822@gmail.com (P. Gnaneswaran).

2. Case Report

A 62 years old male was undergoing cataract surgery in his right eye by a trainee surgeon under the supervision of a senior surgeon. After nucleus delivery a large iridodialysis was noted inferiorly from 4 O'clock to 8 O'clock position (Figure 1 A, B and Figure 2 A). As the dialysis was large and inferiorly situated, it was decided to repair the iris in the same sitting and planned after the implantation of intra ocular lens.

2.1. Surgical technique

Following a top up peribulbar anaesthesia, inferior peritomy was done and hemostasis attained with light cautery. A 10-0 non absorbable monofilament polyamide suture (Ethilon) with a curved needle was passed from sclera at 7 O'clock position corresponding to the iris insertion, the inferior edge of the detached iris is taken into the needle with the help of an iris repositor in the anterior chamber and the suture is exteriorized through cornea. The same as above was done at 6 O' clock and 5 O' clock positions

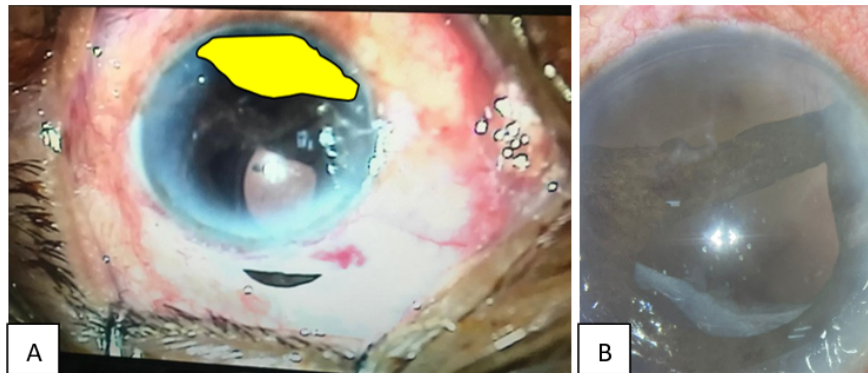
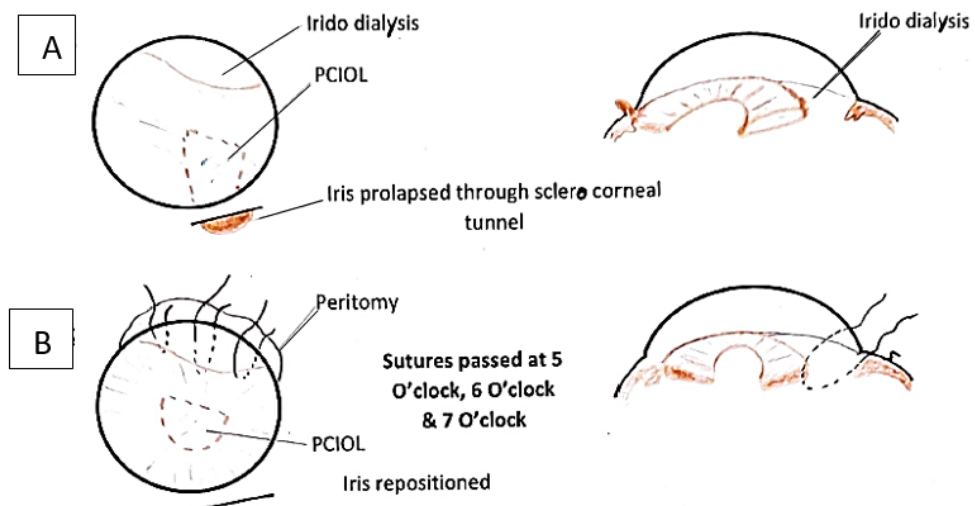


Figure 1: A): Pre-operative photograph showing an inferior iridodialysis from 4 O'clock to 8 O'clock position (shaded area) and prolapsed iris superiorly through the main wound. Note the D shaped pupil due to iridodialysis; B): Preoperative photograph after iris reposition

Pre-Op



Post-Op

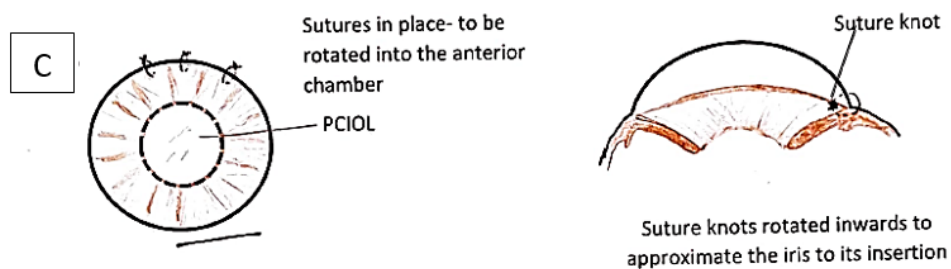


Figure 2: Step wise illustration of iridodialysis repair: A): Depiction of Iridodialysis and iris prolapse; B): Three sutures passed from sclera side (5 O' clock, 6 O' clock and 7 O' clock positions) through the corresponding edges of iris and exteriorized through cornea; C): Sutures individually tied in 3-2-2 fashion and rotated inwards to approximate the iris to its insertion

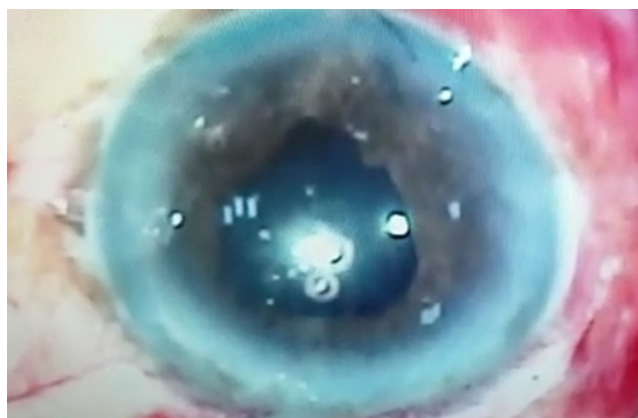

Figure 3: Postoperative picture showing correction of iridodialysis and formation of fairly round pupil centrally

as shown in Figure 2 B. The three sutures were tied with knots in 3-2-2 fashion. All the knots were rotated into the anterior chamber and pulled towards the angle of anterior chamber so that the knots approximated the edges of the dialysed iris to its insertion as shown in Figure 1 C. The procedure was completed with formation of anterior chamber with balanced salt solution and air followed by closure of peritomy and placement of a bandage contact lens (BCL) over the cornea. Sub conjunctival gentamycin and dexamethasone were delivered to minimise the risk of intra ocular infections and inflammation. The postoperative period was uneventful and the recovery was good. The visual acuity at 2 weeks postoperative period was 6/9 with fairly round pupil and no diplopia and glare.

3. Discussion

Iridodialysis causes polycoria which can be annoyingly symptomatic due to monocular diplopia and glare. Sometimes it can be cosmetically unacceptable. Iridodialysis can be classified into massive (More than 120 Degrees), moderate (45 to 120 Degrees), and minimal (less than 45 Degrees) depending on the extent of dialysis.⁸ Characteristically, the functional and cosmetic complaints are often encountered if iridodialysis occurs in the inferior, temporal or nasal aspects. Our patient had a large inferior iridodialysis which would have been symptomatic and caused cosmetic issues. Ever since BW Key described the first iridodialysis repair in 1932, various surgeons have been attempting the procedure with varied results.^{4,6–14} Mc Cannel's technique initiated a revolution in iris repair among ophthalmic surgeons.⁷ Sewing machine technique was originally described for iridodialysis subsequently got modified.^{7,12,13} Siepser slip knot,⁷ mattress suture¹⁴ and single pass four throw technique⁸ have been in vogue. Availability of number of techniques has provided the surgeons with options to choose from. Most of these procedures required straight suturing needles which may

not be available in the operation theatre all the time and maneuvers are more complex. Often the anterior chamber could not be maintained stable during large iridodialysis repair. More importantly the iridodialysis repair procedure would have to be planned electively if it occurs during any other intra ocular procedures such as cataract surgery. Our technique was performed on the same sitting with the instruments generally used for conventional cataract surgery. Hence it can be done in camp setup with limited availability of instruments.

The advantages of this simple technique are:

1. It can be performed with available instruments used for conventional cataract surgery.
2. Anterior chamber stability is maintained.
3. Minimal tissue handling.

Our novel and simple technique requires simple maneuvers and results in good functional and cosmetic outcome.

4. Limitation

The exteriorized suture on the cornea may cause irritation and pose a risk for infection. To address this, we had placed a BCL and the patient was closely monitored. Application of topical antibiotic drops were extended along with regular postoperative medications. Our patient's post operative period was uneventful.

5. Conclusion

We have described this simple suture technique which would come in handy in urgent situations and need less expertise and minimal common surgical instruments.

6. Source of Funding

None.

7. Conflict of Interest


None.

References

1. Okamoto Y, Yamada S, Akimoto M. Suturing repair of subtotal iridodialysis. *Int Ophthalmol*. 2018;38(1):395–8.
2. Kumar KVR. Modified sewing machine technique for iridodialysis repair, intraocular lens relocation, iris coloboma repair, Cionni ring fixation, and scleral-fixed intraocular lens. *Indian J Ophthalmol*. 2018;66(8):1169–76.
3. Shekhar M, Menon PR. "Stay Back Technique" of scleral fixation of decentred intraocular lensbag complex. *Indian J Ophthalmol*. 2022;70(7):2777.
4. Yousif MO. Single suture customized loop for large iridodialysis repair. *Clin Ophthalmol*. 2016;10:1883–90.
5. Sangameswaran RP, Verma GK, Raghavan N, Joseph J, Sivaprakasam M. Cataract surgery in mobile eye surgical unit: Safe and viable alternative. *Indian J Ophthalmol*. 2016;64(11):835–9.

6. Benayoun Y, Petitpas S, Turki K, Adenis JP, Robert PY. Implants à fixation sclérale sans suture: série de neuf cas et revue de la littérature [Sutureless scleral intraocular lens fixation: report of nine cases and literature review]. *J Fr Ophthalmol*. 2013;36(8):658–68.
7. Lian RR, Siepser SB, Afshari NA. Iris reconstruction suturing techniques. *Curr Opin Ophthalmol*. 2020;31(1):43–9.
8. Narang P, Agarwal A, Agarwal A, Agarwal A. Twofold technique of nonappositional repair with single-pass four-throw pupilloplasty for iridodialysis. *J Cataract Refract Surg*. 2018;44(12):1413–20.
9. Pandav SS, Gupta PC, Singh RR, Das K, Kaushik S, Raj S, et al. Cobbler's Technique for Iridodialysis Repair. *Middle East Afr J Ophthalmol*. 2016;23(1):142–4.
10. Agarwal T, Singh D, Panda A. Guide needle-assisted iridodialysis repair. *J Cataract Refract Surg*. 2011;37(10):1918.
11. Stopa M, Rakowicz P. Sutureless iris repair: cauterization technique. *Retina*. 2015;35(12):2647–9.
12. Kumar KVR. Sewing machine technique for iridodialysis repair. *Delhi J Ophthalmol*. 2015;24(4):248–51.
13. Kumar KVR. Modified sewing machine technique for iridodialysis repair, intraocular lens relocation, iris coloboma repair, Cionni ring fixation, and scleral-fixated intraocular lens. *Indian J Ophthalmol*. 2018;66(8):1169–76.
14. Steinert RF. Minimally invasive iris surgery. In: Minimally invasive ophthalmic surgery. Berlin, Heidelberg: Springer; 2010. p. 153–9.

Author biography

Kiruthika Sekizhan, Senior Resident  <https://orcid.org/0009-0005-9374-7641>

Premnath Gnaneswaran, Professor  <https://orcid.org/0000-0002-8867-2914>

Shankar Chokkalingam, Professor  <https://orcid.org/0000-0002-9956-6703>

Rajakumari Murugesan, Professor  <https://orcid.org/0000-0002-7145-6502>

Cite this article: Sekizhan K, Gnaneswaran P, Chokkalingam S, Murugesan R. A simple suture technique to repair iatrogenic iridodialysis post cataract surgery: A case report. *Indian J Clin Exp Ophthalmol* 2024;10(3):616-619.