

Content available at: <https://www.ipinnovative.com/open-access-journals>

IP International Journal of Orthopaedic Rheumatology

Journal homepage: www.ijor.org

Original Research Article

A comparative study of functional outcome of percutaneous kirschner wire fixation versus philos plating of proximal humerus fractures

Mayur Agrawal¹, Akshay Bhosale^{1*}, Tushar Pimpale¹¹Dept. of Orthopaedics, Vilasrao Deshmukh Government Medical College & Hospital, Latur, Maharashtra, India

ARTICLE INFO

Article history:

Received 03-06-2024

Accepted 23-06-2024

Available online 02-07-2024

Keywords:

Proximal Humerus Fractures

PHILOS

K-wire

Constant-Murley score

ABSTRACT

Introduction: Proximal humerus fractures, accounting for approximately 5% of all fractures, pose a significant challenge in orthopedic management due to their complex anatomy and diverse fracture patterns. Treatment options range from conservative methods to various surgical interventions, each with its pros and cons. This study specifically compares two commonly employed surgical techniques: Open reduction & internal fixation with PHILOS plate and percutaneous k-wire fixation with/without external clamps. This study aims to address the effectiveness of each technique by evaluating functional outcomes using validated scoring systems like the Constant-Murley Score.

Objectives: To assess the functional outcomes of two surgical treatment methods (K-wire application and PHILOS plate fixation) for proximal humerus fractures.

Materials and Methods: A randomized prospective study was conducted on patients coming to the Orthopaedics outpatient department or casualty of tertiary care hospital for a duration of 1 year from Dec 2022 to Nov 2023. A total of 18 patients were included in the study.

Results: The mean Constant-Murley Score (CMS) was 81 +/- 6.13 for the PHILOS plating group and 76.88 +/- 7.37 for the K-wire treated group with a p-value of 0.08. The results for CMS were excellent in 22.2% of patients and good in 66.7% of patients in PHILOS treated group and excellent for 11.11%, good for 66.67% and satisfactory for 22.2% in the K-wire treated group.

Conclusion: Both groups achieved satisfactory functional outcomes with CM Score at the final follow-up. Both techniques achieved favorable outcomes, with a majority of patients in both groups (88.89% for PHILOS and 77.78% for K-wire) achieving good to excellent results based on the CMS scores.

This is an Open Access (OA) journal, and articles are distributed under the terms of the [Creative Commons Attribution 4.0 International License](https://creativecommons.org/licenses/by/4.0/), which allows others to remix, and build upon the work. The licensor cannot revoke these freedoms as long as you follow the license terms.

For reprints contact: reprint@ipinnovative.com

1. Introduction

Proximal humerus fractures, accounting for approximately 5% of all fractures, pose a significant challenge in orthopedic management due to their complex anatomy and diverse fracture patterns.¹ Treatment of Proximal humerus fracture does not have major complications but it leads to loss of working hours for months and temporary disability. In such cases it becomes important to restore the function of the limb. Treatment of this injury is purely depended on the severity of fracture & classification. Whether to choose

non-operative treatment or go with surgical procedure can be debatable as there are many studies favouring the both modalities.

Treatment options range from conservative management like collar and cuff sling to various surgical interventions, each with its pros and cons. Surgical options include closed percutaneous fixation with k-wires to open reduction & internal fixation with various available implants ranging from k-wires, intramedullary nails to plate. We conducted this study at our institute and its main purpose was to compare functional outcome of two modalities as treatment of proximal humerus fracture that includes Philos plating

* Corresponding author.

E-mail address: akshaybhoslemd@gmail.com (A. Bhosale).

and percutaneous k-wire fixation with or without external clamps.

PHILOS plating, which stands for proximal humerus internal locking osteosynthesis plate is an invasive technique, that utilizes a locking plate system to achieve anatomical reduction and stable fixation of the fracture fragments.² This method most commonly utilizes the Deltopectoral approach for fracture exposure & fixation. This approach offers potential benefits like improved biomechanical stability, early mobilization, and potentially better functional outcomes.³ However, concerns exist regarding soft tissue damage, neurovascular damage, risk of infection, implant prominence, soft tissue irritation, and potential hardware complications.⁴

Percutaneous k-wire fixation with or without external clamps, on the other hand, involves inserting thin Kirschner wires (k-wires) across the fracture site. Securing these k wires externally with clamps provides better stability to the construct and prevents varus collapse. This minimally invasive method offers advantages like less surgical dissection, shorter operative time, less morbid and potentially lower cost.⁵ However, concerns include the potential for k-wire migration, loss of fixation, and limitations in achieving optimal fracture reduction, particularly in complex fracture patterns.⁶

Therefore, a comparative study investigating Philos plating versus percutaneous k- wire fixation with external clamps for proximal humerus fractures is crucial to evaluate their efficacy and safety, ultimately guiding optimal treatment decisions. This study aims to address this need by Evaluating functional outcomes using validated scoring systems like the Constant-Murley score. By analyzing these key parameters, this study will contribute valuable insights into the comparative effectiveness of Philos plating and percutaneous k-wire fixation with external clamps, potentially informing treatment strategies for proximal humerus fractures.

2. Materials and Methods

This is a randomized prospective study. This study was conducted at a Tertiary care hospital. This study includes patients coming to the Orthopaedics outpatient department or casualty department of the tertiary care hospital.

2.1. Inclusion criteria

1. Age: 18 years and older.
2. Radiologically confirmed Neer's classification - 2-part and 3-part fractures.
3. Willing and able to provide written informed consent for participation in the study.

2.2. Exclusion criteria

1. Open fractures.

2. Old or Pathological fractures.
3. Severe comorbidities/unfit for surgical treatment.
4. Patients who were not willing to give written consent.

All patients with Proximal humerus fracture fulfilling the selection criteria were taken from December 2022 to November 2023. A total of 18 patients were included in the study. Upon enrollment in the study random sampling was done. The study was conducted over a duration of 1 year.

This study aims to "Evaluate the comparative effectiveness of philos plating and percutaneous k-wire fixation with external clamps for proximal humerus fractures and the objective of the study was to assess the functional outcomes of two surgical treatment methods (K-wire application and PHILOS plate fixation) for proximal humerus fractures.

2.3. Methodology

2.3.1. Patient selection and enrollment

Upon arrival at the emergency department, patients with suspected shoulder injuries underwent a thorough clinical evaluation. Those with suspected proximal humerus fractures were identified for further investigation with shoulder X-rays – Anteroposterior view & Axillary Lateral view. After radiological confirmation CT scan of the involved shoulder can be performed if needed. An appropriate shoulder immobilizer was applied & further planning for intervention started.

2.3.2. Randomization

To ensure unbiased group allocation, a consecutive enrolment process was implemented. The first eligible patient was assigned to Group A, the second to Group B, and so on, alternating between groups until the target sample size of patients was reached.

2.3.3. Preoperative evaluation

Following selection, all patients underwent a comprehensive preoperative workup including blood tests, chest X-ray, and electrocardiogram (ECG) to assess their fitness for surgery.

2.3.4. Surgical intervention

Group A received open reduction internal fixation (ORIF) using a PHILOS plate. Group B underwent closed reduction internal fixation (CRIF) with percutaneous k-wire fixation with external clamping.

2.3.5. Surgical techniques

Open reduction & internal fixation group involves patient in a supine position. Followed by selective regional anesthesia or general anesthesia, exposure using a deltopectoral approach fracture is reduced first followed by definitive fixation with the plate internally. Whereas in second group patients, the same supine position & regional anesthesia

is given. Percutaneously fracture reduced then multiple k-wires were inserted to aid fixation. Following that external clamps were applied to the ends of k-wires to avoid varus collapse of fracture.

2.3.6. Outcome measures

Patients were followed up routinely on 6 weeks, 3 months, 6 months, and 1 year. On each follow-up, patients were evaluated clinically using the Constant-Murley Score to assess their functional recovery. Additionally, serial X-rays were obtained to monitor fracture union throughout the healing process.

2.4. Data analysis

The data will be entered into Microsoft Excel Worksheet. The categorical data will be expressed as rates, ratios, and proportions and the continuous data will be expressed as mean \pm standard deviation. Graphical representations will be done wherever applicable. The comparison of the two groups will be done using an unpaired t-test. $P \leq 0.05$ at a 95% confidence interval will be considered as statistically significant.

2.5. Ethical consideration

The study will be conducted after obtaining permission from the Institutional Ethics Committee and the Department of orthopaedics.

2.6. Confidentiality

All the data collected in this study will be kept strictly confidential and used for the study only.

2.7. Consent

All the patients will be enrolled after obtaining their written informed consent once they are stable.

3. Results

The following observations were made from the data collected during this study of the functional outcome following fixation using Philos plating and percutaneous k-wire fixation with external clamps for proximal humerus fractures. A total number of 18 patients were taken up for study. Out of which, 9 patients were treated with the ORIF with PHILOS plating and 9 patients with percutaneous K-wire fixation with or without external clamps. At the final follow-up, the mean Constant- Murley score (CMS) was 81 ± 6.13 for the PHILOS plating group and 76.88 ± 7.37 for the K-wire treated group which was not found statistically significant. The results for CMS were excellent in 22.3% of patients and good in 66.7% of patients, for PHILOS treated group and excellent for 11.1%, good for 66.67% and satisfactory for 22.2% in K-wire treated group.

The following observations were made from the collected data-

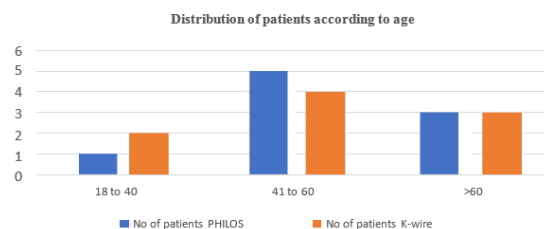


Chart 1: Age distribution

In PHILOS treated group, 1 patient was in 18-40 years of age group, 5 patients were in 41-60 age group and 3 patients were more than 60 years.

Similarly, in K-wire treated group 2 patients were in 18-40 years of age, 4 patients were in 41 – 60 age and 3 patients were more than 60 years.(Chart 1)

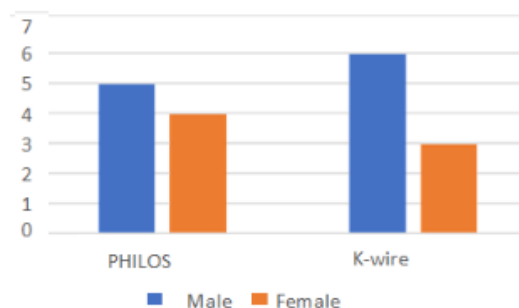


Chart 2: Distribution gender

Gender wise distribution showed that in PHILOS group there were 5 males and 4 females and in the K-wire group, there were 6 males and 3 females.(Chart 2)

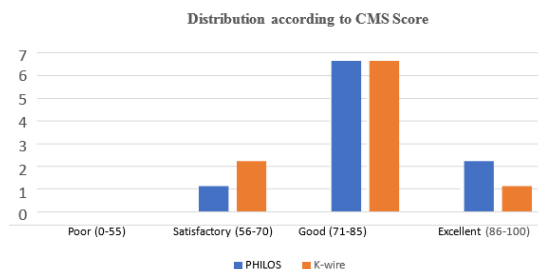


Chart 3: CMS (functional outcome score) distribution

The results for CMS were excellent in 22.2% of patients, good in 66.7% and satisfactory in 11.1% patients, for PHILOS treated group and excellent for 11.1%, good for 66.7% and satisfactory for 22.2% in K-wire treated group. (Chart 3)

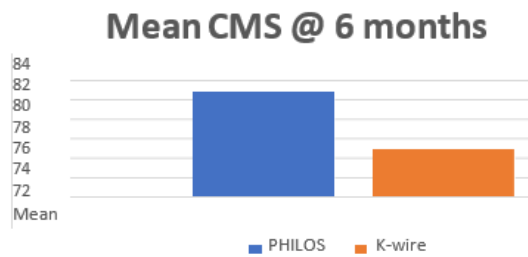


Chart 4: Mean CMS score

At 6 month follow-up, the mean Constant-Murley score (CMS) was 82.77 ± 6.13 for the PHILOS plating group and 76.88 ± 7.37 for the K-wire treated group which was not found significant statistically. (Chart 4)

Case No-1 : ORIF with Plating (Figures 1, 2, 3, 4 and 5)

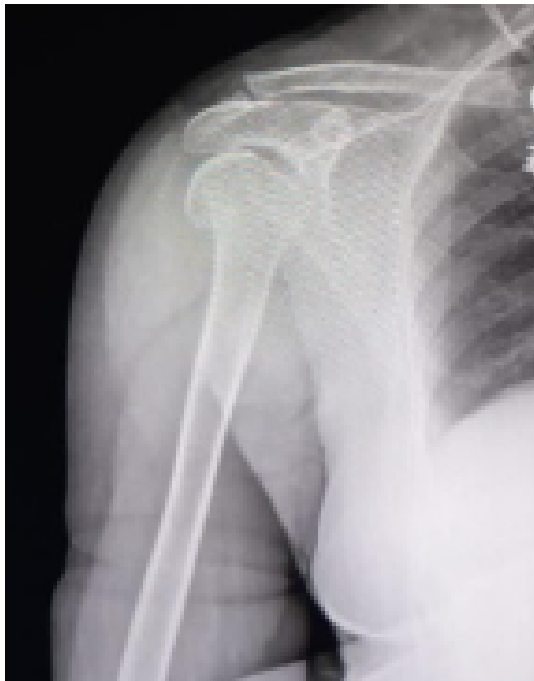

Figure 1: Pre – OP for plate

Case No. 2 : CRIF with percutaneous K-wires & external clamps (Figures 6, 7, 8 and 9)

4. Discussion

Various studies had reported varying results. Gangaiah M et al⁷ (2020) concluded that PHILOS plate provides an excellent stable construct even in multi fragmented osteoporotic proximal humerus fractures with the advantages of accurate reduction and early mobilization. Fixation with percutaneous K - wires may present an efficient treatment option for near 2 or 3 part proximal humerus fractures with its advantages of minimal

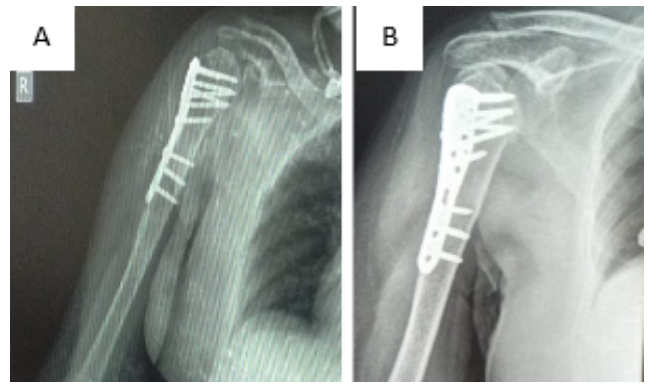


Figure 2: A,B: Post– OP for plate

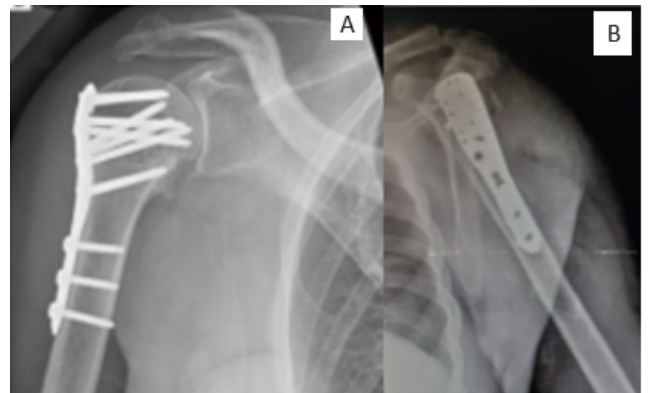


Figure 3: A,B: 1.5 months post op for plate

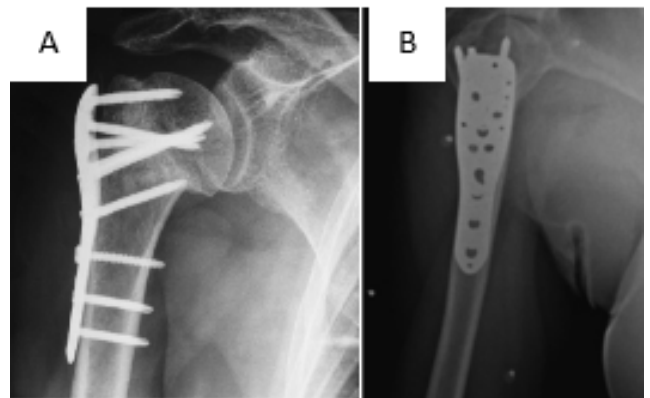


Figure 4: A,B: 6 months post op for plate

invasiveness and less soft tissue dissection. Better functional results were seen in patients treated with PHILOS plate than those treated with percutaneous K - wire fixation. He got Excellent (20 %), Very good (45 %), Good (25 %), Fair (10%) outcomes in PHILOS Plate (Group A). Whereas Excellent (10%), Very good (50 %), Good (35%), Fair (5%) outcomes in K wiring (Group B).⁷

Singla TK et al (2022)⁸ in their study of the Functional outcome of percutaneous Kirschner wire fixation of

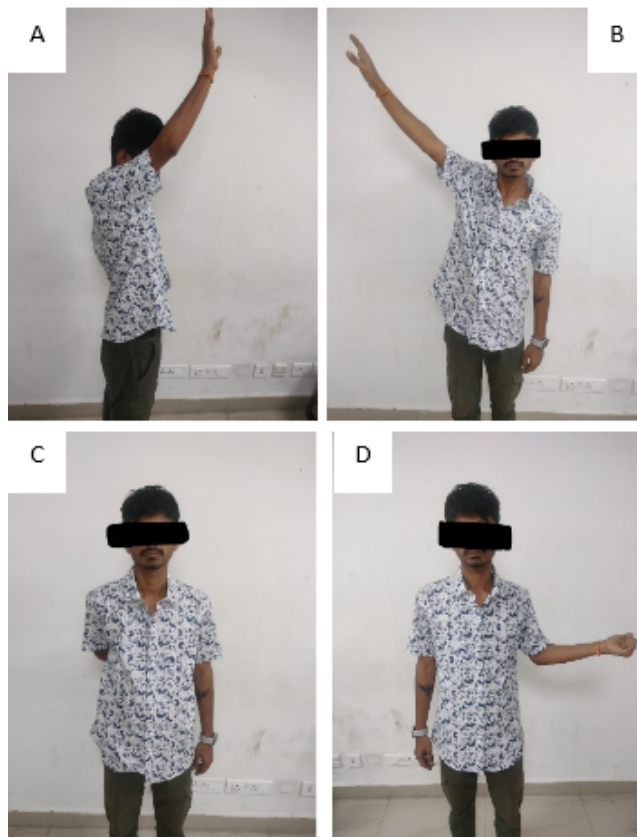


Figure 5: A,B,C,D: Follow Up – for plating AT 6 months

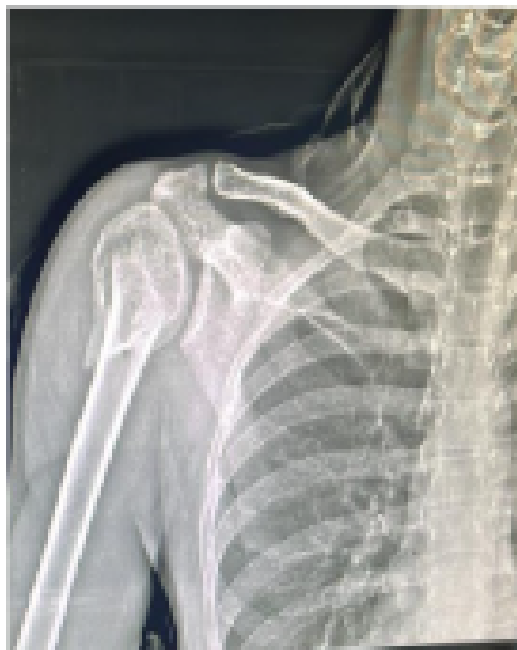

Figure 6: Pre– OP for K-wire

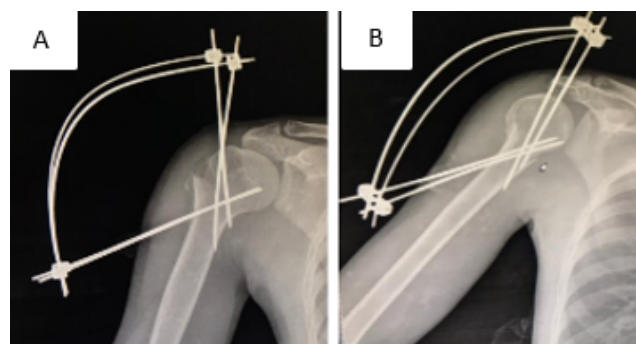


Figure 7: A,B: Post– OP FOR K-wire

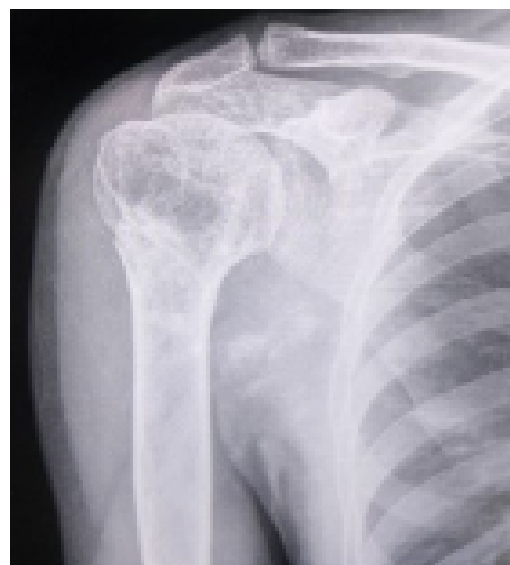

Figure 8: Follow up– OP for K-Wire AT 1.5 months–After removal of K-wires

proximal humerus fractures, found that after 6 months of follow-up, CM score was in the range of 46-91. About 65% of the patients (n=11) had a Good functional outcome, only 2 had Excellent results and the rest of them had Fair results. The more severe the fracture as per Neer's and AO/OTA classification, the lower the total scores observed at final follow-up. None of the patients had Poor functional outcome as per CM score.⁸

Rizwan Shahid⁹ et al. found similar results, although functional outcomes were better in younger patients and worse with associated dislocations.⁹ Thyagarajan et al. reported an average Constant score of 57.5 in their study of 30 patients with Neer's 2-part, 3-part, and 4-part fractures (average age 58 years).¹⁰ Kettler et al. observed Constant-Murley scores ranging from 52 to 72 points after PHILOS plate surgery.¹¹⁻¹⁷

Our study achieved a mean Constant Murley score of 82.77 \pm 6.13 at the end of 6 months for PHILOS Group. This score compares favorably with other studies



Figure 9: A,B,C,D: Follow UP – OP for K-Wire at 6 months

on PHILOS plate fixation for proximal humerus fractures. Whereas score was 76.88 ± 7.37 for the K-wire treated group.

5. Conclusions

This study compared the functional outcomes of two methods for fixing proximal humerus fractures: Philos plating and percutaneous k-wire fixation with external clamps. Although the difference was not statistically significant, both groups achieved satisfactory functional outcomes with CM Score at the final follow-up at 6 months. Both techniques achieved favourable outcomes, with a majority of patients in both groups (88.9% for PHILOS and 77.8% for K-wire) achieving good or excellent results based on the CMS score. No study promises superiority over others for proximal humerus fracture. Further study with a larger sample size might be necessary to determine if one method offers a clear advantage over the other.

6. Limitations

1. Radiological results were not compared and this study was based on Constant Murley Scoring (functional outcomes).
2. The sample size was small for generalizing the findings of this study.
3. Duration of follow-up is inadequate.

7. Source of Funding

None.


8. Conflict of Interest

None.

References

1. Raza AS, Khan MS, Khan IA. A comparative study of functional outcome following PHILOS plating versus percutaneous pinning in proximal humerus fractures. *J Orthop Surg (India)*. 2021;16(2):16–26.
2. Jain A, Sharma A, Mittal R. Study of functional outcome and postoperative complications among proximal humerus fracture patients treated with proximal humerus internal locking system (PHILOS) plating. *J Clin Orthop Trauma*. 2023;14(1):148–53.
3. Jagiasi A, Sharma AK, Mittal R. A comparative study to assess the functional outcome and complication rate of PHILOS plate and percutaneous K-wire fixation in proximal humerus fractures. *Orthopaper*. 2022;8(3):236–42.
4. El-Tawil M, El-Azab M, Mohamed A. PHILOS plate fixation for proximal humerus fractures: a retrospective study. *Injury*. 2016;47(11):2410–4.
5. Cho KJ, Kim SH, Kim JK. Comparison of percutaneous wire fixation with an external fixator and locking plate fixation for unstable proximal humeral fractures in elderly patients. *J Orthop Trauma*. 2010;24(10):728–34.
6. Ricci WM, Owens BD, Tornetta P. Fixation of proximal humerus fractures in the elderly. *J Orthop Trauma*. 2006;20(10):710–22.
7. Gangaiah M, Basavaraj MK, Hanumantappa BG. A comparative study of open reduction and internal fixation with PHILOS plate versus closed reduction and fixation with percutaneous k wiring of neers 2-part and 3-part proximal humerus fractures. *J Evid Based Med Health*. 2020;7(40):2247–50.
8. Singla TK, Selhi HS, Jain D. Functional outcome of percutaneous Kirschner wire fixation of proximal humerus fractures. *Indian J Orthop Surg*. 2022;8(4):263–8.
9. Rizwan S, Mushtaq A, Northover J, Mohammad M. Outcome of proximal humerus fractures treated by PHILOS plate internal fixation Experience of a District General Hospital. *Acta Orthop Belg*. 2008;74(5):602–8.
10. Thyagarajan DS, Haridas SJ, Jones D, Dent C, Evans R, Williams R, et al. Functional outcome following proximal humeral interlocking system plating for displaced proximal humeral fractures. *Int J Shoulder Surg*. 2009;3(3):57–62.
11. Kettler M, Biberthaler P, Braunstein V, Zeiler C, Kroetz M, Mutschler W, et al. Treatment of proximal humeral fractures with the PHILOS angular stable plate. Presentation of 225 cases of dislocated fractures. *Unfallchirurg German*. 2006;109(12):1032–40.
12. Bjorkenheim JM, Pajarinen J, Savolainen V. Internal fixation of proximal humeral fractures with a locking compression plate. *Acta Orthop Scand*. 2004;75(6):741–5.
13. Aggarwal S, Bali K, Dhillon MS, Kumar V, Mootha AK. Displaced proximal humeral fractures: an Indian experience with locking plate. *J Orthop Surg Res*. 2010;5:60. doi:10.1186/1749-799X-5-60.
14. Siwach R, Singh R, Rohilla RK, Kadian VS, Sangwan SS, Dhanda M. Internal fixation of proximal humerus fracture by locking proximal humerus plate in elderly osteoporotic. *J Orthop Traumatol*. 2008;9(3):149–53.
15. Jhamnani R, Dhanda MS, Surana A, Cureus. Study of Functional Outcome and Postoperative Complications Among Proximal Humerus Fracture Patients Treated With Proximal Humerus Internal Locking System (PHILOS) Plating. *Cureus*. 2023;15(7):10447996. doi:10.7759/cureus.42411.
16. Muncibì F, Paez DC, Matassi F, Carulli C, Nistri L, Innocenti M, et al. Long term results of percutaneous fixation of proximal humerus fractures. *Indian J Orthop*. 2012;46(6):664–7.

17. Jaberg H, Warner JJ, Jakob RP. Percutaneous stabilization of unstable fractures of the humerus. *J Bone Joint Surg Am.* 1992;74(4):508–15.

Tushar Pimpale, Assistant professor,  <https://orcid.org/0009-0009-4421-7934>

Author biography

Mayur Agrawal, Junior Resident

Akshay Bhosale, Senior Resident  <https://orcid.org/0000-0001-5945-8065>

Cite this article: Agrawal M, Bhosale A, Pimpale T. A comparative study of functional outcome of percutaneous kirschner wire fixation versus philos plating of proximal humerus fractures. *IP Int J Orthop Rheumatol* 2024;10(1):18-24.