

Content available at: <https://www.ipinnovative.com/open-access-journals>

Indian Journal of Clinical Anatomy and Physiology

Journal homepage: <https://www.ijcap.org/>

Original Research Article

Radiological study of carrying angle among male and female and its clinical importance

T Prabhakar^{1*}, Vinodkumar Gurram², Eshwari R³¹Dept. of Anatomy, Zydus Medical College and Hospital, Dahod, Gujarat, India²Dept. of Anatomy, SSPM Medical College & Life Time Hospital, Padve, Maharashtra, India³Osmania University, Hyderabad, Telangana, India

ARTICLE INFO

Article history:

Received 27-02-2024

Accepted 29-03-2024

Available online 06-05-2024

Keywords:

Carrying angle

Radiograph

Elbow joint

ABSTRACT

Background: The long axes of the ulna and humerus form an acute angle when the upper limb is in its anatomical position and the elbow is fully extended is known as the carrying angle. It is typically larger in females than in males. Anthropologists use the carrying angle to predict a person's sex; orthopaedic surgeons use it to surgically treat a variety of elbow disorders; and total elbow prosthetics.

Aim: The study aimed to assess the carrying angle in an attempt to determine its value in both sexes, proposing a simple and reliable method for measuring it.

Materials and Methods: The elbow radiographs taken in the normal anteroposterior and lateral views were assessed independently and uniformly by anatomists. A total of 70 adult radiographs between the ages of 18 to 76 years, 35 males and 35 females were gathered. To measure the angle, two lines were drawn: one along the mid-axis of the upper limb of the forearm, passing between the radius and ulna through the superior radioulnar joint, and the other along the mid-axis of the lower third of the humerus, where the angle is measured.

Result: The carrying angle is statistically more significant in females than in males among 70 radiographs. The p-value was 0.000 and the mean and SD for males were 14.3 ± 2.740 , while the mean and SD for females were 21.92 ± 3.170 .

Conclusion: The current study concludes that there is a significant gender difference between females and males; carrying angle influences secondary sexual characteristics.

This is an Open Access (OA) journal, and articles are distributed under the terms of the [Creative Commons Attribution-NonCommercial-ShareAlike 4.0 License](https://creativecommons.org/licenses/by-nc-sa/4.0/), which allows others to remix, tweak, and build upon the work non-commercially, as long as appropriate credit is given and the new creations are licensed under the identical terms.

For reprints contact: reprint@ipinnovative.com

1. Introduction

The elbow joint is in a fully extended and supinated position, forearm diverges laterally forming an angle with the upper arm. This is referred to as 'CARRYING ANGLE' or 'CUBITAL ANGLE'. Angle is neutralized when the forearm is flexed and pronated from an extended and supinated position.¹ The carrying angle of the elbow is generally regarded as being greater in females than in males and is considered to be a secondary sex characteristic.² The

carrying angle permits the forearms to clear the hips in swinging movements during walking and is important when carrying objects.³ This angle is $155-180^\circ$ or, if one uses the supplementary angle, usually $0-25^\circ$. The supplementary angle is the smaller angle of deflection.⁴ Supplementary angle = $180^\circ - \text{carrying angle}$. Various authors have used the term carrying angle for both the angles.⁵

Carrying angle is partly due to more distal position of the tip of the medial lip of the trochlea. A curved ridge joins the prominences of coronoid process and olecranon, the obliquity of the shaft of the ulna to this ridge accounts for most of the carrying angle at the elbow.⁶ Knowledge

* Corresponding author.

E-mail address: prabhakar55@gmail.com (T. Prabhakar).

of the carrying angle is important anthropologically for differentiation of sex. It is also useful for the reduction of common complications of supracondylar fractures. Loss or increase in carrying angle results in cosmetic deformities and also for designing total elbow prosthesis.⁷

2. Materials and Methods

Elbow X-rays were collected in various clinical laboratories and Amaltas Hospital in and around Dewas, Madhya Pradesh. The study was conducted at Amaltas Institute of Medical Science, Dewas. Totally 70 elbow radiographs of adults were collected which included 35 males and 35 females. The age ranged from 18 to 76 years, and the mean age was 35 years. The carrying angle was measured by drawing a line passing through the mid-axis of the lower third of the humerus and another line along the mid-axis of the upper third of the forearm passing in between the radius and ulna through a superior radioulnar joint. Both the lines were extended to meet at the midpoint of transepicondylar line where the angle was measured.¹

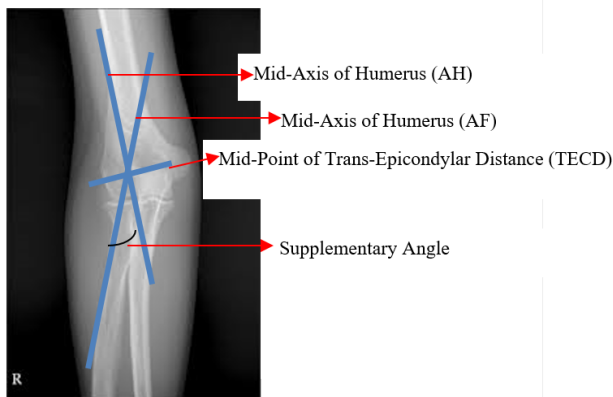


Figure 1: 1: Anteroposterior radiographic view of the right elbow of an adult female. It shows the carrying angle (*). The supplementary angle between the mid-axis of the humerus (AH) and the mid-axis of forearm (FA). The two lines (AH and AF) meet at the mid-point of Trans-Epicondylar Distance (TECD)

The bones show physiological growth between 1 to 16 years. So, we have selected x-rays between 16 to 40 years. Normal anteroposterior radiographic views with an extended elbow and fully supinated forearm were examined. Exclusion criteria: Age: below 15 years. i. Obliquity or rotation of view was excluded. ii. No rotation was censured by appreciating the two humeral epicondyle and slight superimposition of the radial head, neck and tuberosity over the proximal ulna excluded. iii. Subjects with cubitus valgus and varus deformities. iv. Subjects undergone supracondylar fracture and total elbow arthroplasty are excluded.

3. Result

Statistical analysis is in which Mean, Standard Deviation (SD) and t-test were included to assess any Gender differences. The level of significance was defined as a p-value of less than 0.0001.

The angle is significantly greater in females than in males. In males, it ranges from 8.80° to 18.50° with a Mean and SD of 14.3±2.74°, while in females it ranges from 17.60° to 29.80° with a Mean and SD of 21.92±3.17°. P value is <0.0001⁴.

4. Discussion

Knowledge of the measurement of the carrying angle of the elbow and its variations is important to evaluate traumatic elbow injuries in elbow disorders. Punia et al. did not find any significant difference between males and females. We found a greater difference between males and females. Purkait R. and Chandra et al. studied the carrying angle by measuring the trochlear angle and the olecranon-coronoid angle. According to them, the olecranon-coronoid angle showed a statistically significant difference between males and females.^{2,8} In our study, the angle was measured between the longitudinal axis of the arm and the forearm, which showed a greater gender difference. Yilmaz et al.⁹ confirmed a greater difference between males and females, which supports the present study. Park S., Kim E., et al.¹⁰ used three-dimensional radiographs to measure the carrying angle, but we used image 'J' software to measure the carrying angle. Both the studies showed a greater gender difference.

Greater carrying angle in females can be considered their secondary sexual characteristic because there is no difference in carrying angle between males and females until puberty, after which it increases in females.⁵ It might also be due to their increased joint laxity, allowing a greater degree of elbow extension and hence a greater carrying angle.^{11,12} Steel FLD et al.⁶ (1958) studied the carrying angle in the left upper limb of 100 adults (50 males and 50 females) in London using radiographs.

The measurement of carrying angle was done using a goniometer by Paraskevas G et al.,⁵ showing 12.230 ± 0.30 in males and 15.770 ± 0.410 in females. When these angles were compared with our study, they showed a greater angle difference. Khane GN et al. found that carrying angle is inversely related to the height of the person. But we consider only the gender difference.¹³

Papadopoulos and Paraskevas G. et al.⁵ found an increased carrying angle in the dominant upper limb compared to the opposite upper limb. Our study is invariable on the sides of the upper limb. Bernardo Barellos and Terra et al.¹⁴ stated that the carrying angle physiologically increases as age progresses. The angle gradually increases from childhood to sixteen years of age. We have selected X-

Table 1: Comparison of carrying angle between male and female

Gender	N(samples)	MEAN	STD DEV	STD ERR	Minimum	Maximum
Female	35	21.92°	3.17°	0.63°	17.60°	29.80°
Male	35	14.36°	2.74°	0.54°	8.80°	18.50°
diff (1-2)		7.5360	2.9719	0.8406	-	-

Table 2: Shows the variance

Method	Variances	DF	Pr> t
Pooled	Equal	48	<.0001
Satterthwaite	Unequal	47.014	<.0001

rays from 16–40 years to exclude physiological variation. Potter, Afkison, and Elftman considered the carrying angle a secondary sex characteristic, which is much more significant in our study with an increased carrying angle in females than males.^{12,15}

Considering our studies and comparing the values, it is clear that a greater angle in females than males was observed, showing a great gender difference. The mean and standard deviation in males is $14.3 \pm 2.74^\circ$ and $21.92 \pm 3.17^\circ$ in females.

5. Conclusion

The present study was conducted to compare the carrying angle values of males with those of females. The study was conducted in the Dewas region of Madhya Pradesh, and it included 70 radiographs (35 males and 35 females) from the age group of 16–40 years. We conclude the present study, which confirms a significant gender difference in the carrying angle between females and males. By considering the above fact, the gender of an individual can be identified in the radiographs. Values may assist the orthopaedics in correcting the elbow deformities.

6. Source of Funding

None.

7. Conflict of Interest

None.

References

- Ahmad N. The bends and flexures of forearm and elbow x-ray positioning; 2002. Available from: <https://www.auntminnie.com/clinical-news/digital-x-ray/article/15563584/the-bends-and-flexures-of-forearm-and-elbow-x-ray-positioning#:~:text=Positioning%20for%20a%20lateral%20projection,long%20axis%20of%20the%20forearm.>
- Purkait R, Chandra H. An anthropometric investigation into the probable cause of formation of carrying angle: A sex indicator. *J Indian Acad Forensic Med.* 2004;26:14–9.
- Snell RS. *Clinical Anatomy.* 7th ed. New York: Lippincott Williams and Wilkins; 2004.
- Beals RK. The normal carrying angle of the elbow. A radiographic study of 422 patients. *Clin Orthop Relat Res.* 1976;119:194–6.
- Paraskevas G, Papadopoulos A, Papaziogas B, Spanidou S, Argiriadou H, Gigis J. Study of the carrying angle of the human elbow joint in full extension: a morphometric analysis. *Surg Radiol Anat.* 2004;26(1):19–23.
- Steel FLD, Tomlinson JDW. The 'carrying angle' in man. *J Anat.* 1958;92(Pt 2):315–7.
- Punia RS, Sharma R, Usmani JA. The carrying angle in an Indian population. *J Anat Soc India.* 1994;43(2):107–10.
- Chang CW, Yi-Chian W, Chang-Hung C. Increased Carrying Angle is a Risk Factor for Nontraumatic Ulnar Neuropathy at the Elbow. *Clin Orthop Relat Res.* 2008;466(9):2190–5.
- Yilmaz E, Karakurt L, Belhan O, Bulut M, Serin E, Avci M. Variation of the carrying angle with age, sex and special reference to side. *Orthopedics.* 2005;28(11):1360–3.
- Kim E, Park SJ, Lee HS, Park JH, Park JK, Ha SH, et al. In vivo 3-dimensional Kinematics of Cubitus Valgus after Non-united Lateral Humeral Condyle Fracture. *Clin Shoulder Elb.* 2018;21(3):151–7.
- Khare GN, Rai SK. Carrying angle in boys and girls of eastern part of India. *Indian J Orthop.* 1998;32:7–14.
- Mcminn RMH, Potter HP. The obliquity of the arm of the female in extension. The relation of the forearm with the upper arm in flexion. *J Anat Physiol.* 1895;29(Pt 4):488–91.
- Khare GN, Goel SC, Saraf SK, Singh G, Mohanty C. New observations on carrying angle. *Indian J Med Sci.* 1999;53(2):61–7.
- Terra BB, Silva BCM, Bella H. Evolution of the carrying angle of the elbow: a clinical and radiographic study. *Acta Ortop Bras.* 2011;19(2):79–82.
- William A, Herbert E. The carrying angle of the human arm as a secondary sex character. 2005;91:49–52.

Author biography

T Prabhakar, Associate Professor  <https://orcid.org/0009-0004-4141-4012>

Vinodkumar Gurram, Assistant Professor

Eshwari R, Researcher

Cite this article: Prabhakar T, Gurram V, Eshwari R. Radiological study of carrying angle among male and female and its clinical importance. *Indian J Clin Anat Physiol* 2024;11(1):50-52.