



Original Research Article

Anthropometric study of the bicipital groove in Kolkata based population and its clinical implication

Srijit Narayan Chaudhuri¹, Mithu Paul², Subhajit Halder³, Oyndrila Sengupta^{4*}

¹Dept. of Anatomy, Santiniketan Medical College, Bhatara, West Bengal, India

²Dept. of Anatomy, Midnapore Medical College and Hospital, Midnapore, West Bengal, India

³Dept. of Anatomy, Calcutta National Medical College, Kolkata, West Bengal, India

⁴Dept. of Anatomy, Murshidabad Medical College, Murshidabad, West Bengal, India



ARTICLE INFO

Article history:

Received 17-12-2021

Accepted 05-05-2022

Available online 07-12-2023

Keywords:

Bicipital groove

Humerus

Humeral prosthesis

Surgical neck of humerus

ABSTRACT

Background: The knowledge of the humeral morphology is an important tool in determination of the prosthetic size, its positioning and also its design. Reconstructive surgery of upper end of humerus requires measurement of intertubercular sulcus.

Aim and Objective: In this descriptive and cross sectional study it was attempt to study the clinical correlation of length, depth and width of the bicipital groove with antero-posterior and transverse diameters of surgical neck of the dry humeri, for their use in the betterment of human humeral prosthesis.

Materials and Methods: The study was conducted on 100 adult dry intact human humeri collected from different medical colleges of Kolkata in the department of Anatomy, Calcutta National Medical College, Kolkata.

Statistical analysis used: This study analysis was done in SPSS 23 Software. Independent sample-'t' test was used for statistical analysis. P-value <0.05 was considered to be significant.

Result: The difference of anthropometric dimensions of left humeral bicipital groove are more significant as compared to right. There is strong statistical correlation between length of Bicipital Groove vs Total Length of Humerus, Width of Bicipital Groove vs. Transverse Diameter at surgical neck

Conclusion: To conclude, with minor differences from previous similar studies the present study is noteworthy in the field of prosthetic limb manufacture.

This is an Open Access (OA) journal, and articles are distributed under the terms of the [Creative Commons Attribution-NonCommercial-ShareAlike 4.0 License](https://creativecommons.org/licenses/by-nc-sa/4.0/), which allows others to remix, tweak, and build upon the work non-commercially, as long as appropriate credit is given and the new creations are licensed under the identical terms.

For reprints contact: reprint@ipinnovative.com

1. Introduction

The data on anthropometric study on the upper end of humerus is minimum. The study of the anatomy of the humerus is related to the prosthetic replacement, fracture reduction and placement of the lateral pin at the upper end of humerus. Anterior Aspect of the upper end of humerus presents a unique feature - bicipital groove. Bicipital groove is present in between the greater and lesser tubercle of humerus, it is continued for about 5 cms on the shaft of

the bone.¹ This sulcus has lateral lip, medial lip and floor. Tendon of pectoralis major is inserted to the lateral lip, and teres major to the medial lip. The latissimus dorsi is inserted to the floor. The contents of the groove is tendon of long head of the biceps brachii muscle with synovial membrane and the ascending branch of the anterior humeral circumflex artery.^{2,3} Transverse humeral ligament bridges the two tubercles and form a tunnel or acts as a retinaculum through which the long tendon of biceps brachii passes through. Coracohumeral ligament lies on the transverse humeral ligament and becomes continuous with rotator cuff. Subluxation of shoulder joint is prevented by the above

*Corresponding author.

E-mail address: sanskritabrata@gmail.com (O. Sengupta).

mentioned structures. Moreover they keep the tendon of long head of biceps in position and facilitate free and easy movement of shoulder joint.⁴

Shoulder joint pain and diseases are often due to problem in intertubercular sulcus and its contents. So, the aim of the study was to determine the variation of length, width and depth of the intertubercular sulcus.

Recently there has been an upsurge and renewed interest on anatomical knowledge of the sulcus regarding its morphology and morphometry due to development of various advanced shoulder reconstruction techniques for selection of suitable prosthesis device.⁵ The present study has attempted to further enrich the knowledge about the intertubercular sulcus and hence its clinical implication.

2. Aims and Objectives

Though this kind of study had been done previously but the more specimens are taken under consideration the further enrichment of the knowledge will be there as the nature is ever changing and ever evolving. So to serve humankind every little effort of observation will add a small drop in the ocean of medical knowledge. In this study determination of the variation of the dimensions of the intertubercular sulcus of the humeri was one of the main aims. Determination of the co-relation of the length, width, depth, transverse diameter at surgical neck and antero-posterior diameter at surgical neck of the humeri was also part of the objective of this study. More over to observe the presence of the supratubercular ridge of Meyer (STR) in the humeri was also an aspect. To compare the data obtained from the present study, with the similar data found in the previous study and finally to apply the observation of present and past studies for betterment of the technological development in preparation of shoulder joint prosthesis and lateral pins insertion were the aims and objectives of the present study.

3. Materials and Methods

This observational and descriptive study was done in the Anatomy Department, Calcutta National Medical College, Kolkata. 100 dry adult bones i.e humeri including both right and left sides were taken from anatomy departments of Calcutta National Medical College, KPC Medical College, IPGME&R, and NRS Medical College & Hospital. Intact and fully ossified dry humeri were included. Humeri with gross congenital or pathological abnormality and broken, fragmented or fragile humeri were excluded. The study was carried out during the period of 12.06.2017 to 12.08.2018.

Sample size was determined by taking into account the sample sizes of previous similar studies. Complete enumeration was done here.

Total Length of humeri (TLH), Length of Bicipital Groove (L-BG), Width of Bicipital Groove (W-BG), Depth of Bicipital Groove (D- BG), Antero Posterior diameter at

surgical neck of humeri (APD) and Transverse Diameter at surgical neck of humeri (TVD) were the variables which were measured.

The data collection form, Vernier slide caliper, ruler, paper, pen, marker, gloves and none the less the Osteometric board were used to perform the study.

3.1. Procedure

The present study was performed on unpaired 100 dried cadaveric humeri 41 belonging to the right side and 59 to the left side of unknown age and sex, collected from different medical colleges of Kolkata. The humeri which exhibited damage or any pathological changes were excluded from the present study. Total length, antero-posterior and transverse diameter at surgical neck of humeri, along with length, width, depth of BG were measured. The total length was measured with the help of osteometric board. The anteroposterior and transverse diameter at surgical neck along with other parameters like length, width, depth of bicipital groove were analyzed by Vernier caliper. The length of the BG were determined by the maximum distance between most proximal and distal point of the groove.

3.2. Statistical analysis

Initially data were collected. Thereafter they were compiled in Microsoft office excel 2010 and presented in tables and diagrams after compilation. The results were expressed in proportion and percentages. This study analysis was done in SPSS 23 Software. Independent sample- 't' test was used for statistical analysis. P value of <0.05 was considered to be significant while analysing Pearson correlation coefficient significance.

3.3. Ethics approval

Permission of Ethics Committee – Institutional ethics committee provided the approval after thorough review and discussion of the study synopsis submitted and presented before the committee. The ethical clearance number is Anat CNMC 76/2016 dated 06/12/2016.

4. Result and Analysis

The statistical significance were observed, when the data of right and left side of W-BG and the D-BG are compared as the p values were 0.02 and 0.03 respectively.

No statistical significance were observed when the data of right and left side of length of bicipital groove (L-BG), total length of humerus (TLH), transverse diameter surgical neck and anteroposterior diameter at surgical neck are compared.

However, Supratubercular Ridge was not observed on any humerus in the present study.

Table 1: Morphometric parameters of humerus and bicipital groove

Parameters	Right	Left	P value
L_BG (mm)	67.63 ± 8.99	70.69 ± 8.64	0.09
W_BG (mm)	9.42 ± 1.41	10.04 ± 1.340	0.02 *
D_BG (mm)	5.14 ± 1.07	5.59 ± 1.01	0.03 *
TLH (mm)	294.44 ± 19.05	293.02 ± 20.63	0.72
TD at surgical neck (mm)	24.56 ± 2.69	25.38 ± 3.26	0.17
APD at surgical neck (mm)	21.41 ± 3.46	20.90 ± 2.87	0.43

* Significant

NOTE: L_BG: Length of Bicipital groove, W_BG: Width of bicipital groove, D_BG: Depth of bicipital groove, TLH: Total length of humerus, TD: Transverse diameter, APD: Anteroposterior diameter. Unpaired t-test is used.

Table 2: Comparison of anthropometric parameters of intertubercular sulcus between present and previous studies

Authors	Place of study	Sample size	L-BG (mm)	W-BG (mm)	D-BG (mm)	STR (%)
Waefae et al 2010 ⁶	Brazil	50	81	10.1	4	-
Cone et al 1983 ⁷	V.A.M.C USA	158	-	8.8	4.3	50
Abboud et al 2010 ⁸	Pennsylvania Hospital, Philadelphia	75	-	-	5.1	-
Murlimanju et al 2012 ¹⁴	Kasturba Medical College, Manipal University	104	86.0 ± 10.1	8.3 ± 2.4	4.7 ± 2.0	15.4
Right			83.3 ± 11.5	8.7 ± 2.2	4.2 ± 1.6	7.7
Left						
Rajani et al 2013 ⁹	AIIMS, Rishikesh, Uttarakhand	101				17
Right			85 ± 09	9.0 ± 2.1	5.0 ± 1.0	
Left			83 ± 10.1	8.9 ± 1.1	6.0 ± 1.0	20
Rajan et al 2016, ¹⁰	Sri Ramachandra Medical College and Research Institute, Chennai	100				
Right			84.79 ± 5.84	1.84±1.01	4.21 ± 0.58	17
Left			87.33 ± 6.40	7.74 ± 1.96	5.01 ± 1.05	14
Arunkumar et al 2016 ¹¹	Dhanalakshmi Srinivasan Medical College & Hospital. Tamil Nadu.	98	83	8.4	5	26.5
Gupta et al 2015 ¹²	Kasturba Medical College	60	74.1	10.8	5.5	-
Phalguni et al ¹³	Calcutta National Medical College Kolkata	107				-
Right			71.54 ± 3.78	8.42 ± 0.85	4.63 ± 3.8	
Left			70.78 ± 5.04	7.7 ± 0.50	4.45 ± .30	
Present study						
Right			67.63 ± 8.99	9.42 ± 1.41	5.14 ± 1.07	-
Left			70.69 ± 8.64	10.04 ± 1.34	5.59 ± 1.01	

The Table 2, shows the comparison of the anthropometric parameters of bicipital groove between present and after previous studies.

This table shown the correlation between the Length of Bicipital Groove vs. Total Length of Humerus of right and left side, Width of Bicipital Groove vs. Transverse Diameter at surgical neck of humeri of right and left side

Significant statistical correlation was observed in left humeral Length of Bicipital Groove vs. Total Length of Humerus and Width of Bicipital Groove vs. Transverse

Diameter at surgical neck as the correlation coefficient and p values were 0.602 and 0.000 in the first one and similarly in the second one, the values were '0.507' and '0.000' respectively. In the third one (Depth of Bicipital Groove vs Antero Posterior Diameter at the surgical neck of the humeri) the Pearson's Co-relation coefficient was near to the significant side.

Where as significant correlation exist in right humeral Width of Bicipital Groove Vs. Transverse Diameter at Surgical Neck of Humerus. Medium strength of significance

Table 3: Showing the Pearson Correlation Coefficients and corresponding p-values of Right and Left measurements

	Right	Left
Length of Bicipital Groove Vs. Length of Humerus	Pearson Correlation Coefficient: 0.352* p-Value: 0.024	Pearson Correlation Coefficient: 0.602* p-Value: 0.000
Width of Bicipital Groove Vs. Transverse Diameter at Surgical Neck of Humerus	Pearson Correlation Coefficient: 0.514* p-Value: 0.001	Pearson Correlation Coefficient: 0.507* p-Value: 0.000
Depth of Bicipital Groove Vs. Antero Posterior Diameter at Surgical Neck of Humerus	Pearson Correlation Coefficient: 0.126 p-Value: 0.434	Pearson Correlation Coefficient: 0.212 p-Value: 0.107

*(indicates that the correlations are significant at 0.05 level of significance)

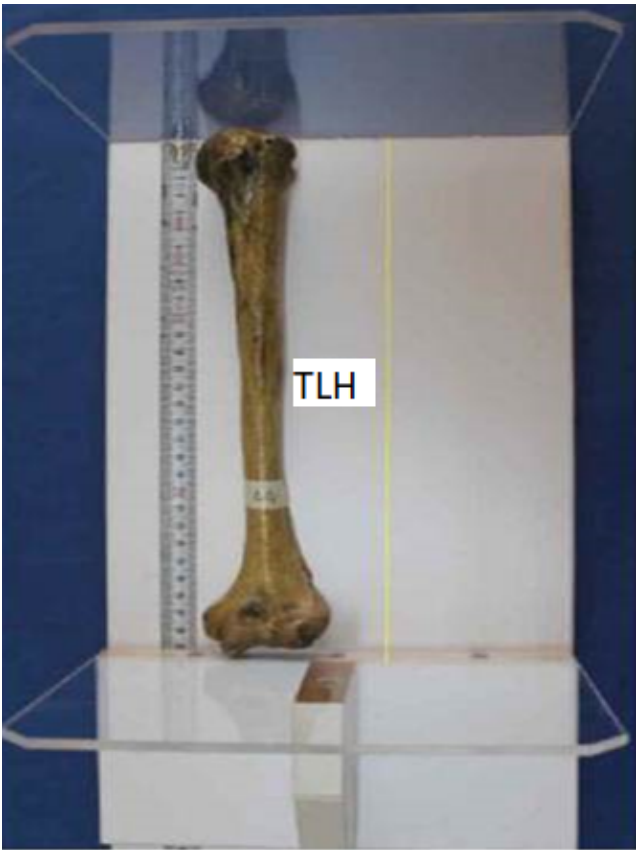

Figure 1: Measurement of total length of humerus by osteometric board

was found in right humeral length of BG vs. Total humeral length.

5. Discussion

Variation is the rule in God’s creation. The human body is not exception to this law. Some variations which may be developmental on acquired can give rise to abnormal functioning of the of the human physiology. Morphometric variations are not uncommon in intertubercular sulci of humerii. Functioning of the tendon of long head of biceps brachii is intimately dependent on intertubercular sulcus morphometry.^{15,16}

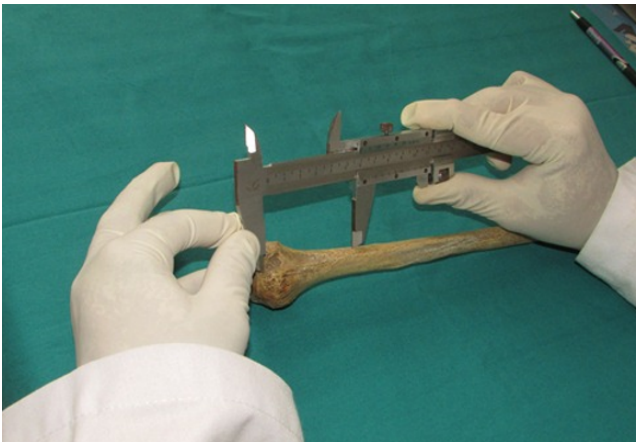

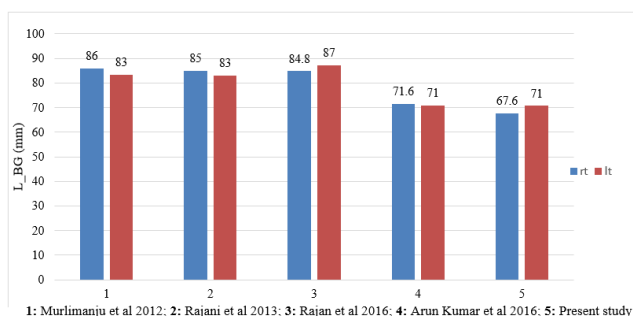
Figure 2: Method of measurement of the length of bicipital groove of humerus



Figure 3: Method of measurement of the Transverse diameter of surgical neck of humerus

Humeral dimensions are correlated with different dimension of the intertubercular sulcus. Measurement of length, width and breadth gives the idea about anthropometry of the sulcus.¹⁷

rovides with a quick view regarding comparison of the present study with previous relevant studies.



Graph 1: Comparison between the data of length of bicipital groove of right side and left side in previous and present study.

Greater will be the stability of the biceps tendon depending on the length of the intertubercular sulcus. This increases the freedom of multidirectional movement of the shoulder joint. Rajani S, Man S and Rajan YS, Kumar SKS conclusively reported length of medial and lateral walls of bicipital groove of both sides.^{9,10} But in this study the length of the walls were not measured separately. Average total length of the sulcus was measured which was compared with that of previous studies and found to be lower^{11,12,18} and was close to the finding of Phalguni Srimani, Ritaban Saha, Biplab Goswami, Sibani Mazumdar.¹³ The retention of biceps tendon can be mostly taken care by the depth of the groove. In this respect, width of the present study compared with those of similar parameters reported by other authors.^{6,9,11,14,18}

According to Cone RO, Danzig L, Resnick D, Goldman AB, wide groove of more than 17 mm are often shallow which may predispose subluxation or dislocation of tendon⁷. Shallow groove is mostly responsible for impingement and chronic trauma of the tendon by the overlying acromion bone and coracoacromial arch. On the other hand deep groove is more likely to cause constriction of the tendon as hypothesized by DePalma.¹⁹

A shallow and wide groove is more likely responsible subluxation / dislocation of biceps tendon frequently than a deep and narrow groove which rather cause irritation and tenosynovitis. Therefore, measurement of width and height of biceps tendon were undertaken by Rajani and Man to reach precise definition of narrow and shallow groove.⁹

Sex related difference of bicipital groove in terms of width and depth were observed by Pfahler M, Branner S, Refior HJ.²⁰ Gender based differences regarding length and depth of intertubercular sulcus were discussed by Kaur and Gupta.³

In the present study the morphometric parameters of bicipital groove were statistically more significant on the left side as compared to the right side. This observation goes against the explanation of exertion of higher pressure by long tendon of right side (as in manual workers) as

proposed by Vettivel S and Others.²¹ This may be due to the presence of higher number of left sided sample in present study (of humeri). In present study, it was seen that there is strong statistical correlation between L-BG VS TLH, W-BG vs. TD at surgical neck whereas in the previous study it was observed the percentile relation of the above stated parameters.^{12,17}

Humans are unique among primates in presenting dimension of intertubercular sulcus as mentioned by Rock Wood and Masten.¹⁷

The lack of smoothness of the floor of intertubercular sulcus may be ascribed on chronic tenosynovitis of the biceps tendon or due to repeated friction of the tendon with walls of the sulcus during manual labour works.^{3,14,22}

The concept of MHA was proposed by Hitchcock and Bechtol.²³ Right handedness in majority of population may be responsible for substantial reduction of the angle of medial wall of the intertubercular sulcus of right humerus. With increase in pressure by the tendon of biceps brachii the angle is reduced more and more as shown by Kaur M, Gupta R and Arun Kumar KR, Shalini R.^{3,11} The study of Srimani P and Others also matched with the previous study.¹³ Levinsohn and Santelli reported the flattened medial wall of intertubercular sulcus results into medial dislocation of biceps long head, but Cone et al¹⁰ observed no such correlation. Vettivel et al in their study documented wider sulcus with more acute medial wall angle were associated with dominant side and therefore reported morphometry of intertubercular sulcus as indicator of handedness.²¹

According to O Donoghue, medial wall angle $< 30^{\circ}$ may predispose to subluxation and obtuse ($>90^{\circ}$) to tenosynovitis by causing restriction of movements by the biceps tendon.¹⁵

Medial dislocation of long head of biceps brachii may be prevented by presence of supratubercular ridge (STR) as it may help gradual change of direction of the tendon by lifting it laterally.¹⁶ Bicipital tenosynovitis may be associated with presence of supratubercular ridge.²³ But it may be a different picture as forward displacement of the Biceps tendon may be favoured due to the presence of STR as stated by Nevaizer RJ. This also may result as a primary cause of the lesion of the long head of Biceps brachii.²⁴

Presence of STR is observed in about 50% subjects according to Cone RO, Danzig L, Resnick D, Goldman AB.⁷

Medial displacement of long head of biceps from the groove can be prevented due to the presence of STR as observed by Vettivel et al.²¹

But Arun Kumar KR, Shalini R. and Murlimanju et al^{11,14} observed very low incidence of STR as 18.1% and 15.4% on right and 8.4% and 7% on the left side.

Rajan and Kumar observed 17% on the right side and 14% left side quit similar to observations made by Rajani and Man.^{9,10}

I have failed to observe STR in any specimen in my study may be due to population, racial and regional variations which may be investigated later.

6. Limitation

In the present study there were limitation of any knowledge Age, Sex, Height, Weight, BMI of the specimen of Bones taken and no knowledge of the occupation or the activity pattern of the subjects is known. Else a functional correlation with the value of anthropometric data may be possible.

No scope of parameter of MWA be made in the present study.

Recently there are lots of advancement in medical science so the results of the sophisticated tools

and imaging techniques^{5,13} may be different from the method used in the present study.

7. Conclusion

Presently the incidence of shoulder pain and disability is increasing daily. Sometimes no obvious cause could be determined initially as whether it is Medical or Anatomical. Assessment of Bicipital Groove Anatomy could be a part to provide information for both Diagnostic and Therapeutic intervention. There is very little differences observed between past and present study still the knowledge of present study highlighting the anatomical variant of Bicipital Groove could be relevant and clinically noteworthy. Specially the morphometric correlation between the Total Length of Humerus vs Length of Bicipital Groove and Transverse Diameter at surgical neck vs. width of the Bicipital Groove bears a significant statistical value (Pearson's correlation coefficient). So in geographically diversified places this type of study may be helpful in correlating Anatomical and population variation.

8. Contribution Detail

Dr. Srijit Narayan Chaudhuri: Concept, Design, Data acquisition, Data analysis.

Dr. Mithu Paul: Data acquisition, Definition of intellectual content

Dr. Subhajit Halder: Manuscript preparation, Manuscript review

Dr. Oyndrila Sengupta: Statistical analysis, Manuscript preparation, manuscript editing.

9. Conflict of Interest

We the authors declare that there is no conflict of interest among us regarding this article.

10. Source of Funding

No financial support has been taken from any institute or organisation.

References

1. Joseph J. Textbook of Human Anatomy. In: Hamilton W, et al., editors. Locomotor system. London: Macmillan; 1976. p. 19–200.
2. Gray H, Standing S, Ellis H, Berkovitz B. Gray's anatomy : the anatomical basis of clinical practice. 39th Edn. Spain: Elsevier Churchill Livingstone; 2005. p. 823–32.
3. Kaur M, Gupta R. Morphometric and morphological study of bicipital groove in North Indian population. *Int J Basic Appl Med Sci*. 2015;5(3):48–53.
4. van Deurzen D, Garssen FL, Kerkhoffs G, Bleys R, Have IT, van den Bekerom M, et al. Clinical relevance of the anatomy of the long head bicipital groove, an evidence-based review. *Clin Anat*. 2020;34(2):199–208.
5. Robertson DD, Yuan J, Bigliani LU. Three-dimensional analysis of the proximal part of the humerus: relevance to arthroplasty. *J Bone Joint Surg Am*. 2000;82(11):1594–602. doi:10.2106/00004623-200011000-00013.
6. Wafae N, Santamaría L, Vitor L, Pereira LA, Ruiz CR, Wafae GC, et al. Morphometry of the human bicipital groove (sulcus intertubercularis). *J Shoulder Elbow Surg*. 2010;19(1):65–8.
7. Cone RO, Danzig L, Resnick D, Goldman AB. The bicipital groove: radiographic, anatomic and pathologic study. *AJR Am J Roentgenol*. 1983;141(4):781–8.
8. Abboud JA, Widmer BJ, Demola PM, Bartolozzi R. Bicipital groove morphology on MRI has no correlation to intra articular biceps tendon pathology. *J Shoulder Elbow Surg*. 2010;19(6):790–4.
9. Rajani S, Man S. review of bicipital groove morphology and its analysis in North Indian Population and its clinical implications. *ISRN Anat*. 2013;p. 243780. doi:10.5402/2013/243780.
10. Rajan YS, Kumar SKS. Morphometric Study on Bicipital Groove among South Indian Population. *J Clin Diagn Res*. 2016;10(7):1–3.
11. Arunkumar KR, Manoranjitham R, Raj UD, Shalini R. Morphometric study of Bicipital groove in South Indian Population and its clinical implication. *Int J Anat Res*. 2016;4(2):2187–91.
12. Gupta C, Jaiswal S, D'souza A. Anthropometric study of bicipital groove and its clinical implication. *Niger J Surg Sci*. 2015;25(1):1–3.
13. Srimani P, Saha R, Goswami B, Mazumdar S. Morphometric Analysis Of Bicipital Groove Of Humerus With Its Clinical Implications: A Study In West Bengal. *Int J Anat Res*. 2016;4(4):3009–15.
14. Murlimanju BV, Latha V, Pai MM, Shreya M, Prashanth KU, Kumar C, et al. Anthropometric study of the bicipital groove in Indians and its clinical implications. *Chang Gung Med J*. 2012;35(2):155–9.
15. Donoghue DO. Subluxing biceps tendon in the athlete. *Clin Orthop Relat Res*. 1982;April(164):26–9.
16. Levinsohn EM, Santelli ED. Bicipital groove dysplasia and medial dislocation of the biceps brachii tendon. *Skeletal Radiol*. 1991;20(6):419–23. doi:10.1007/BF00191083.
17. Rockwood CA, Masten FA. The Shoulder. vol. 2. Philadelphia: W. B. Saunders Company; 1992.
18. Murthi AM, Vosburgh CL, Neviasser TJ. The incidence of pathologic changes of the long head of the biceps tendon. *J Shoulder Elbow Surg*. 2000;9(5):382–5. doi:10.1067/mse.2000.108386.
19. Depalma AF. Surgical anatomy of the rotator cuff and the natural history of degenerative periarthritis. *Clin Orthop Relat Res*. 2008;466(3):543–51.
20. Pfahler M, Branner S, Refior HJ. 20. Pfahler M, Branner S, Refior HJ, The role of the bicipital groove in tendinopathy of the long biceps tendon. *J Shoulder Elbow Surg* 1999; 8:419–24. *J Shoulder Elbow Surg*. 1999;8(5):419–24.
21. Vettivel S, Indrasingh I, Chandi G. Variations in the intertubercular sulcus of the humerus related to handedness. *J Anat*. 1992;180(Pt 2):321–6.
22. Motagi M, Shankar N, Ravindranath R. Estimation of the angle of humeral torsion from digital images of dry humeri of South Indian origin. *Anatomy*. 2012;6:34–41.

23. Hitchcock HH, Bechtol CO. Painful shoulder; observations on the role of the tendon of the long head of the biceps brachii in its causation. *J Bone Joint Surg Am.* 1948;30(2):262–73.
24. Nevaizer RJ. Lesions of the biceps and tendinitis of the shoulder. *Orthop Clin North Am.* 1980;11(2):343–8.

Subhajit Halder, Assistant Professor

Oyndrila Sengupta, Assistant Professor

Author biography

Srijit Narayan Chaudhuri, Assistant Professor

Mithu Paul, Assistant Professor

Cite this article: Chaudhuri SN, Paul M, Halder S, Sengupta O. Anthropometric study of the bicipital groove in Kolkata based population and its clinical implication. *Panacea J Med Sci* 1012;13(3):619-625.