

# Maxillary Molar Intrusion Simplified Using Microimplants: A Case Report

Nehete AB<sup>1</sup>, Belsare NB<sup>2</sup>

**To cite:** Nehete AB, Belsare NB. Maxillary Molar Intrusion Simplified Using Microimplants: A Case Report. *Journal of Contemporary Orthodontics*, February 2018, Vol 2, Issue 1, (page 71-74)

**Received on:**  
06/10/2017

**Accepted on:**  
06/02/2018

**Source of Support:** Nil

**Conflict of Interest:** None

<sup>1</sup>Professor and PG guide, Department of Orthodontics and Dentofacial Orthopedics, MGVS KBH Dental College and Hospital, Nashik, Maharashtra: dramit0202@gmail.com

<sup>2</sup>Assistant Professor, Department of Prosthodontics, SMBT Dental College and Hospital, Sangamner, Maharashtra: drnehabelsare@gmail.com

## ABSTRACT

Supraeruption of the maxillary molars because of loss of the opposing teeth creates occlusal interference, functional disturbances and increased complexity of restoring edentulous space. The purpose of this case report is to demonstrate the use of orthodontic microimplants for intrusion of maxillary 1<sup>st</sup> molars. A 24-year-old girl with an supraerupted maxillary right 2<sup>nd</sup> premolar and 1<sup>st</sup> molar encroaching on the opposing mandibular edentulous space were successfully intruded using two well placed microimplants and partial fixed appliance. Two orthodontic microimplants on either side provides a simple, balanced and predictable force system for true intrusion of the molars.

**Keywords:** Molar intrusion, Microimplants, Supraerupted molars.

## INTRODUCTION

Loss of the mandibular first molar often results in supraeruption of the opposing teeth, resulting in occlusal interference and functional disturbances, compromised periodontal health and increased complexity of restoring edentulous space. Leveling the maxillary posterior occlusal plane often requires invasive prosthodontic reduction with root canal treatment, surgical impaction or full fixed appliance therapy along with extraoral headgear.<sup>1,2</sup> The orthodontic microimplants has provided the clinician with a simpler and more efficient means of molar intrusion.

This article demonstrates how molar intrusion can be quickly and effectively achieved with partial fixed appliance and two well positioned microimplants.

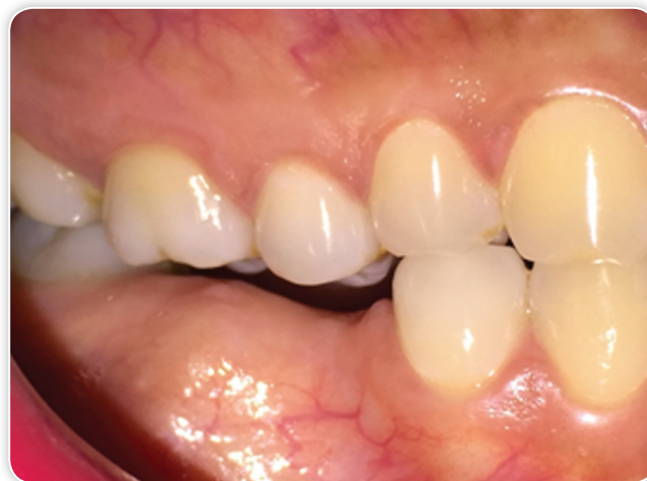## CASE HISTORY

A 24-year-old female patient reported for replacing missing teeth in lower right posterior quadrant. Past dental history revealed extraction of lower right 2nd premolar and 1st molar 4 year back because of decay. Patient was medically fit, healthy and had a hyperdivergent growth pattern. Intraoral examination revealed missing lower right 2nd premolar and 1st molar, supraerupted upper right 2nd premolar and 1st molar, well aligned arches, slight spacing in lower anterior region, midline discrepancy and class I occlusion. Her gingival condition was

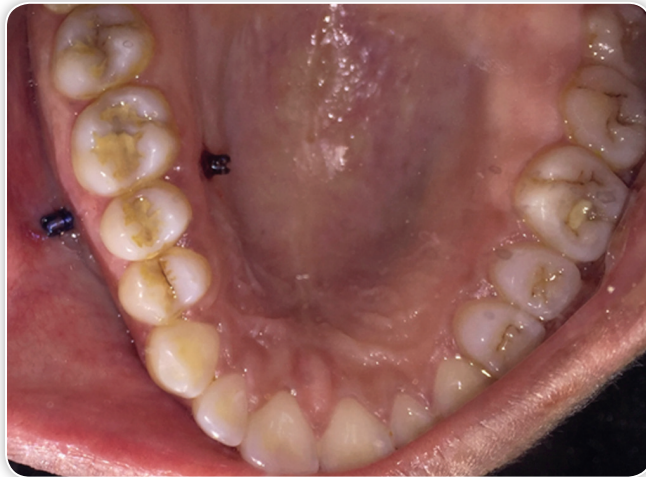fair. According to marginal ridge discrepancy upper right 2nd premolar and 1st molar supraerupted by 2.5 mm (Fig. 1).

The objective of the treatment was to intrude the supraerupted upper right 2nd premolar and 1st molar with the help of orthodontic microimplants and partial fixed appliance and subsequently regain vertical clearance for the prosthesis.

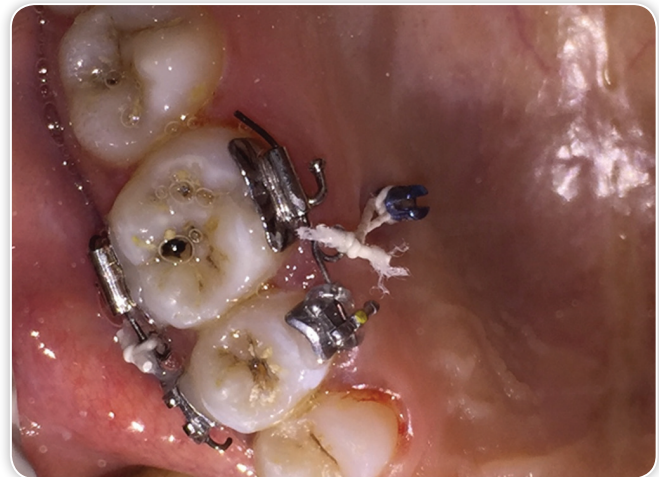Two microimplants 1.3 mm × 8 mm (S.K. Surgicals, Pune) were used for anchorage, one was inserted buccally in the interdental area between upper right 2nd premolar and 1st molar at the mucogingival junction with an angle of 45° to the



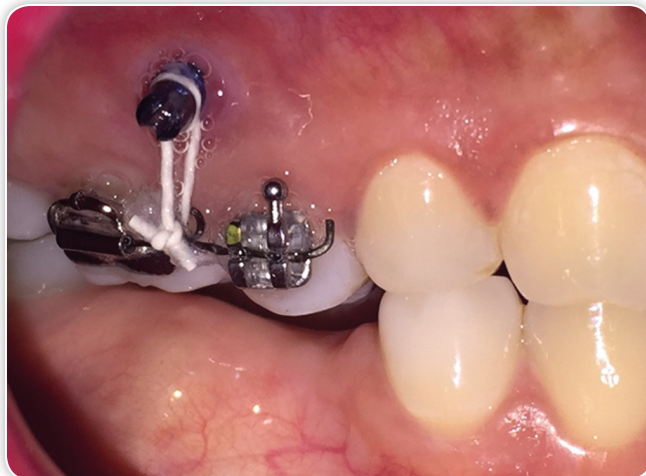
**Figure 1** Pretreatment intraoral right buccal view



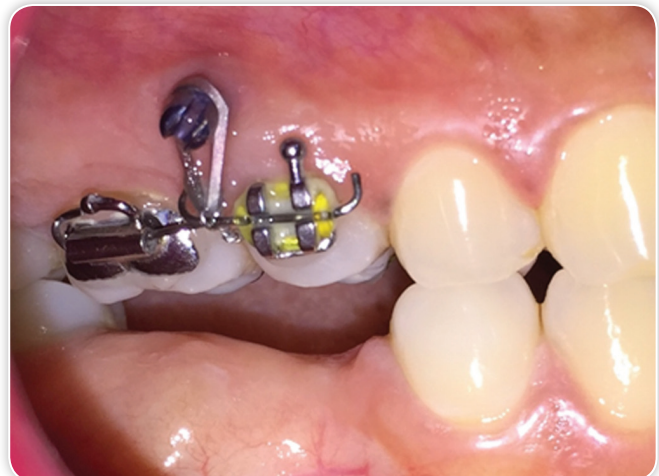**Figure 2** Orthodontic microimplants inserted buccally and palatally between maxillary 2nd premolar and 1st molar



**Figure 4** Palatal sectional fixed appliance and elastic thread tied from head of buccal microimplant upto hook on archwire



**Figure 3** Buccal sectional fixed appliance and elastic thread tied from head of buccal microimplant upto hook on archwire



**Figure 5** Intraoral right buccal view showing leveled maxillary occlusal plane

long axis of the teeth (Fig. 2). The second microimplant was inserted on the palatal slope in the same region around 7 to 8 mm from the alveolar crest. Both microimplants were inserted under topical anesthesia using self-drilling mechanism.

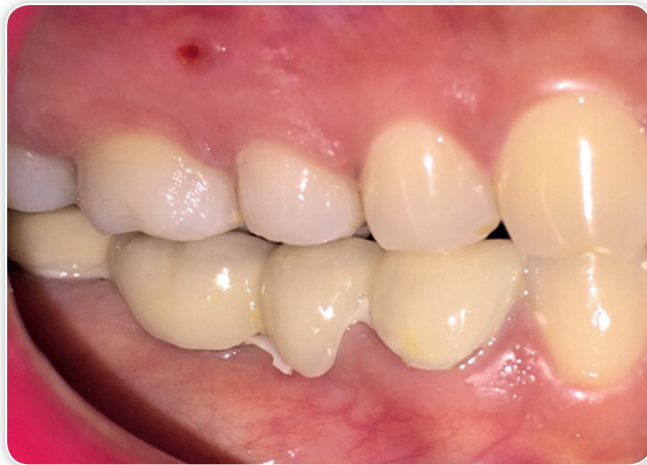0.022" slot edgewise brackets and molar tubes and were bonded to buccal and palatal aspects of upper right 2nd premolar and 1st molar. A 0.018" round stainless steel wire segments with hook in the center was ligated to the brackets both buccally and palatally. These wires were cinched at either end. An elastic thread was tied from heads of microimplants upto the hook to generate intrusive force (Figs 3 and 4).

Approximately 100 gm of force was applied on each side to intrude both upper right 2nd premolar and 1st molar. After one month to facilitate intrusion two thick elastic separators were used, one was inserted mesial to 2nd premolar and other was

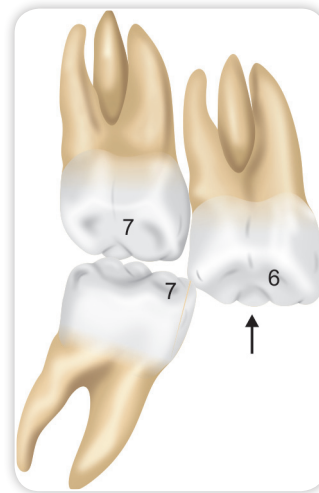
inserted distal to 1st molar. At the interval of six weeks, elastic threads were changed. After 5 months of active treatment upper right 2nd premolar and 1st molar were intruded and maxillary occlusal plane was leveled (Fig. 5). After leveling maxillary occlusal plane alveoloplasty was done to improve surface contour of edentulous area and gain vertical clearance for replacing missing teeth. Then after one month of healing the missing teeth were replaced with fixed prosthesis (Fig. 6). Because of financial reason patient opted for four unit bridge.

## DISCUSSION

Effective molar intrusion is a challenging task and highly unpredictable especially when it is done by conventional orthodontic mechanics. In existing methods to secure



**Figure 6** Post-treatment Intra-oral right buccal view



**Figure 7** Door wedge effect

anchorage either complete fixed appliance is required or complex appliance has to be designed. Despite the effort, efficient molar intrusion is difficult to accomplish.

The introduction of orthodontic microimplants, has provided the clinician with a simpler, efficient and reliable means for achieving true molar intrusion. Their simple design makes them comfortable to the patient and the implantation technique is relatively simple.

Numerous authors, employing various treatment modalities, have described intrusion of supraerupted maxillary molars. Sherwood demonstrated the use of titanium miniplates as skeletal anchorage for molar intrusion.<sup>3</sup> The intrusive force was limited to the buccal aspect of the extruded molar and buccal tipping of the molar was counteracted by an auxiliary archwire. Lee and Shuman used single microimplant, segmental wire and transpalatal arch for intruding maxillary molar.<sup>4</sup> Sivakumar demonstrated intrusion of maxillary molar with a single palatal microimplant and .017" × .025" TMA helical spring along with partial fixed appliance.<sup>5</sup> Kravitz used two miniscrews i.e. one buccal between 1st and 2nd molar and other palatal between 2nd premolar and 1st molar for intruding 1st molar.<sup>6</sup> Intrusion force of 100 gm was applied with closed power chain extending from buccal to palatal microimplant.<sup>6</sup>

This case demonstrated an effective mechanism using two miniscrews and partial fixed appliance to intrude supraerupted upper right 2nd premolar and 1st molar. One miniscrew was placed in the buccal dentoalveolus between 2nd premolar and 1st molar at the level of the mucogingival junction; the second was placed in the palatal slope in the same region. The largest amount of maxillary interradicular bone in the mesiodistal

direction, buccally and palatally is between 2nd premolar and 1st molar.<sup>7-9</sup>

Prior to applying intrusive force, it may be necessary to create adequate space between supraerupted tooth and its adjacent teeth. In particular, the mesial surface of the posterior tooth often leans against the distal surface of the supraerupted molar below its height of contour (Fig. 7). This door-wedge effect<sup>6</sup> impedes intrusion and often requires placement of a thick elastic separator. The orthodontist should remove the separator once molar intrusion becomes clinically evident. Use of two miniscrews i.e. buccal and palatal effectively produces true intrusion lowering the chances of buccolingual tipping of supraerupted teeth.

Regarding the optimum force for intrusion, Burstone<sup>10</sup> suggested 20 gm force while Gianelly and Goldman<sup>11</sup> recommended 15 to 50 gm force for intruding single rooted teeth. Kalra et al<sup>12</sup> suggested about 90 gm per tooth for molar intrusion in growing children. In adult patients considering the number and the surface area of the posterior tooth roots, it is reasonable to apply intrusion forces 2 to 3 times greater than those applied on anterior teeth. We used 200 gm of total intrusive force for both 2nd premolar and 1st molar and obtained 0.5 mm of intrusion per month.

## CONCLUSION

A supraerupted maxillary molar can be successfully intruded using microimplants. Two orthodontic microimplants on either side provides a balanced and predictable force system for true intrusion of the molars.



**Address for Correspondence**

Nehete AB  
Professor and PG Guide  
Department of Orthodontics and Dentofacial Orthopedics  
MGVs KBH Dental College and Hospital  
Nashik, Maharashtra  
e-mail: dramit0202@gmail.com

## REFERENCES

1. Yao CC, Wu CB, Wu HY, Kok SH, Chang HF, Chen YJ. Intrusion of overerupted upper left first and second molars by mini-implants with partial-fixed orthodontic appliances: a case report. *Angle Ortho.* 2004;74:550-7.
2. Yao CC, Lee JJ, Chen HY, Chang ZC, Chang HF, Chen YJ. Maxillary molar intrusion with fixed appliances and mini-implant anchorage studied in three dimensions. *Angle Orthod.* 2005;75:754-60.
3. Sherwood KH, Burch JG, Thomson WJ. Closing anterior open bites by intruding molars with titanium miniplate anchorage. *Am J Orthod.* 2002;122:593-600.
4. Lee M and Shuman J. Maxillary molar intrusion with a single miniscrew and a transpalatal arch. *Journal Clinical Orthod.* 2012;46:48-51.
5. Sivakumar I, Sivakumar A. Intrusion of overerupted molar using orthodontic miniscrew implant: A preprosthodontic therapy. *Contemporary Clinical Dentistry.* 2014;5:422-4.
6. Kravitz ND, Kusnoto B, Tsay PT, Hohit WF. Intrusion of overerupted upper first molar using two orthodontic miniscrews. *Angle Orthod.* 2007;77:915-22.
7. Carano A, Velo S, Incorvati C, Poggio P. Clinical application of the mini-screw anchorage system (M.A.S) in the maxillary alveolar bone. *Prog Orthod.* 2004;5:212-35.
8. Schneile MA, Beck FM, Jaynes RM, Huja SS. A radiographic evaluation of the availability of bone for placement of mini-screws. *Angle Orthod.* 2004;74:832-7.
9. Poggio PM, Incorvati C, Velo S, Carano A. "Safe zones": a guide for miniscrew positioning in the maxillary and mandibular arch. *Angle Orthod.* 2006;76:191-7.
10. Burstone CR. Deep overbite correction by intrusion. *Am J Orthod.* 1977;72:1-22.
11. Gianelly AA, Goldman HM. *Biologic basis of orthodontics.* Philadelphia: Lea and Febiger; 1971.
12. Kalra V, Burstone CJ, Nanda R. Effects of a fixed magnetic appliance in the dentofacial complex. *Am J Orthod Dentofacial Orthop.* 1989;95:467-78.