



## Original Research Article

# Assessment of functional and radiological outcomes of closed reduction and K-wire fixation of supracondylar fracture of humerus in children

Deelipkumar Choudhary<sup>1</sup>, Shivanand C Mayi<sup>2</sup>, Ranganath N<sup>3,\*</sup><sup>1</sup>Dept. of Orthopaedics, Muzaffarnagar Medical College & Hospital College, Muzaffarnagar, Uttar Pradesh, India<sup>2</sup>Dept. of Orthopaedics, Ananta Institute of Medical Sciences and Research Centre, Nathdwara, Rajasthan, India<sup>3</sup>Dept. of Orthopaedics, KVG Medical College and Hospital, Sullia, Karnataka, India

## ARTICLE INFO

## Article history:

Received 10-09-2022

Accepted 30-11-2022

Available online 07-04-2023

## Keywords:

Supracondylar fracture

Closed reduction

Percutaneous pinning

Kwires

Cubitus varus

## ABSTRACT

**Introduction:** Supracondylar fractures of the humerus are commonly seen in children and are difficult to manage because of their unstable nature. It is difficult to maintain the reduction with splints. Non-operative treatment is associated with malunion and open reduction is more invasive procedure. Closed reduction of the fracture with percutaneous K-wire fixation is the preferred procedure with satisfactory results.

**Materials and Methods:** Children who came to the tertiary care hospital with a fracture in the supracondylar region following history of trauma to the elbow region and X-ray showing Gartland Type II and extension Type III fractures were included in this study. All these fractures were managed with closed reduction and fixation with K-wires inserted by percutaneous technique. Functional outcome and radiological union were noted.

**Results:** A total of 35 children were operated. About half of the study population were in the range of 6 to 8 years. Majority of study subjects were boys. The average time period between sustaining a fracture and surgical procedure was  $1.35 \pm 0.48$  days. The final results of this treatment modality were graded based on Flynn's criteria and about 94.28% of study subjects had excellent to good outcomes. One child had complication of superficial pin tract infection.

**Conclusion:** Displaced supracondylar fractures of humerus can be effectively managed with closed reduction and percutaneous criss-cross K-wire fixation. This procedure does not disturb the normal fracture healing process.

This is an Open Access (OA) journal, and articles are distributed under the terms of the [Creative Commons Attribution-NonCommercial-ShareAlike 4.0 License](https://creativecommons.org/licenses/by-nc-sa/4.0/), which allows others to remix, tweak, and build upon the work non-commercially, as long as appropriate credit is given and the new creations are licensed under the identical terms.

For reprints contact: [reprint@ipinnovative.com](mailto:reprint@ipinnovative.com)

## 1. Introduction

In children, majority of fractures around elbow are supracondylar fractures of humerus contributing 50-70% of all fractures around the elbow.<sup>1</sup> These fractures make about 3% of all fractures seen in children.<sup>2</sup> The frequency of these fractures gradually increases with age and maximum number of fractures are seen between 5 to 7 years.<sup>3</sup> These fractures occur due to child falling with an outstretched hand and are among the common fractures seen in children.<sup>4-6</sup>

These fractures need to be reduced properly to avoid occurrence of malunion.

The challenge is in the management of supracondylar fracture of humerus with displacement in these children.<sup>7</sup> Any pitfall in the treatment of these fracture leads to trouble to the treating doctor.<sup>2</sup> These fractures need appropriate care to prevent the complications like stiffness of elbow, sloughing of skin, Volkmann's Ischemia and myositis ossificans. Traction and closed reduction with Plaster of Paris splinting, which was being used in old days leads to loss of fracture reduction and elbow stiffness.<sup>8</sup>

\* Corresponding author.

E-mail address: [ranganath.drortho@gmail.com](mailto:ranganath.drortho@gmail.com) (Ranganath N).

Closed reduction and percutaneous fixation with Kirshner wires (K-wire) has shown to give good functional outcome in these fractures.<sup>9</sup> In this study, our aim was to assess the functional and radiological outcomes of these fractures managed by percutaneous pinning technique.

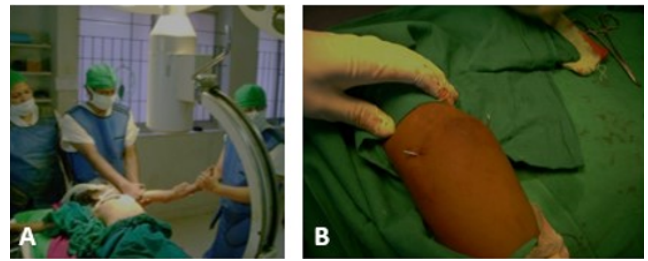
## 2. Materials and Methods

This prospective observational study was conducted from December 2017 to May 2019 in a medical college hospital. A universal sampling technique was used where all patients satisfying the inclusion criteria were included in the study. Institutional Ethical Committee clearance was taken before starting the study. Study participants were enrolled after getting informed consent from either parent of the child. Child below the age of 12 years with Gartland Type II and Type III supracondylar fracture of humerus reporting to the Emergency or Orthopaedic department within 72 hours of injury were included in this study. Gartland type I fracture, open fracture, fracture with associated vascular injury, previous or concomitant ipsilateral elbow fracture, and flexion type of supracondylar fracture were excluded from this study.

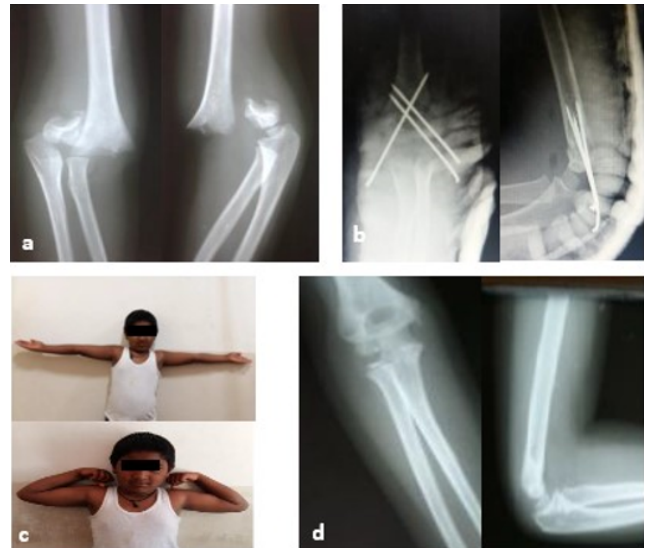The patient brought to the department of emergency medicine or orthopaedics with a history of injury to the elbow was immobilized using an arm sling and analgesics were given. After initial stabilization, the anteroposterior and lateral view radiographs were taken. The fracture was then classified according to Gartland classification.<sup>7</sup> The necessary blood investigations were done for patients who were planned for surgery on an emergency basis. Percutaneous K-wire fixation was done after closed reduction of fracture in all the study subjects.

Under general anaesthesia, the child was positioned in supine on the operating table. Closed reduction was performed under C-arm guidance. The steps for the reduction were to give longitudinal traction with elbow position in hyperextension and supination of the forearm, which was followed by application of a valgus or varus force to correct the medial or lateral displacement of distal fragment. This was followed by slow flexion of the elbow, with correction of posterior displacement of the distal fragment. The accuracy of reduction was confirmed by the anteroposterior view and oblique views under image intensifier. The reduction was considered as satisfactory if, the medial and lateral pillar continuity was achieved on oblique views and the anterior humeral line was crossing the capitulum on lateral view. After achieving satisfactory reduction, the fracture was fixed in same position percutaneously with 2 or 3 K-wires in criss cross manner (Figure 1).

In fractures with posteromedial displacement of distal fragment, medial pin was inserted first followed by the lateral pin. The entry of the medial pin was from the center point of the medial epicondyle in anteroposterior and lateral



**Fig. 1:** Reduction of fracture with fluoroscopy guidance (A) and percutaneous K-wire fixation under General anesthesia (B).



**Fig. 2:** Anteroposterior and Lateral view of Supracondylar fracture Humerus left side (a) with percutaneous K-wire fixation (b), elbow range of movements (c), and radiological union of the fracture (d).

views of image intensifier. The lateral pin was inserted through the center of the lateral epicondyle. The K-wires used were of 1.2 mm to 2.0 mm diameter. The pins were inserted at an angle of 30 degrees obliquity to the long axis of the humerus in coronal plane. After pin insertion, stability of the fixation was confirmed under image intensifier with flexion and extension of the elbow joint and also valgus and varus forces. The pins were cut after bending and the bent part was kept outside the skin for easy removal at 6 weeks. The involved limb was supported by well-padded posterior POP slab with elbow in neutral position before shifting the child to the ward. The operated limb was kept elevated and active finger mobilisation was encouraged. Postoperatively, intravenous antibiotics were given for three days along with analgesics and other supportive treatment. Radiograph of the operated elbow was taken on the next day to see the fracture fragment alignment. Patients were advised to come for regular follow up and were discharged on third day. Parents of children were explained about the care of the POP slab, the importance of active finger movements, and

keeping limb elevated.

Postoperative POP slab support was continued for 3 weeks. The K-wires were removed at 3 weeks and active elbow movements were started (Figure 2). Patients and their parents were advised to continue exercises at home and to come for follow up at 6 weeks, 3 months and 6 months. Maintenance of reduction was confirmed on follow-up X-ray by measuring Baumann's (humerocapitellar) angle and comparing it with the perioperative calculated value. In normal individuals the Baumann's angle range from 64 degrees to 81 degrees.<sup>10</sup> Carrying angle and range of motion of operated elbow was measured clinically with a goniometer and compared with the uninvolved elbow. A detailed clinical examination was done at the final follow up to assess the functional outcome according to the Flynn's criteria (Table 1).<sup>11</sup> The results were analysed by Descriptive statistical analysis. The continuous measurements are presented as Mean  $\pm$  Standard Deviation and results on categorical measurements as percentages. The Chi-square test was used to test significance and a P-value of  $<0.05$  was taken as statistically significant.

**Table 1:** Flynn's criteria for grading of functional outcome in supracondylar fractures of the humerus

Result	Rating	Cosmetic factor (carrying angle loss) (degrees)	Functional factor (motion loss) (degrees)
Satisfactory	Excellent	0–5	0–5
	Good	5–10	5–10
	Fair	10–15	10–15
Unsatisfactory	Poor	Over 15	Over 15

### 3. Results

In this study, 35 children with fracture of the humerus in supracondylar region were included. All the fractures were managed by closed reduction and percutaneous K-wire fixation. About half of the study population were in the range of 6 to 8 years. Majority of study subjects were boys. Other demographic data was given in Table 2.

The cases that underwent surgery for supracondylar fracture of the humerus were not older than 72 hours and surgery was performed at the earliest possible time after admission to the hospital. The average time period between sustaining a fracture and surgical procedure was  $1.35 \pm 0.48$  days. More than half of patients (57.14%) stayed in the hospital for 4 days and remaining (42.85%) for 3 days (Table 3). All the fractures were united at 3 weeks, which was confirmed before K-wire removal. At 3 months after surgery, the Baumann's angle of injured elbow in 85.7% of children was within normal range. The values of Baumann's angle in postoperative and at 3 months interval, X-Rays were compared and was statistically not significant

(Table 4).

**Table 2:** Demographic data of the study subjects.

Variables	Number (percent) (n=35)
Mean Age $\pm$ SD	$7.91 \pm 2.22$ years
<b>Sex of the patients</b>	
Male	24 (68.57%)
Female	11 (31.42%)
<b>Side affected</b>	
Right side	10 (28.57%)
Left side	25 (71.42%)
<b>Mode of injury</b>	
Fall while Playing	18 (51.42%)
Fall from Bicycle	11 (31.42%)
Fall from Tree/Steps	06 (17.14%)
<b>Fracture type (Gartland Type)</b>	
Type 2	10 (28.57%)
Type 3A (Posteromedial)	15 (42.85%)
Type 3B (Posterolateral)	10 (28.57%)

**Table 3:** Time to surgery and hospital stay of the patients

Variables	Mean & SD (n=35)
Mean duration from injury to surgery	$1.35 \pm 0.48$ Day
Mean duration of stay in the hospital	$3.57 \pm 0.5$ Day
Mean Baumann's angle at 3 months	$74.94 \pm 4.37$ degrees

**Table 4:** Mean Baumann's angle up to 3 months.

S.No.	Time of measurement	Mean	Standard deviation	P value
1	Immediate postoperative period	74.88	3.91	0.9245
2	At 3 weeks	75.4	3.54	
3	At 6 weeks	75.31	3.66	
4	At 3 months	74.94	4.37	

The final results of this treatment modality were graded based on Flynn's criteria and about 94.28% of study subjects had excellent to good outcomes (Table 5). One child had complication of superficial pin tract infection which was managed with regular dressing. Another child had K-wire migration which was reinserted in the appropriate direction. Among two children who had a poor outcome, one had cubitus varus deformity and another had elbow stiffness

**Table 5:** Final outcome based on Flynn's grading

Results	Outcome	No. of patients	Percentage
Satisfactory	Excellent	28	80 %
	Good	5	14.28 %
Unsatisfactory	Poor	2	5.71 %

#### 4. Discussion

The Supracondylar fracture of the humerus is most commonly seen in children due to fall with an outstretched hand.<sup>12</sup> The most commonly used treatment modality in this fracture is closed reduction and percutaneous K-wire fixation. The maintenance of reduction in these fractures pose a challenge to treating surgeon. Poor prognosis is seen in children who report to hospital after 24 hours of the injury.<sup>13</sup> Most of the children in this study were below 8 years (72.85%). The mean age of the study participants was 7.9 years which matches with other studies in the literature.<sup>14–17</sup> This fracture was predominantly seen in boys in this study and this has been reported in the literature.<sup>14,16–19</sup> Previous studies have reported that the common mode of injury was a fall while playing, which was also found in this study.<sup>16,19,20</sup> Involvement of left upper limb was seen more commonly than right in literature and in this study.<sup>16,17,19,21</sup>

Literature says that, the traction application is also an effective method in the treatment of these fractures but has got many drawbacks and it also increases the duration of hospital stay.<sup>22</sup> Use of either skin or skeletal traction for the treatment of supracondylar fracture of humerus is seen to increase the hospital stay of the patient.<sup>14</sup> Open reduction and internal fixation in these fractures is recommended when it is an open fracture, with a vascular injury requiring exploration or difficulty in reduction.<sup>14</sup> Hence in recent times, closed reduction and percutaneous pin fixation has gained popularity for the treatment of displaced closed supracondylar fractures without associated neurovascular injury.

In this study, the average delay from injury to the surgery was 2.65 days. Other studies have reported the time delay from 1.3 to 2 days.<sup>19,23,24</sup> The increased delay between fracture and surgery in our study was due to delayed presentation to the hospital, as most cases were referred from the rural health centres. About half of the patients stayed in hospital for three days and another half for four days. The short duration of hospital stay helps in returning of child's parents to their home and earn for the family. This was especially important for lower-income group families. The patient's families were happy to go home early with an advice about the care of the POP slab, limb elevation, and active finger movements.

The purpose of treating any fracture is to get fracture union in anatomical position without any associated complications. Closed reduction and percutaneous K-wire fixation is being used more commonly in the treatment of displaced (Gartland Type II and Gartland Type III) supracondylar fractures of humerus. In literature, majority of studies have used two crossed K-wires inserted from the medial and lateral aspect of the elbow.<sup>11,25,26</sup> Use of only laterally inserted pins without any medial pin has also

been reported in some studies.<sup>27</sup> Biomechanically, a crossed pin configuration provides increased stability but studies have shown a increased risk of iatrogenic ulnar nerve injury during the insertion of the medial pin.<sup>23,28,29</sup> Treatment of these fractures with only lateral pin however avoids the iatrogenic injury to the Ulnar nerve but, at the cost of decreased stability of the fracture fixation.<sup>30–34</sup>

Pin tract infection rate ranges from no pin tract infection to 5.8% in the previous studies.<sup>11,20,35</sup> In this study 1 patient (2.85%, n=35) had a pin tract infection that responded to the oral antibiotics. Studies have shown the loss of elbow range of movements between zero to five degrees, which was 4.49 degrees in this study. One patient had cubitus varus deformity with no major functional disability. One more child with stiffness of the elbow was put on active assisted physiotherapy and gradually got the functional range of movements.

Loss of carrying angle in these fractures after treatment has been reported in the literature. In our study, loss of the carrying angle (zero to five degrees) of the affected extremity was noted in 25 (71.42%) patients. Other studies in the past have shown variable percentages of loss in carrying angle ranging from 82.9% to 91.75%.<sup>19,20,35</sup> Our study showed that, about 85.72 % fractures had Baumann's angle in the normal range at the final follow up as compared to other study which reported normal Baumann's angle in 66% of the fractures.<sup>36</sup> Functional results based on Flynn's grading system showed that 94.28% (n=35) children had satisfactory results. Our study findings are in comparison with other studies which reported excellent to good results from 74.02 % to 94%.<sup>11,15,35</sup>

The results of our study are comparable with other study results reported in the literature. Closed reduction with pinning aids in early discharge of patient. The limitations of this study is that there was no comparison group. Further studies with larger sample and long term follow up are required to see the long-term functional outcome of the affected limb.

#### 5. Conclusion

Displaced supracondylar fractures of humerus can be effectively managed with closed reduction and percutaneous criss-cross K-wire fixation. This procedure does not disturb the normal fracture healing process and gives satisfactory functional outcome with reduced complications.

#### 6. Source of Funding

None.

#### 7. Conflict of Interest

None.

## References

- Herring JA. Fracture about the elbow. In: Tachdjian's Pediatric Orthopaedics. vol. 3. Philadelphia: W.B. Saunders; 2002. p. 2139–221.
- Aronson DD, Prager BI. Supracondylar fractures of the humerus in children. A modified technique for closed pinning. *Clin Orthop Relat Res.* 1987;219:174–84.
- Kasser JR, Beaty JH. Supracondylar fractures of the distal humerus. In: Rockwood and Wilkins Fractures in children. vol. 3. Philadelphia: Lippincott Williams and Wilkins; 2001. p. 577–620.
- Cheng JC, Shen WY. Limb fracture pattern in different pediatric age groups: a study of 3,350 children. *J Orthop Trauma.* 1993;7(1):15–22.
- Wilkins KE. Fractures and Dislocation of the Elbow Region. In: Wilkins K, King R, editors. Fractures in Children. vol. 3. Philadelphia: JB Lippincott Company; 1991. p. 509.
- Skaggs D, Pershad J. Pediatric elbow trauma. *Paediatr Emerg Care.* 1997;13(6):425–34.
- Gartland JJ. Management of supracondylar fractures in children. *Surg Gynecol Obstet.* 1959;109(2):145–54.
- Canale TS. Fractures and Dislocations in Children. In: Campbell's operative orthopaedics. vol. 3. New York: Mosby; p. 2407–22.
- Vaquero-Picado A, Gonzales-Moran G, Moraleda L. Management of supracondylar fractures of humerus in children. *EFORT Open Rev.* 2018;3(10):526–40. doi:10.1302/2058-5241.3.170049.
- Williamson DM, Coates CJ, Miller RK, Cole WG. Normal characteristics of the Baumann (humerocapitellar) angle: an aid in assessment of supracondylar fractures. *J Pediatr Orthop.* 1992;12(5):636–9.
- Flynn JC, Matthews JG, Benoit RL. Blind pinning of displaced supracondylar fractures of the humerus in children. *J Bone Joint Surg Am.* 1974;56(2):263–72.
- Cheng JC, Lam TP, Shen WY. Closed reduction and percutaneous pinning for type III displaced supracondylar fractures of the humerus in children. *J Orthop Trauma.* 1995;9(6):511–5.
- Ating'a JE. Conservative management of supracondylar fractures of the humerus in Eastern Provincial General Hospital, Machakos. *East Afr Med J.* 1984;61(7):557–60.
- Pirone AM. Management of displaced extension- type supracondylar fractures of the humerus in children. *J Bone Joint Surg Am.* 1988;70(5):641–50.
- Farnsworth CL, Silva PD, Mubarak SJ. Etiology of supracondylar humerus fractures. *J Pediatr Orthop.* 1998;18(1):38–45.
- Gopinath P, Singh S, Ravoo A. Study of percutaneous K wire fixation in supracondylar fracture of humerus in children. *Int J Res Orthop.* 2019;5(3):427–31.
- Narayana LS, Naik LT, Kumar VR, Kumar MA. Closed reduction and internal fixation with Kirschner wires for supracondylar fracture humerus in children. *Asian Pac J Health Sci.* 2016;3(3):95–100.
- Wilkins KE. The operative management of supracondylar fracture. *Orthop Clin North Am.* 1990;21(2):269–89.
- Gowda PM, Mohammed N. A study of supracondylar fractures of humerus in children by reduction and fixation with Kirschner wires. *Int J Clin Pract.* 2014;5(6):572–76.
- Sahu RL. Percutaneous lateral Kirschner wire fixation in pediatric supracondylar fractures of humerus. *J Orthop Traumatol Rehabil.* 2013;6(1):78–83.
- Sharma A, Walia J, Brar BS, Sethi S. Early results of displaced supracondylar fractures of humerus in children treated by closed reduction and percutaneous pinning. *Indian J Orthop.* 2015;49(5):529–35.
- Sutton WR, Georgopoulos G, Jr TD. Displaced supracondylar humeral fractures in children - A comparison of results and costs in patients treated by skeletal traction versus percutaneous pinning. *Clin Orthop Relat Res.* 1992;(278):81–7.
- Skaggs DL, Hale JM, Bassett J, Kaminsky C, Kay RM, Tolo VT, et al. Operative treatment of supracondylar fractures of the humerus in children. The consequences of pin placement. *J Bone Joint Surg Am.* 2001;85(5):735–40.
- Nacht JL, Ecker ML, Chung SM, Lotke PA, Das M. Supracondylar fractures of the humerus in children treated by closed reduction and percutaneous pinning. *Clin Orthop Relat Res.* 1983;(177):203–9.
- Swenson AL. The treatment of supracondylar fractures of the humerus by Kirschner-wire transfixion. *J Bone Joint Surg Am.* 1948;30A(4):993–7.
- Casiano E. Reduction and fixation by pinning “banderillero” style-fractures of the humerus at the elbow in children. *Mil Med.* 1960;125:262–4.
- Ariño VL, Lluch EE, Ramirez AM, Ferrer J, Rodriguez L, Baixauli F, et al. Percutaneous fixation of supracondylar fractures of the humerus in children. *J Bone Joint Surg Am.* 1977;59(7):914–6.
- Lyons JP, Ashley E, Hoffer MM. Ulnar nerve palsies after percutaneous cross-pinning of supracondylar fractures in children's elbows. *J Pediatr Orthop.* 1998;18(1):43–5.
- Rasool MN. Ulnar nerve injury after K-wire fixation of supracondylar humerus fractures in children. *J Pediatr Orthop.* 1998;18(5):686–90. doi:10.1097/00004694-199809000-00027.
- Gordon JE, Patton CM, Luhmann SJ, Bassett GS, Schoenecker PL. Fracture stability after pinning of displaced supracondylar distal humerus fractures in children. *J Pediatr Orthop.* 2001;21(3):313–8.
- Lee SS, Mahar AT, Miesen D, Newton PO. Displaced pediatric supracondylar humerus fractures: Biomechanical analysis of percutaneous pinning techniques. *J Pediatr Orthop.* 2002;22(4):440–3.
- Zionts LE, McKellop HA, Hathaway R. Torsional strength of pin configurations used to fix supracondylar fractures of the humerus in children. *J Bone Joint Surg Am.* 1994;76(2):253–6. doi:10.2106/00004623-199402000-00013.
- Kallio PE, Foster BK, Paterson DC. Difficult supracondylar elbow fractures in children: Analysis of percutaneous pinning technique. *J Pediatr Orthop.* 1992;12(1):11–5.
- Davis RT, Gorczyca JT, Pugh K. Supracondylar humerus fractures in children. Comparison of operative treatment methods. *Clin Orthop Relat Res.* 2000;(376):49–55.
- Sakthivel RN, Balakrishnan V, Vadivelu G. Analysis of supracondylar fractures in children treated with closed reduction and percutaneous pinning. *Int J Res Med Sci.* 2016;4(5):1590–96.
- Tuomilehto N, Kivisaari R, Sommarhem A, Nietosvaara AY. Outcome after pin fixation of supracondylar humerus fractures in children: postoperative radiographic examinations are unnecessary. *Acta Orthop.* 2017;88(1):109–15. doi:10.1080/17453674.2016.1250058.

## Author biography

**Deelipkumar Choudhary**, Assistant Professor

**Shivanand C Mayi**, Associate Professor

**Ranganath N**, Professor

**Cite this article:** Choudhary D, Mayi SC, Ranganath N. Assessment of functional and radiological outcomes of closed reduction and K-wire fixation of supracondylar fracture of humerus in children. *Panacea J Med Sci* 2023;13(1):98–102.