

Content available at: <https://www.ipinnovative.com/open-access-journals>

Indian Journal of Clinical and Experimental Ophthalmology

Journal homepage: [www.ijceo.org](http://www.ijceo.org)

## Original Research Article

## Clinical study of intravitreal injection of expansile gases in treatment of vitreomacular traction

Jignesh Y Gosai<sup>1</sup>, Amruta V More<sup>2</sup>, Urmish V Goswami<sup>1</sup>, Sarjak M Shah<sup>1,\*</sup>, Soema S Tebhla<sup>1</sup><sup>1</sup>Dept. of Ophthalmology, M & J Western Regional Institute of Ophthalmology, Government Eye Hospital, Ahmedabad, Gujarat, India<sup>2</sup>L V Prasad Eye Institute, Bhubaneswar, Odisha, India

## ARTICLE INFO

## Article history:

Received 09-05-2022

Accepted 28-06-2022

Available online 06-10-2022

## Keywords:

Vitreomacular traction syndrome

Posterior vitreous detachment

Intravitreal gases

Macula

Retina

## ABSTRACT

**Introduction:** VMT is a condition with an abnormal adhesion of vitreous to the macula. In classic form it is separated from the retina throughout the peripheral fundus but remains adherent posteriorly. We studied the efficacy of intravitreal expansile gas injection with proper patient positioning for relieving VMT, using OCT as main modality to image response.

**Aim:** To study the efficacy of intravitreal injection of expansile gases (SF<sub>6</sub> or C<sub>3</sub>F<sub>8</sub>) in releasing VMT and the improvement in the visual acuity.

**Materials and Methods:** The study was conducted in a tertiary eye care centre during the period of October '14 to '16. 37 eyes of 30 patients were included.

**Results:** Those with HVMA of <750 μm had a 100% success rate, those with HVMA >750 μm had a 26.66% failure rate of non-resolution. The 33 eyes (P= 0.026) which were relieved of the traction provided a significant relevance of this treatment method in case of symptomatic VMT. Eyes treated with expansile gas injection and resolution of VMT showed non-significant improvement after one week of injection (P = 0.089), but did show significant improvement after one and three months (P<0.01).

**Conclusion:** For patients unable to undergo long surgeries like PPV with ILM peeling, this modality of intravitreal expansile gas injection serves to relieve the traction easily and reduces any sort of visual distortion.

This is an Open Access (OA) journal, and articles are distributed under the terms of the [Creative Commons Attribution-NonCommercial-ShareAlike 4.0 License](https://creativecommons.org/licenses/by-nc-sa/4.0/), which allows others to remix, tweak, and build upon the work non-commercially, as long as appropriate credit is given and the new creations are licensed under the identical terms.

For reprints contact: [reprint@ipinnovative.com](mailto:reprint@ipinnovative.com)

## 1. Introduction

In 1967, Jaffe described 'vitreoretinal traction syndrome' as a distinct entity. The condition he described mostly affected phakic patients, lacked multicystic macular lesions and fluorescein leakage, and demonstrated vitreoretinal adherence.<sup>1</sup>

In 1970, Reese et al described an unusual macular condition in which an incomplete posterior vitreous detachment (PVD) exerted traction on the macula and

was accompanied by decreased visual acuity (VA).<sup>2</sup> Histopathologic studies by him confirmed 'vitreomacular traction syndrome' and showed partially detached posterior hyaloid with persistent attachment to the internal limiting membrane in the foveal region.<sup>3</sup> Hence, the term vitreomacular traction (VMT) syndrome was coined. In late 1960's detailed study of the vitreous attachments to the retinal structures was done and the term "Vitreomacular traction" was coined.

In Vitreomacular traction, the vitreous gel has an abnormally strong adhesion to the macula and over time, the gel tends to pull forward and can cause retinal distortion,

\* Corresponding author.

E-mail address: [sarjakmshah@gmail.com](mailto:sarjakmshah@gmail.com) (S. M. Shah).

retinal swelling and decreased vision. It is an offshoot of the normal aging process in the eye called posterior vitreous detachment. In the classic form of VMT syndrome, as initially described, the vitreous is separated from the retina throughout the peripheral fundus but remains adherent posteriorly, endangering anteroposterior traction on a broad, dumbbell-shaped region over the macula and optic nerve.<sup>4</sup> OCT has provided new insight into the understanding of VMT syndrome by providing better evaluation of tractional forces at the vitreoretinal interface, as well as comprehending its relationship with particular macular conditions.

Nowadays, VMT is believed to be associated with a broad spectrum of maculopathies, including cystoid macular edema (CME), epiretinal membrane (ERM), and macular hole (MH) formation, all may be attributed to a common aetiology.<sup>5</sup>

The pathogenesis of these disorders is not completely understood, OCT has implicated tractional forces as a plausible cause. Vitreomacular traction (VMT) syndrome leading to macular traction, which can cause decreased visual acuity, metamorphopsia, photopsia and central scotomas necessitating treatment, which impact an individual's quality of life.<sup>6</sup>

The treatment for symptomatic vitreomacular traction includes 23G/25G Pars Plana Vitrectomy with peeling of the Internal Limiting membrane, Pharmacological vitreolysis and the experimental treatment by intravitreal injection of expansile gas.

In this study we monitored the efficacy of intravitreal expansile gas injection in relieving the vitreomacular traction with positioning the patient and using OCT as our main imaging modality.

## 2. Aims and Objectives

1. To study the efficacy of intravitreal injection of expansile gases (SF<sub>6</sub> or C<sub>3</sub>F<sub>8</sub>) in releasing vitreomacular traction with proper position.
2. To study improvement in the visual acuity after releasing vitreomacular traction.

## 3. Materials and Methods

The study was carried out in a tertiary eye care centre during the period of October 2014 to October 2016. During this period 37 eyes of 30 patients were included in the study with proper informed consent as per the inclusion and exclusion criteria. The study was conducted in accordance with the tenets of the Declaration of Helsinki and was approved by the Institutional Review Board and Ethics Committee. A detailed history of each patient was taken and findings were recorded including visual acuity (Snellen's chart), fundus examination using 90D double aspheric lens and Optical Coherence Tomography (Topcon 3D OCT 2000) done for

all patients.

### 3.1. Inclusion criteria

All the patient more than 18 years of age providing written consent and with willingness to come for follow up were included in this study.

Phakic/Pseudophakic patients with adequate pupillary dilatation. (8mm) with visible vitreous attachment within 1500um radius of foveal center on causing anteroposterior vitreofoveal traction near or within the macula and minimum visual acuity of 1/60 on Snellen's chart (counting fingers at 1m) were selected for the study.

### 3.2. Exclusion criteria

All the patients less than 18 years, one eyed, unable to visit for follow up, who partake air travel and with other history of ocular disease and trauma were excluded from the study.

### 3.3. Clinical examination

Following points were included in ophthalmic examination

1. Best corrected visual acuity on Snellen's chart
2. Intraocular pressure
3. Anterior segment evaluation
4. Dilated posterior segment evaluation using Direct & Indirect ophthalmoscope, followed by slit lamp biomicroscopy with +90D double aspheric lens.

After clinical examination and clinical diagnosis patients further underwent optical coherence tomography. Patients diagnosed on the basis of OCT were posted for intravitreal injection and underwent systemic investigations like random blood sugar and HbA1c levels. Patients were the given 0.3ml 100% intravitreal injection of SF<sub>6</sub> or C<sub>3</sub>F<sub>8</sub> with 30G needle 3.5 to 4mm away from limbus under topical anaesthesia and explained to maintain face down position or prone position for most of the waking hours for 1-2days. They were given antibiotic eye drops (7 days) and anti-inflammatory eye drops for one month. Intraocular pressure was measured, and BCVA monitored. Follow up OCTs were performed at one week, one month and three months follow up visits with ophthalmology parameters monitored on those follow ups.

## 4. Results

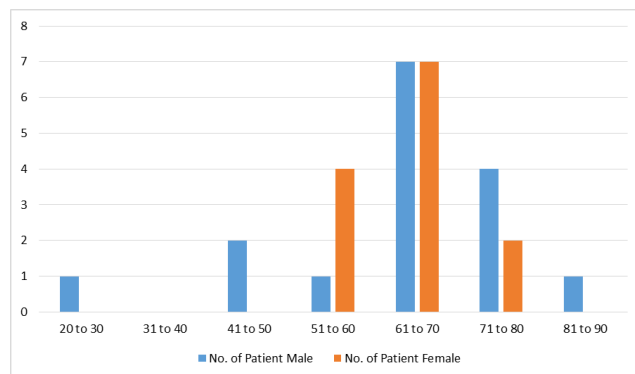
37 eyes of 30 patients were studied and the following results were obtained.

### 4.1. Age wise distribution

The age of patients in our study was between 21-90 years (median 65) and inter-quartile range (IQR 25-75) 58years-70.5years.(Figure 1)

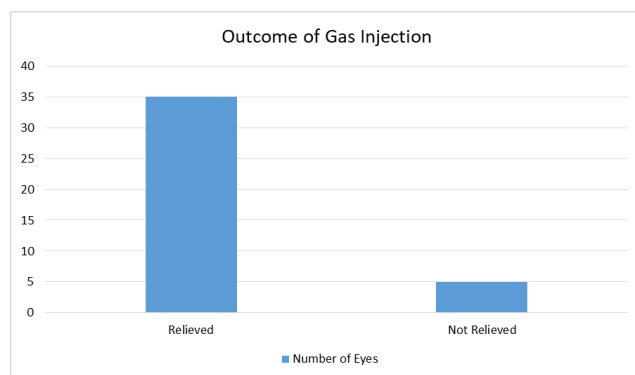
**Table 1:** Age wise distribution of the patients

| Age (Years) | Number of Patients |        |
|-------------|--------------------|--------|
|             | Male               | Female |
| 21 to 30    | 1                  | 0      |
| 31 to 40    | 0                  | 0      |
| 41 to 50    | 2                  | 0      |
| 51 to 60    | 1                  | 4      |
| 61 to 70    | 7                  | 7      |
| 71 to 80    | 4                  | 2      |
| 81 to 90    | 1                  | 0      |

**Fig. 1:** Age wise distribution of study participants

#### 4.2. Sex ratio

14 females (47% and 16 males (53% patients out of 30. (Figure 2)

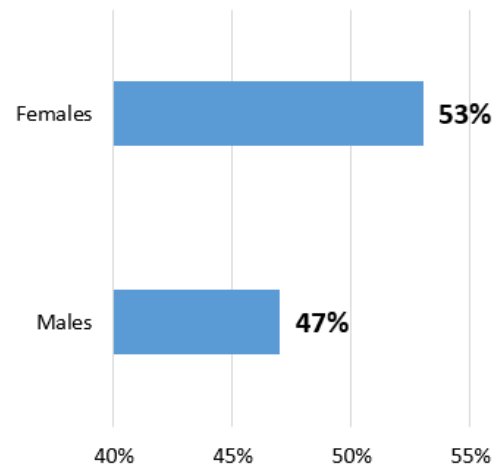
**Fig. 2:** Outcome of gas injection in VMT relief

#### 4.3. Gas injection

37 eyes of 30 patients underwent 0.3ml of 100% SF<sub>6</sub> OR C<sub>3</sub>F<sub>8</sub> intravitreal injection and 33 eyes (89.18%) were relieved of vitreomacular traction. (Figure 3)

#### 4.4. Horizontal vitreomacular adhesion

37 eyes of 30 patients with horizontal vitreomacular adhesion (HVMA) </>750 μm were compared regarding

**Fig. 3:** Sex distribution of participants

relief of the vitreomacular traction or not in a 2 × 2 table with the following results.

**Table 2:** Results after gas injection in eyes with horizontal vitreomacular adhesions

|             | VMT Relieved | VMT Not Relieved |
|-------------|--------------|------------------|
| HVMA >750um | 11 (73.33%)  | 4 (26.67%)       |
| HVMA <750um | 22 (100%)    | 0 (0%)           |

After calculation with Mid-P Exact, 95% confidence interval the P value is 0.02067.

P value is significant at 0.05 significance level (P<0.05) and the treatment option of intravitreal injection of SF<sub>6</sub> or C<sub>3</sub>F<sub>8</sub> in case of vitreomacular traction is an effective method.

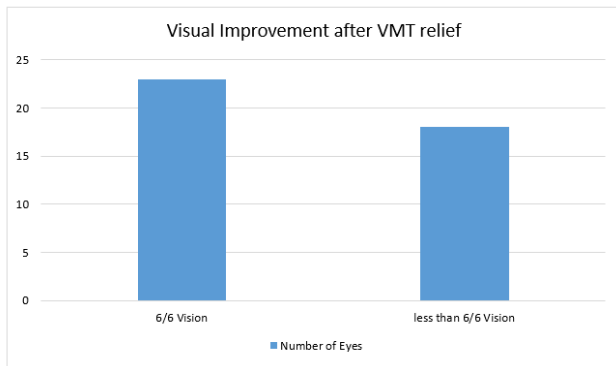
#### 4.5. Patients regaining 6/6 visual acuity

Out of 37 eyes of 30 patients, 21 eyes of 37 eyes (56.76%) gained 6/6 vision recorded on Snellen's chart and 16 eyes (43.24%) did not gain 6/6 vision at three months.

After running a Wilcoxon-signed rank test the results were,

1. There was no significant change in the visual acuity at seven days post treatment (P = 0.089).
2. There was significant change in visual acuity at 1month post treatment (P<0.01) with improvement in vision in 34 eyes out of 37 eyes.
3. There was significant change in visual acuity at 3 months post treatment (P<0.01) with improvement in vision in 36 eyes out of 37. (Figure 4)

Intraocular pressure changes were monitored after the intravitreal injection of 0.3ml 100% gas SF<sub>6</sub> or C<sub>3</sub>F<sub>8</sub> which



**Fig. 4:** Visual improvement after VMT relief in participants

showed no significant change in IOP at seven days post gas injection ( $P=0.354$ ), at 1 month post gas injection ( $P=0.722$ ) and at 3 months post gas injection ( $P=0.877$ ).

Seven patients (fourteen eyes) out of thirty patients had bilateral vitreomacular traction. These patients received intravitreal injection of 0.3ml 100% gas SF<sub>6</sub> or C<sub>3</sub>F<sub>8</sub> were relieved of the traction in the injected eye. During this period the other diseased eye did not undergo spontaneous resolution of the traction. Patients were hence injected 0.3ml 100% gas SF<sub>6</sub> or C<sub>3</sub>F<sub>8</sub> in the other eye too.

All the patients with bilateral vitreomacular traction, after gas injection underwent resolution and had significant improvement in vision, as stated above.

Patients who maintained prone or face down position after 0.3ml 100% gas SF<sub>6</sub> or C<sub>3</sub>F<sub>8</sub> were relieved of the traction earlier.

## 5. Discussion

Ian A. Rodrigues et al<sup>7</sup> studied 15 eyes of 14 patients with intravitreal gas injection in cases of vitreomacular traction and studied the effect of PVD induction after a month. The patients who had a horizontal vitreomacular adhesion of <750 μm had a 75% success rate ( $P = 0.018$ ) at the end of six months of being relieved of the vitreomacular traction.

Pre-treatment maximum central foveal thickness was significantly less following successful release of vitreomacular traction within six months compared to the eyes without vitreomacular traction release.

In our study 37 eyes of 30 patients underwent gas injection.

The patients who had (HVMA) horizontal vitreomacular adhesion of <750 μm had a 100% success rate in relieving vitreomacular traction whilst those with HVMA >750 μm had a 26.66% failure rate of non-resolution of the vitreomacular traction. The 33 eyes ( $P= 0.026$ ) which were relieved of the traction provided a significant value about the relevance of this treatment method in case of symptomatic vitreomacular traction.

Of the eyes which underwent treatment and the vitreomacular traction had resolved within 3 months achieved a normal foveal contour with normal central foveal thickness.

Shelly Day et al<sup>8</sup> in a recent study found that all of the eyes that had release of VMT had vitreoretinal adhesion of less than 521 μm, and none had ERMs. None of the patients with release of VMT had an ERM, compared with 50% of those who did not have release of VMT ( $P = 0.09$ ). Four of the patients also had VMT in the contralateral eye, and none of them developed release of the VMT in the contralateral eye during this period. No other ocular complications were noted, and none required intraocular pressure lowering medications or cataract surgery during this period.

In our study two eyes had vitreomacular traction with an epiretinal membrane of which both eyes did not undergo resolution of vitreomacular traction after intravitreal injection of SF<sub>6</sub> or C<sub>3</sub>F<sub>8</sub>.

Seven patients (14 eyes) had coexisting vitreomacular traction in the contralateral eye which did not undergo spontaneous resolution in the period of study of the first eye and was subjected to the same treatment option of gas injection three months after the injection in the first eye. All of the 14 eyes were relieved of the vitreomacular traction.

The patients characteristically affected with visually symptomatic vitreomacular traction were in the broad age group of 51 years to 80 years and maximally concentrated in the 61 years to 70 years group.

Eyes which underwent resolution of the traction and showed decrease in the central foveal thickness during the follow up, showed drastic vision improvement with 56.76% patients gaining 6/6 vision on the Snellen's chart without any distortion of image formed and 43.24% patients having vision better than before and could read a minimum of 6/60 on the Snellen's chart. The patients not achieving 6/6 vision had remaining intraretinal fluid at the fovea or had a part of the foveal tissue which avulsed during the treatment. The overall progress rate of the patients in regard to vision had a significant change after one month ( $P<0.01$ ) and even better after three months ( $P<0.01$ ) with lesser distortion as the intraretinal fluid resolved. The vision improved for a few patients as early as seven days post gas injection but was statistically not significant ( $P=0.089$ ).

Melberg et al,<sup>9</sup> in the study of conducting pars plana vitrectomy in nine eyes of nine patients of vitreomacular traction found that seven eyes i.e. 78% reattachment of macula was found. Visual acuity was improved in four eyes and was stable in four eyes and worsened in one eye. The visual improvement was limited by chronic macular detachment, pre-macular fibrosis, cystoid macular edema, or macular schisis. He also noted that the vision was later compromised by complications of vitrectomy surgery like intraoperative haemorrhage, post operatively

high intraocular pressure, cataract.

In our study 33 eyes of 37 eyes were relieved of vitreomacular traction within 3 months with a gain of good vision. The study did not see any adverse events like acute cataract, macular hole formation, haemorrhage, high intraocular pressure rise, retinal tear or detachment. Part of the foveal tissue did avulse in two eyes but was not statistically significant.

In our study 37 eyes of 30 patients were injected with intravitreal gas injection of undiluted 0.3 ml of C<sub>3</sub>F<sub>8</sub> or SF<sub>6</sub> gas. Out of which 4 eyes weren't resolved of the traction. Out of these four, two eyes had epiretinal membrane. Patients with epiretinal membrane related vitreomacular traction had lesser chance of resolution with this modality of treatment and may have a better chance with enzymatic vitreolysis or pars plana vitrectomy with internal limiting membrane peeling as specified in Stalman et al. study.

Our treatment modality has been able to treat traction at the macula but has not been tried to close macular hole. In this study patients with impending macular hole were enrolled and 50% patients (1 out of 2) were relieved of the traction and saved from progression into a macular hole. Further study with a larger sample size is warranted to check the efficacy in this regard.

Chan said,<sup>10</sup> “We theorize that the gas bubble may destabilize the vitreous integrity by accentuating liquefaction, and the cortical vitreous collapses during the absorption phase of the bubble, leading to PVD. Perhaps the long-acting bubble serves as a cushion and a more gentle PVD.”

During our study the patients who maintained face down or prone positions were seen to be benefitted earlier than who did not maintain or were unable to maintain face down or prone position. It was subjectively observed that maintaining position had an added advantage to the treatment of faster resolution of the traction and early visual recovery as early as 7<sup>th</sup> day of injection, there was induction of complete PVD. The other demographic details did not bring about any significance in the treatment outcome.

## 6. Conclusion

Our study establishes the successful role of intravitreal expansile gases (SF<sub>6</sub> and C<sub>3</sub>F<sub>8</sub>) in the treatment of VMT as highly efficient and novel alternative. Intraocular gas injection alone in the office setting followed by limited face-down positioning appears to be a viable novel alternative for treatment of symptomatic VMT.

There was significant improvement in the post treatment visual acuity of the patients at the end of 3 months.

It is a convenient and effective OPD procedure that should be adapted in retina clinic routinely.

## 7. Abbreviations

VMT vitreomacular traction, HVMA horizontal vitreomacular adhesion, PVD posterior vitreous

detachment, PPV pars plana vitrectomy, OCT optical coherence tomography, ERM epiretinal membrane, CME cystoid macular edema, MH macular hole.

## 8. Source of Funding

None.

## 9. Conflict of Interest

Nil.

## References

1. Jaffe NS. Vitreous traction at the posterior pole of the fundus due to alterations in the vitreous posterior. *Trans Am Acad Ophthalmol Otolaryngol.* 1967;71(4):642–52.
2. Reese AB, Jones IS, Cooper WC. Macular changes secondary to vitreous traction. *Am J Ophthalmol.* 1967;64(3):544–9.
3. Reese AB, Jones IS, Cooper WC. Vitreomacular traction syndrome confirmed histologically. *Am J Ophthalmol.* 1970;69(6):975–7.
4. McDonald HR, Johnson RN, Schatz H. Surgical results in the vitreomacular traction syndrome. *Ophthalmology.* 1994;101(8):1397–402.
5. Smiddy WE, Flynn HW. Pathogenesis of macular holes and therapeutic implications. *Am J Ophthalmol.* 2004;137(3):525–37.
6. Bottós JM, Elizalde J, Rodrigues EB, Maia M. Current concepts in vitreomacular traction syndrome. *Curr Opin Ophthalmol.* 2012;23(3):195–201.
7. Rodrigues IA, Stangos AN, Mchugh DA, Jackson TL. Intravitreal injection of expansile perfluoropropane (c(3)f(8)) for the treatment of vitreomacular traction. *Am J Ophthalmol.* 2012;155(2):270–6.
8. Day S, Martinez JA, Nixon PA, Levitan M, Dooner JW, Wong RW, et al. . Intravitreal sulfur hexafluoride injection for the treatment of vitreomacular traction syndrome. *Retina.* 2016;36(4):733–7.
9. Melberg NS, Williams DF, Balles MW, Jaffe GJ, Meredith TA, Sneed SR, et al. Vitrectomy for vitreomacular traction syndrome with macular detachment. *Retina.* 1995;15(3):192–7.
10. Chang LK, Fine HF, Spaide RF, Koizumi H, Grossniklaus HE. Ultrastructural correlation of spectral-domain optical coherence tomographic findings in vitreomacular traction syndrome. *Am J Ophthalmol.* 2008;146(1):121–7.

## Author biography

**Jignesh Y Gosai**, Associate Professor

**Amruta V More**, Vitreo Retina Fellow

**Urmish V Goswami**, Resident Doctor

**Sarjak M Shah**, Resident Doctor

**Soema S Tebhla**, Resident Doctor

**Cite this article:** Gosai JY, More AV, Goswami UV, Shah SM, Tebhla SS. Clinical study of intravitreal injection of expansile gases in treatment of vitreomacular traction. *Indian J Clin Exp Ophthalmol* 2022;8(3):393-397.