

Content available at: <https://www.ipinnovative.com/open-access-journals>

The Journal of Dental Panacea

Journal homepage: <https://www.jdentalpanacea.org/>

Original Research Article

Bromelain vs trypsin-chymotrypsin in management of complications following surgical removal of mandibular

Madan Nanjappa^{1,*}, Shivani¹, Somak Saha¹¹Dept. of Oral Surgery, Vokkaligara Sangha Dental College & Hospital, Bengaluru, Karnataka, India

ARTICLE INFO

Article history:

Received 26-07-2022

Accepted 21-09-2022

Available online 30-09-2022

Keywords:

Bromelain

Impacted teeth

Postoperative edema

Third Molar

Trypsin

ABSTRACT

Introduction: Surgical removal of third molars is still the most common routine surgical procedure done by oral and maxillofacial surgeons which is usually associated with postoperative sequelae. In order to avoid or minimize post-surgical complications such as swelling, pain and trismus, patients are advised to use proteolytic enzyme and NSAID's along with routine antibiotics.

Materials and Methods: 50 patients who have bilateral symmetrical impacted mandibular third molars were included in the study. Post operatively, all patients were given antibiotics and analgesics for 5 days. Patients were given bromelain for 5 days after the procedure on one side and trypsin-chymotrypsin for 5 days on the other side with an interval of 21 days between the two procedures. Patients were recalled on day 1, day 3 and day 7 for assessment of post-operative trismus, pain and swelling based on measuring inter-incisal distance, visual analogue scale and, facial reference points.

Results and Analysis: Data was gathered and statistical assessment was done using SPSS software by using descriptive statistics and chi square test.

Conclusion : The conclusion drawn from the study was that bromelain has a significant effect on swelling, mouth opening and pain after surgical removal of impacted third molar than chymotrypsin. We suggest its usage in reduction of swelling and pain post operatively after surgical removal of third molar. However further studies with larger sample size and randomizations are required to confirm the same.

This is an Open Access (OA) journal, and articles are distributed under the terms of the [Creative Commons Attribution-NonCommercial-ShareAlike 4.0 License](#), which allows others to remix, tweak, and build upon the work non-commercially, as long as appropriate credit is given and the new creations are licensed under the identical terms.

For reprints contact: reprint@ipinnovative.com

1. Introduction

The knowledge of surgical procedure for removal of impacted mandibular third molar is one of the very firsts to be acquired by Oral and Maxillofacial surgeon. Simultaneously, this is the most common surgical procedure performed in a dental office by Oral and Maxillofacial surgeon worldwide.¹ Despite being a relatively straight forward procedure, the surgical removal of an impacted mandibular third molar is often associated with a specific set of post-operative complications, which often becomes a nagging concern for the surgeon. Therefore, the incidence

of specific complications should be thoroughly understood and, wherever possible, a preventive or management strategy should be applied.

Complications, such as pain, dry socket, swelling, paresthesia of the lingual or inferior alveolar nerve, bleeding, and infection are most common.² Proper antimicrobial treatment and oral wound care can accelerate the epithelial healing process, thereby preventing infection and chronicity of the wound. Systemic proteolytic enzyme therapy with chymotrypsin, serratiopeptidase, aprotinin, and bromelain are being increasingly used for wound healing and anti-inflammatory effects after impacted third molar surgery.

* Corresponding author.

E-mail address: nanjappamadan@yahoo.com (M. Nanjappa).

Bromelain is a blend of enzymes extracted from the stem and fruit of pineapple (*Ananas comosus*), and is known for its proteolytic action, which also contain components such as acid phosphatase, peroxidase, many protease inhibitors, and organically bound calcium.³ It is prepared by centrifugation, ultrafiltration, and lyophilisation of pine-apple juice. Bromelain alters pain mediators such as bradykinin, inhibiting the synthesis of pro-inflammatory prostaglandins, mainly PGE2. Its fibrinolytic action aids in the reabsorption of oedema into the blood circulation.⁴⁻⁶ Overall it was found to be reducing pain, swelling, and healing time. Bromelain has very low toxicity; its IgE-mediated allergenic potential cannot be underestimated. It is recommended to administer bromelain before food and daily dosage should be 750-1000mg/day in divided doses.⁷ However, there is not much literature comparing bromelain with other enzymatic preparations in treatment of inflammation associated with surgical removal of the third molar.

The purpose of this study was to comparatively assess the efficacy of bromelain with trypsin-chymotrypsin in management of post-operative trismus, pain and swelling after surgical removal of impacted lower third molar.

2. Materials and Methods

A comparative study was performed on 50 subjects of age group 18 - 45 years, requiring surgical extraction of bilaterally symmetrical impacted mandibular third molar teeth reporting to department of oral and maxillofacial surgery of V.S Dental College and Hospital, Bangalore, Karnataka, India. Patients with systemic diseases in whom tooth extraction is contraindicated, patients who are mentally challenged and who are unable to communicate, pregnant and lactating women, patients allergic to bromelain and immuno-compromised patients were excluded from the study.

Surgical removal of impacted mandibular third molars was performed under local anesthesia (2% lignocaine with 1:80000 adrenaline) in bilaterally symmetrical impacted mandibular third molar cases. Only one tooth was removed at a time. The second tooth removal was scheduled with a minimum gap of 3 weeks to allow resolution of post-operative symptoms following the first extraction. Post operatively, all patients received antibiotics and analgesics. Bromelain 200mg was administered BD (half an hour before meal) for 5 days after the procedure on one side, while trypsin-chymotrypsin (100000 Armour units of enzymatic activity in enteric coated tablets) was administered BD (half an hour before meal) for 5 days after the procedure on the other side.

Patients were recalled on day 1, day 3 and day 7 for assessment of post-operative trismus, pain and swelling. Trismus was assessed by measuring inter-incisal distance by measuring the maximal opening between the maxillary

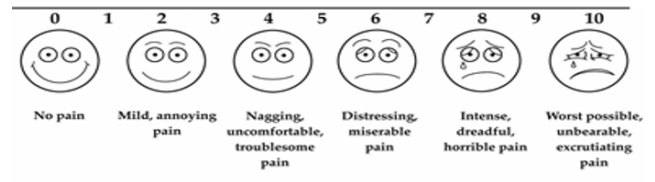


Fig. 1: 100 mm Visual analogue scale.

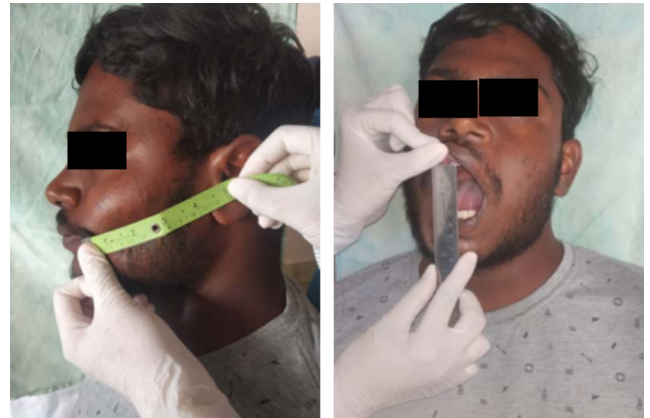

Fig. 2: Assessment of swelling and mouth opening.

ESUL and mandibular incisor. Pain was recorded using non calibrated 100mm visual analogue scale. The end points of the scale were 'no pain' and 'pain could not be worse'. Swelling was assessed by measuring the distance between two facial reference points i.e. from tragus to the corner of the mouth.

3. Results

50 patients were included in our study, out of which 27 were males and 23 were females. All patients had bilaterally symmetrical impacted mandibular 3rd molar teeth. The mean age was 30.16. Each patient was given bromelain on one side and trypsin-chymotrypsin on the other side. Data was analysed using SPSS software using chi square test, correlation methods to find the positivity or negativity performance of the drug. The range of the correlation lies between -1 to +1. The test used to find the significance is "t test: Two samples assuming unequal variances".

In the assessment of pain, the results showed that trypsin-chymotrypsin (0.631) showed better response in pain relief from day 1-3 compared to bromelain (0.239). However from day 1-7 bromelain (0.542) was superior in pain relief compared to trypsin-chymotrypsin (0.163). [Graphs 1 and 2].

Assessment of pain revealed trypsin-chymotrypsin (P-value=0.9) to be slightly better than bromelain (P-value=0.8). [Tables 1 and 2]

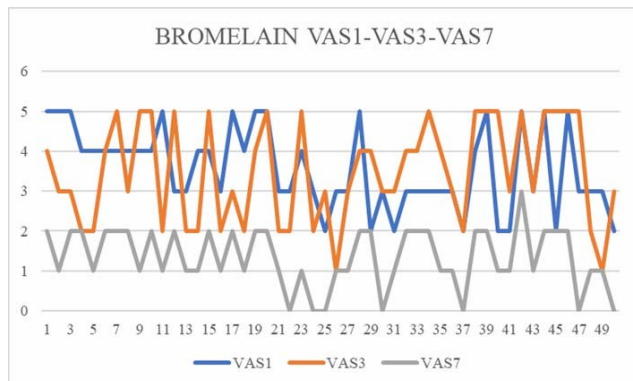
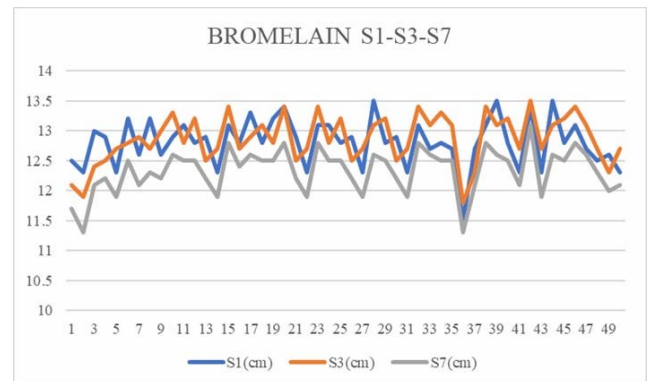
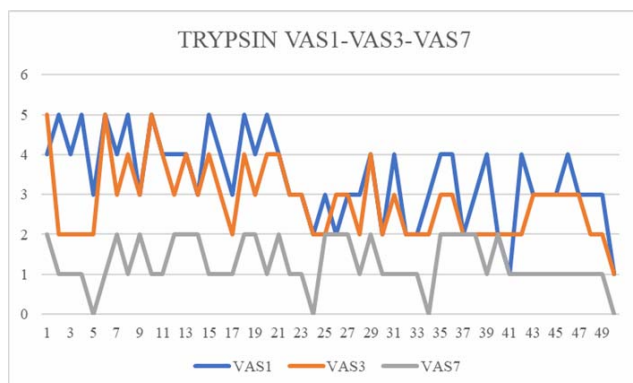
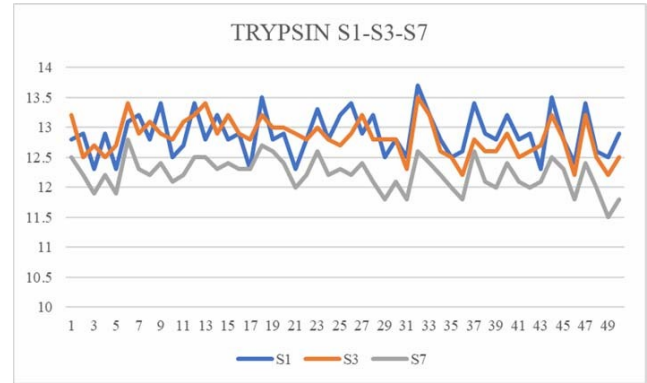
Assessment of swelling in the two groups showed almost similar response in both groups from day 1-3 (trypsin-

Table 1: Table showing pain assessment scores in bromelain group

Variables	N	Mean	SD	Standard Error	Skewness	Range	C.L(95.0%)
VAS1	50	3.56	1.033322	0.14613385	0.063999	2 to 5	0.293667
VAS3	50	3.48	1.281581	0.181242875	-0.13554	1 to 5	0.364221
VAS7	50	1.34	0.745326	0.105404953	-0.34553	0 to 3	0.211819

Table 2: Showing pain assessment scores in trypsin-chymotrypsin group.

Variables	N	Mean	SD	Standard Error	Skewness	Range	C.L (95.0%)
VAS1	50	3.42	1.051529	0.148708728	-0.27373	1 to 5	0.298841377
VAS3	50	2.84	0.933722	0.132048229	0.645297	1 to 5	0.26536085
VAS7	50	1.28	0.607437	0.085904551	-0.21671	0 to 2	0.172631658

**Graph 1:** Graphical representation of pain assessment in Bromelain group**Graph 3:** Graphical representation of swelling in bromelain group.**Graph 2:** Graphical representation of pain assessment in Trypsin-Chymotrypsin group**Graph 4:** Graphical representation of swelling in Trypsin-Chymotrypsin

chymotrypsin: 0.533, bromelain: 0.566). However from day 1-7 bromelain (0.806) was superior in reduction in size of swelling compared to trypsin-chymotrypsin (0.677). [Graphs 3 and 4]

Evaluation of swelling showed similar response in both drug groups (P-value=1). [Tables 3 and 4]

Assessment of mouth opening from day 1-3 showed better response to bromelain(0.400) compared to trypsin-chymotrypsin(0.312). From day 1-7 also bromelain(0.002)

showed better efficacy compared to trypsin-chymotrypsin(-0.520). [Graphs 5 and 6]

Assessment of mouth opening was found to be similar in both drug groups (P-value=0.0003). [Tables 5 and 6].

4. Discussion

The prevalence of third molar impaction in Indian population ranges from 18% to 32% with a slight sex predilection towards males.⁸ For the oral and maxillofacial

Table 3: Table showing assessment of swelling in bromelain group

Variables	N	Mean	SD	Standard Error	Skewness	Range	C.L(95.0%)
S1(cm)	50	12.81	0.402163	0.056874369	-0.54281	11.5 to 13.5	0.114293
S3(cm)	50	12.864	0.402928	0.056982633	-0.54092	11.8 to 13.5	0.114511
S7(cm)	50	12.33	0.374847	0.053011358	-0.70472	11.3 to 13.1	0.10653

Table 4: Table showing assessment of swelling in trypsin-chymotrypsin group

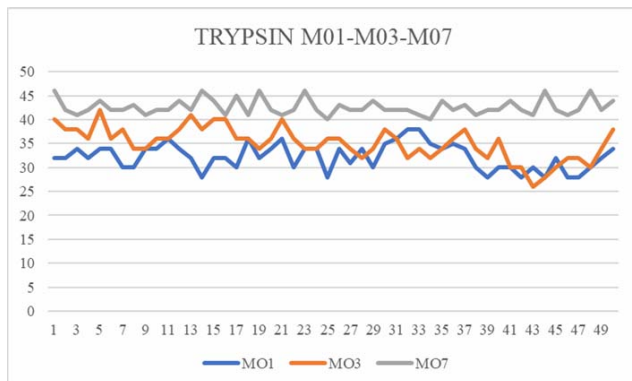
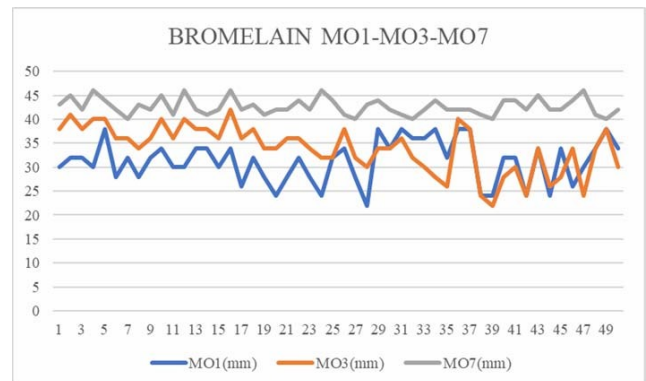
Variables	N	Mean	SD	Standard Error	Skewness	Range	C.L(95.0%)
S1(cm)	50	12.888	0.365133	0.05163767	0.191826	12.3 to 13.7	0.103769783
S3(cm)	50	12.834	0.315329	0.044594316	-0.0664	12.2 to 13.5	0.089615634
S7(cm)	50	12.22	0.273302	0.038650712	-0.22494	11.5 to 12.8	0.077671514

Table 5: Table showing assessment of mouth opening in bromelain group

Variables	N	Mean	SD	Standard Error	Skewness	Range	C.L(95.0%)
MO1(mm)	50	31.28	4.458608	0.630542365	-0.26223	22 to 38	1.267122
MO3(mm)	50	33.9	4.982623	0.704649283	-0.65373	22 to 42	1.416046
MO7(mm)	50	42.64	1.746834	0.247039615	0.485821	40 to 46	0.496445

Table 6: Table showing assessment of mouth opening in trypsin-chymotrypsin group

Variables	N	Mean	SD	Standard Error	Skewness	Range	C.L(95.0%)
MO1(mm)	50	32.32	2.736302	0.386971496	0.00191	28 to 38	0.777648336
MO3(mm)	50	35.1	3.394173	0.480008503	0.34055	26 to 42	0.964613202
MO7(mm)	50	42.62	1.652333	0.233675163	0.868269	40 to 46	0.46958782

**Graph 5:** Graphical representation of mouth opening in trypsin- chymotrypsin.**Graph 6:** Graphical representation of mouth opening in Bromelain group.

surgeon, It is of utmost importance to be familiar with all the possible peri-operative complications associated with the procedure for surgical removal of impacted third molars. Impacted teeth are often associated with pericoronitis, periodontitis, cystic lesions, neoplasm, root resorption and can cause detrimental effects on adjacent tooth. The procedure of surgical removal of impacted third molars commonly involves elevating the mucoperiosteal layer, adequate guttering of the bone, and performing an odontectomy. Surgical removal of the third molar can cause severe soft tissue and bone damage and inevitably leading to the release of various inflammatory mediators like

bradykinin, histamine, and serotonin, which can cause pain, swelling, and trismus.

Systemic proteolytic enzyme therapy is being increasingly used for wound healing and anti-inflammatory effects after impacted third molar surgery. These enzymes include Chymotrypsin and Trypsin (pancreatic proteases), Bromelain (pineapple enzyme), Papain (papaya enzyme), Fungal proteases and Serratia peptidase (the 'silk worm' enzyme). Proteolytic enzymes are administered to hasten the healing of damaged tissue and thus promote a complication free recovery. These effects are brought about by the anti-inflammatory, anti-thrombotic and fibrinolytic

properties which were demonstrated both in-vitro and in-vivo. Bromelain is a proteolytic enzyme extracted from the stem and fruit of the pineapple plant. It is considerably absorbable when taken by oral route without losing its proteolytic activity and without producing any major side effects. It inhibits the synthesis of the “proinflammatory” prostaglandins without affecting that of the “antiinflammatory” properties.⁹

Previously done studies have shown the effect of orally administered bromelain in reducing the postsurgical complications; these studies suggested few mechanisms of actions such as - (1) Altering pain mediators such as bradykinin, (2) Inhibiting the synthesis of pro-inflammatory prostaglandins, mainly PGE2 and (3) Its fibrinolytic action aids in the reabsorption of edema into the blood circulation.⁴

Tejpal singh et.al. studied the effect of bromelain in post-operative pain after third molar extraction in a prospective randomized trial which included 40 patients. They have found that bromelain was effective 70% of the patients in reduction of pain and swelling after surgical removal of the third molar.¹⁰

Viganò et.al., evaluated the efficacy of anti-inflammatory and analgesic properties of bromelain in oral and implant surgery. They conducted a prospective and controlled study where 300 oral surgery patients were selected, 150 of whom treated with bromelain and 150 with paracetamol and codeine. All patients who underwent placement of implants, extraction of partially or totally impacted molars, lateral maxillary sinus lift and enucleation of odontogenic cysts were included in the study. They found that in the bromelain group, inflammation, edema and trismus were statistically better than in the group that only received analgesics.¹¹

In our study, we noted that Bromelain when compared to Trypsin- Chymotrypsin after third molar surgery in bilaterally symmetrically impacted teeth showed considerable reduction of swelling, pain and increase in mouth opening, when compared swelling from tragus to corner of the mouth, mouth opening measured with a Vernier calliper from upper incisor to lower incisor and pain on Visual analogue scale with bromelain than trypsin-chymotrypsin.

5. Conclusion

In our study we can conclude that bromelain has a significant effect on swelling, mouth opening and pain after surgical removal of impacted third molar than chymotrypsin. We suggest its usage in reduction of swelling and pain post operatively in surgical removal of third molar. However further studies with larger sample size and

randomizations are required to confirm the same.

6. Source of Funding

None.


7. Conflict of Interest

None.

References

1. Kolokythas A. What is the scope of practice of oral and maxillofacial surgeons? *J Oral Maxillofac Surg.* 2021;79:267. doi:10.1016/j.joms.2020.10.021.
2. Kazancioglu HO, Kurklu E, Ezirganli S. Effects of ozone therapy on pain, swelling, and trismus following third molar surgery. *Int J Oral Maxillofac Surg.* 2014;43(5):644–8. doi:10.1016/j.ijom.2013.11.006.
3. Bromelain. Monograph. *Altern Med Rev.* 2010;15(4):361–8.
4. Inchingolo F, Tatullo M, Marrelli M, Inchingolo AM, Picciariello V, Inchingolo AD, et al. Clinical trial with bromelain in third molar exodontia. *Eur Rev Med Pharmacol Sci.* 2010;14(9):771–4.
5. Nor MZ, Ramchandran L, Duke M, Vasiljevic T. Characteristic properties of crude pineapple waste extract for bromelain purification by membrane processing. *J Food Sci Technol.* 2015;52(11):7103–12.
6. Pardhi V, Chivte P, Kothare A, Shanbhag T. An Overview of Purification and Activity of Bromelain. *Int J Recent Sci Res.* 2016;7(8):12860–5.
7. Novaes LDL, Jozala AF, Lopes AM, Santos-Ebinuma VDC, Mazzola PG, Pessoa Junior A. Stability, purification, and applications of bromelain: A review. *Biotechnol Prog.* 2016;32(1):5–13. doi:10.1002/btpr.2190.
8. Padhye MN, Dabir AV, Girotra CS, Pandhi VH. Pattern of mandibular third molar impaction in the Indian population: a retrospective clinico-radiographic survey. *Oral Surg Oral Med Oral Pathol Oral Radiol.* 2013;116(3):e161–6. doi:10.1016/j.oooo.2011.12.019.
9. Taussig SJ. The mechanism of the physiological action of bromelain. *Med Hypotheses.* 1980;6(1):99–104.
10. Singh T, More V, Fatima U, Karpe T, Aleem M, Prameela J, et al. Effect of proteolytic enzyme bromelain on pain and swelling after removal of third molars. *J Int Soc Prev Community Dent.* 2016;6(9):197–204. doi:10.4103/2231-0762.197192.
11. Viganò L, Casu C, Argenta F. Evaluation of the efficacy of bromelain in oral and implant surgery patients. *Italian J Dent Med.* 2017;2(3):83–9.

Author biography

Madan Nanjappa, Professor and HOD  <https://orcid.org/0000-0002-8708-5486>

Shivani, Post Graduate

Somak Saha, Post Graduate

Cite this article: Nanjappa M, Shivani, Saha S. Bromelain vs trypsin-chymotrypsin in management of complications following surgical removal of mandibular. *J Dent Panacea* 2022;4(3):133-137.