

Content available at: <https://www.ipinnovative.com/open-access-journals>

IP Journal of Otorhinolaryngology and Allied Science

Journal homepage: <https://www.joas.co.in/>

## Case Report

# Effect of alternate rapid maxillary expansion and constriction on pharyngeal airway– A case report

Sanjana Shetty<sup>1,\*</sup>, Naazia Shaikh<sup>2</sup>

<sup>1</sup>Dept. of Orthodontics and Dentofacial Orthopedics, Sinhgad Dental College and Hospital, Pune, Maharashtra, India

<sup>2</sup>Dept. of Orthodontics and Dentofacial Orthopedics, M A Rangoonwala College of Dental Science and research Center, Pune, Maharashtra, India



## ARTICLE INFO

### Article history:

Received 03-03-2022

Accepted 10-03-2022

Available online 16-04-2022

### Keywords:

Alt-RAMEC (Alternate Rapid Maxillary Expansion and Contraction protocol)

Computed Cone Beam Tomography (CBCT)

Skeletal Class III Malocclusion

Airway Changes

## ABSTRACT

The Alt-RAMEC protocol was introduced by Liou in the year 2005. It allows for sutural mobilisation by opening and closing the RME screw for 7-9 weeks. Maxillary protraction after the use of Alt-RAMEC (Alternate Rapid Maxillary Expansion and Contraction) protocol is an efficient method for early treatment skeletal Class III malocclusion. This case report shows the results of the using hyrax bonded maxillary expander with Alt-RAMEC protocol to treat a maxillary hypoplasia Class III malocclusion. A 10-year-old patient with skeletal class III malocclusion with anterior as well as unilateral posterior crossbite was treated using this protocol. CBCT scans were taken before and after expansion. These CBCT scans were used for assessing and analyzing the airway tissue changes that have occurred after using Alt-RAMEC protocol. The objective of this case report is to assess airway changes after using Alt-RAMEC protocol.

This is an Open Access (OA) journal, and articles are distributed under the terms of the [Creative Commons Attribution-NonCommercial-ShareAlike 4.0 License](#), which allows others to remix, tweak, and build upon the work non-commercially, as long as appropriate credit is given and the new creations are licensed under the identical terms.

For reprints contact: [reprint@ipinnovative.com](mailto:reprint@ipinnovative.com)

## 1. Introduction

When treating a Class III malocclusion, doctors are faced with a predicament. The time of treatment varies, from early intervention during the pre-pubertal phases of development to intervention after the patient has completed active growth. Treatment options include dentofacial orthopedics, camouflage orthodontics, and a combination orthognathic surgical and orthodontic approach.<sup>1,2</sup> The most often used approach for early treatment of these individuals is protraction face mask (PFM) therapy paired with rapid maxillary expansion (RME). Liou introduced the Alt-RAMEC (Alternate Rapid Maxillary Expansion and Contraction protocol) in 2005.<sup>3</sup> It enables for sutural mobilisation by opening and closing the RME screw for 7-9 weeks.<sup>4,5</sup> In contrast to standard RME, its application strategy is to enhance the frequency of rapid maxillary

expansion by alternating rapid expansion and constriction several times. The Alt-RAMEC procedure was shown to have double the amount of anterior maxillary displacement as the regular RME protocol. Previous research found that using the Alt-RAMEC regimen in conjunction with maxillary protraction resulted in an increase in pharyngeal airway. Volumetric measurements are possible using CBCT (Cone beam computed tomography), which is more beneficial for analyzing the morphology of airway structures.<sup>6</sup> The three-dimensional measurement of the airway cavity is superior to the traditional two-dimensional approaches for evaluating it. The goal of this case report is to study and analyse the airway alterations that occur immediately following Alternate Rapid Maxillary Expansion and Constriction utilising CBCT images recorded before and after the technique is applied.

\* Corresponding author.

E-mail address: [sanjanashetty816@gmail.com](mailto:sanjanashetty816@gmail.com) (S. Shetty).

## 2. Case History

The patient, 10 years old, came to Department of Orthodontics and Dentofacial Orthopedics with a complaint of backwardly placed upper teeth, an un-aesthetic dental and facial appearance. Patient also had anterior cross-bite in addition to bilateral posterior cross-bite. Class III malocclusion with maxillary retrusion was seen in the patient. (Figure 1)

The treatment objectives were to obtain a normal profile by skeletal correction, correct the Class III dental relationship and obtain Class I canine and Class I incisal relationship.

The patient was delivered a bonded type of RME appliance with a Hyrax expansion screw in the middle and an occlusal splint (extending from the distal of the canines and encompassing the posterior teeth) for the Alt-RAMEC protocol. (Figure 2). The maxilla was expanded and contracted alternating weeks by 4 one quarter turns per day (1 mm) and this was continued for 9 weeks ending with expansion. (Figure 3).

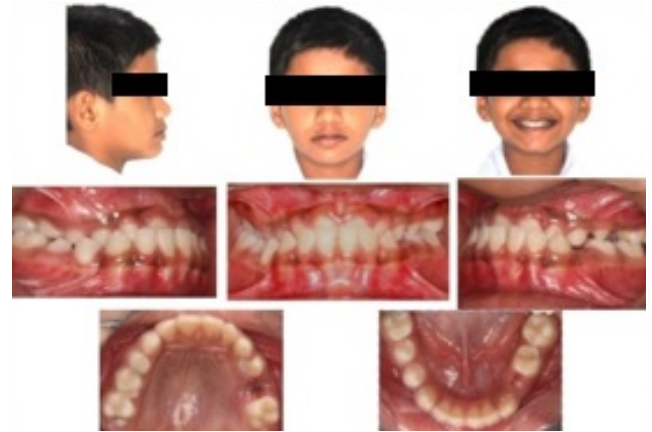**Table 1:** Pre-treatment and post-treatment measurements of upper pharyngeal airway, lower pharyngeal airway and total pharyngeal airway.

	Pre-treatment measurements (T1)	Post-treatment measurements (T2)	Difference (T2-T1)
Pharyngeal compartment	4.269 cm <sup>3</sup>	4.470 cm <sup>3</sup>	0.201 cm <sup>3</sup>
Anterior nasal compartment	2.151 cm <sup>3</sup>	2.756 cm <sup>3</sup>	0.605 cm <sup>3</sup>
Nasal compartment	23.612 cm <sup>3</sup>	25.14 cm <sup>3</sup>	1.528 cm <sup>3</sup>
Total airway	30.032 cm <sup>3</sup>	32.366 cm <sup>3</sup>	2.334 cm <sup>3</sup>

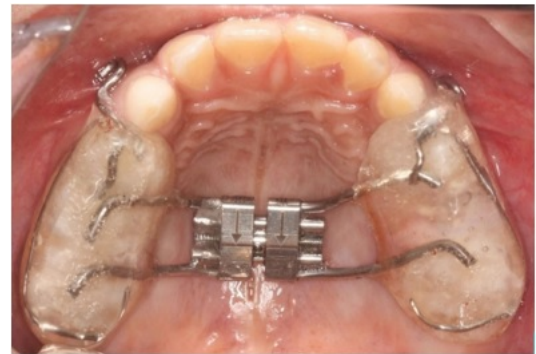
Two sets of CBCT scans were performed: one before to the start of the therapy and one immediately after the expansion according to the Alt-RAMEC protocol was finished.

The teeth that were bonded for Hyrax maxillary expander were first permanent molar and deciduous second molar on both sides.

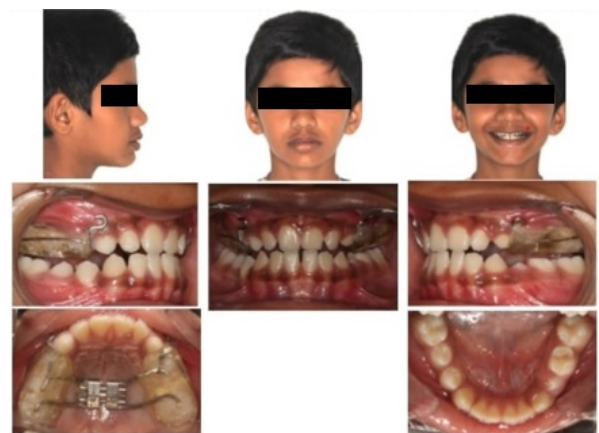For measurement of airway it was divided into 3 parts- anterior nasal compartment, nasal compartment and posterior compartment. Horizontal reference planes and a vertical reference plane was used in both pre-treatment and post-treatment in CBCT scans in the sagittal view. VRP passed through sellion (deepest midpoint on angle formed between nose and forehead) and alar curvature points. HRP 1 passed through infraorbital point and porion. Parallel to HRP 1, two other planes were drawn. HRP 2 passed through posterior nasal spine and HRP 2 passed through most anterior and inferior point of second cervical vertebra.



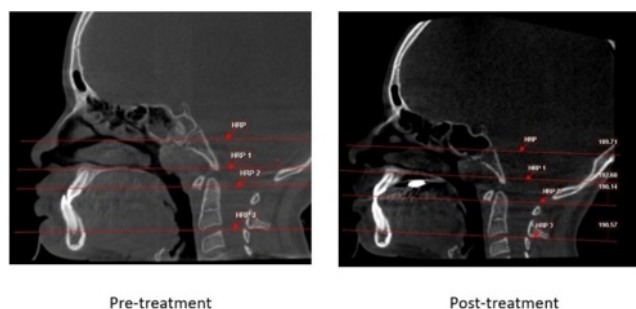
**Fig. 1:** Pre-treatment photographs.



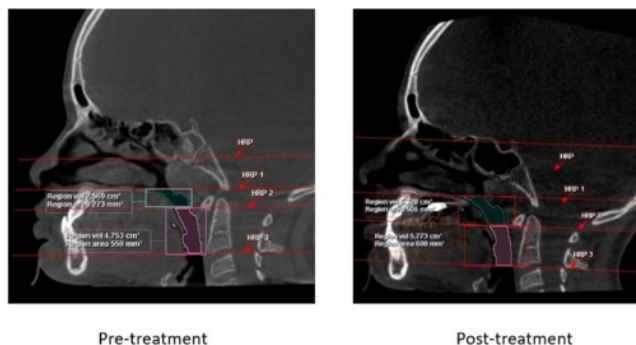
**Fig. 2:** Rapid maxillary expander delivered.



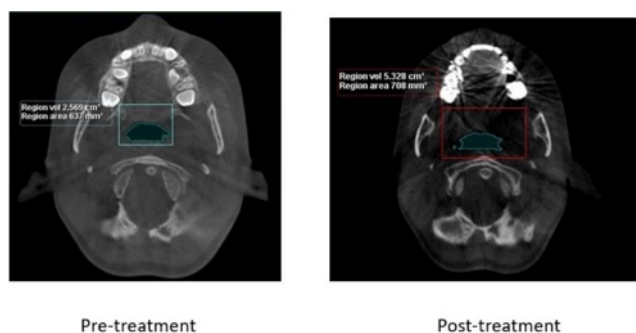
**Fig. 3:** Post-treatment photographs.



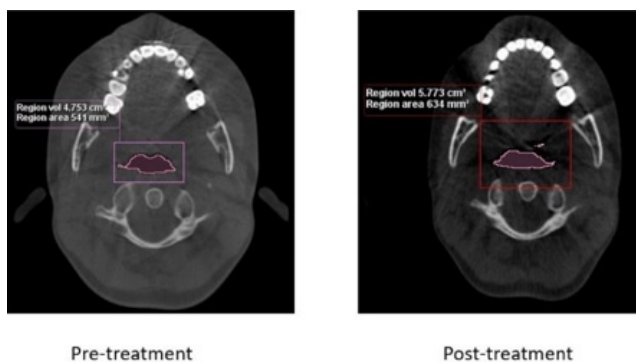
**Fig. 4:** Horizontal reference planes.



**Fig. 5:** Measurement of upper pharyngeal airway (green) and lower pharyngeal airway (pink).



**Fig. 6:** Measurement of upper pharyngeal airway in axial view.



**Fig. 7:** Measurement of lower pharyngeal airway in axial view.

The nasal compartment was measured volumetrically anterior to VRP. The nasal compartment was measured with HRP 1 as upper border and HRP 2 as lower border. The pharyngeal compartment was measured with HRP 2 as upper border and HRP 3 as lower border. (Figure 5) The airway was assessed in axial plane too so as to make sure that entire air cavity is covered. (Figure 6) (Table 1)

### 3. Results

After using the Alt-RAMEC technique, the volume of all compartments of airway increased. The total volume of the pharyngeal airway was also increased. The rise was greater in the nasal compartment than in the others.

### 4. Discussion

Alternate rapid maxillary expansion and constriction is a modification of the conventional Rapid maxillary expansion. The use of the Alt-RAMEC regimen prior to maxillary protraction is a successful strategy for treating individuals with Class III malocclusions early.<sup>4</sup> The purpose of this strategy is to enhance the efficacy of a device that requires patient cooperation, to increase the ease and effectiveness of the procedure in a short amount of time, to avoid unfavorable dentoalveolar consequences, and to create more skeletal results from the procedure. Increasing the skeletal impact lowers the risk of post-treatment relapse, which is one of the most important problems in orthodontic treatment.<sup>7</sup> The Alt-RAMEC protocol accomplishes significantly greater circumaxillary suture disjunction than the Rapid maxillary expansion strategy. The amount of maxillary protraction observed under the Alt-RAMEC protocol was 4-5 mm in 5 months, while it was 1.5-3.0 mm in 10-12 months under the Rapid maxillary expansion protocol.<sup>4</sup>

The pharyngeal airway space and different craniofacial skeletal pattern morphology of patients, both in anteroposterior aspect (Class I, class II, class III skeletal patterns) and vertical aspect (dolichofacial, mesofacial, brachyfacial) have been co-related and discussed in the orthodontic literature for quite some time. According to several studies, patients with Class III malocclusion typically have velopharynx constriction, pharyngeal airway constriction, nasal obstruction, or choanal stenosis, which can be caused by maxillary hypoplasia and retrusion.<sup>8-10</sup> For decades, lateral cephalometry has been utilized to examine airway size and shape due to its great reproducibility and minimal radiation exposure. The disadvantage of using lateral cephalometric radiographs for upper airway evaluation is that they only give 2-dimensional representations of complicated 3-dimensional anatomic components and do not provide a full-scale image of the upper airway.<sup>11</sup> CBCT imaging uses low radiation doses to offer a good picture of tissues with minimum image

distortion. The use of CBCT aids in the correct volumetric measuring of the airway.

According to the findings of this case study, the all three compartments of airways as well as the total pharyngeal airway, expanded following the administration of the Alt-RAMEC regimen. Increase was maximum in nasal compartment. This indicates upper pharyngeal airway increased more than lower pharyngeal airway. The forward movement of the retrusive maxilla is responsible for the expansion in upper pharyngeal airway. The increase in lower pharyngeal airway is attributed to increase in the GoMe-SN and FMA angles that are associated with maxillary expansion. There are very few studies in the literature that evaluate the pharyngeal changes after expansion using Alt-RAMEC. Celikoglu M, Buyukcavus<sup>12</sup> MH conducted a study to assess changes in pharyngeal airway dimensions after the Alt-RAMEC/FM protocol. The considerable forward movement of the maxilla resulted in an increase in upper pharyngeal airway dimension, but no significant variation in lower pharyngeal airway dimension was noted. Ozbilena E et.al.<sup>13</sup> conducted a retrospective study for comparative evaluation of the changes in pharyngeal airway after RME/PFM and Alt-RAMEC/PFM. It was observed that the lower and total pharyngeal airway increased significantly after Alt-RAMECPFM.

## 5. Conclusion

Because of the substantial forward movement of the maxilla caused by this technique, the volume of the pharyngeal airway, particularly the upper pharyngeal airway, increases. In the future, more detailed research on the airway changes following Alt-RAMEC are needed.

## 6. Source of Funding

None.

## 7. Conflict of Interest

The author declares that there is no conflict of interest.

## References

1. Guyer EC, Ellis I, McNamara JA, Behrents RG. Components of Class III malocclusion in juveniles and adolescents. *The Angle Orthodontist*. 1986;56(1):7–30. doi:10.1043/0003-3219(1986)056<0007:COCIMI>2.0.CO;2.
2. Ellis E, McNamara JA, A J. Components of adult Class III malocclusion. *Journal of Oral and Maxillofacial Surgery*. 1984;42(5):295–305. doi:10.1016/0278-2391(84)90109-5.
3. Liou EJW. Toothborne orthopedic maxillary protraction in Class III patients. *J Clin Orthod*. 2005;39(2):68–75. [15735356].
4. Liou EJ, Tsai WC. A new protocol for maxillary protraction in cleft patients: repetitive weekly protocol of alternate rapid maxillary expansions and constrictions. *Cleft Palate Craniofac J*. 2005;42(2):121–7. doi:10.1597/03-107.1.
5. Liou EJ. Effective maxillary orthopedic protraction for growing Class III patients: a clinical application simulates distraction osteogenesis. *Prog orthod*. 2005;6(2):154–71. [16276426].
6. Aboudara C, Nielsen I, Huang JC, Maki K, Miller AJ, Hatcher D, et al. Comparison of airway space with conventional lateral headfilms and 3-dimensional reconstruction from cone-beam computed tomography. *Am J Orthod Dentofacial Orthop*. 2009;135(4):468–79. doi:10.1016/j.ajodo.2007.04.043.
7. Sung SJ, Baik HS. Assessment of skeletal and dental changes by maxillary protraction. *Am J Orthod Dentofacial Orthop*. 1998;114(5):492–502. doi:10.1016/s0889-5406(98)70168-4.
8. Iwasaki T, Hayasaki H, Takemoto Y, Kanomi R, Yamasaki Y. Oropharyngeal airway in children with Class III malocclusion evaluated by cone-beam computed tomography. *Am J Orthod Dentofacial Orthop*. 2009;136(3):318–9. doi:10.1016/j.ajodo.2009.02.017.
9. Martin O, Muelas L, Viñas MJ. Comparative study of nasopharyngeal soft-tissue characteristics in patients with Class III malocclusion. *Am J Orthod Dentofacial Orthop*. 2011;139(2):242–51. doi:10.1016/j.ajodo.2009.07.016.
10. Kiliç AS, Arslan SG, Kama JD, Ozer T, Dari O. Effects on the sagittal pharyngeal dimensions of protraction and rapid palatal expansion in Class III malocclusion subjects. *Eur J Orthod*. 2008;30(1):61–6. doi:10.1093/ejo/cjm076.
11. Stratemann SA. Three-dimensional craniofacial imaging: airway and skeletal morphology. *Am J Orthod Dentofacial Orthop*. 2006;130:807.
12. Celikoglu M, Buyukcavus MH. Changes in pharyngeal airway dimensions and hyoid bone position after maxillary protraction with different alternate rapid maxillary expansion and construction protocols: a prospective clinical study. *Angle Orthod*. 2017;87(4):519–25. doi:10.2319/082316-632.1.
13. Ozbilen EO, Yilmaz HN, Kucukkeles N, N. Comparison of the effects of rapid maxillary expansion and alternate rapid maxillary expansion and constriction protocols followed by facemask therapy. *Korean J Orthod*. 2019;49(1):49–58. doi:10.4041/kjod.2019.49.1.49.

## Author biography

Sanjana Shetty, Post Graduate

Naazia Shaikh, Post Graduate

**Cite this article:** Shetty S, Shaikh N. Effect of alternate rapid maxillary expansion and constriction on pharyngeal airway– A case report. *IP J Otorhinolaryngol Allied Sci* 2022;5(1):13-16.