

Content available at: <https://www.ipinnovative.com/open-access-journals>

IP International Journal of Maxillofacial Imaging

Journal homepage: <https://www.ijmi.in/>

Case Report

Endodontic management of pulp canal obliteration: A case report of two cases

Nishant Sinha¹, Ashish Kamboj^{1,*}, S S Chopra², Ashok Rathod³, Pritam Mohanty⁴, Prateek Mathur⁵

¹Government Dental Centre, Leh, (UT of Ladakh), India

²Dept. of Dental Surgery, Armed Forces Medical College, Pune, Maharashtra, India

³AFDC, New Delhi, India

⁴Dept. of Orthodontics, KIDS, KIIT-DU, Bhubaneswar, Odisha, India

⁵Dept. of Orthodontics, ADC R&R, Delhi, India



ARTICLE INFO

Article history:

Received 21-02-2022

Accepted 25-02-2022

Available online 07-04-2022

Keywords:

Dental trauma

Discolouration

Pulp canal obliteration

Root canal treatment

ABSTRACT

Pulp canal obliteration (PCO) is defined as a deposition of hard tissue within the root canal space and a yellow discoloration of clinical crown. These tissues can eventually produce the radiographic appearance of a root canal space that has become partial or completely calcified. These teeth provide an endodontic treatment challenge. The critical management decision being whether to treat these teeth endodontically immediately upon detection of the pulpal obliteration or to wait until symptoms or signs of pulp or periapical disease occur.

Success in root canal treatment is based on proper debridement, disinfection and obturation of the root canal system. However, this procedure may be difficult or even impossible to achieve if the pulpal space is calcified. The endodontic treatment performed under these circumstances pose the risk of root perforation, a complication that seriously affects the long-term prognosis of tooth. The present article discusses a series of cases of endodontic treatment in teeth with partially or completely PCO and methods for the clinical management of these cases using contemporary endodontic techniques.

This is an Open Access (OA) journal, and articles are distributed under the terms of the [Creative Commons Attribution-NonCommercial-ShareAlike 4.0 License](https://creativecommons.org/licenses/by-nc-sa/4.0/), which allows others to remix, tweak, and build upon the work non-commercially, as long as appropriate credit is given and the new creations are licensed under the identical terms.

For reprints contact: reprint@ipinnovative.com

1. Introduction

Pulp canal obliteration (PCO), also called calcific metamorphosis (CM) is defined as a deposition of hard tissue within the root canal space. This may occur idiopathically or following direct pulp capping or trauma.^{1,2} The exact mechanism of PCO is unknown but is believed to be related to damage to the neurovascular supply of the pulp at the time of injury.^{3,4} The calcification of the pulp chamber results in a darker hue, the loss of translucency and the yellowish appearance of the crown of the tooth.⁵ Pulp necrosis has also been reported as a complication,^{6,7} with

ranges varying from 1% to 16%. Periapical lesion develops in a range of 7.3% to 24% in these cases up to 4 years after initial traumatic injury, especially in completely calcified teeth.^{6,8} Success in root canal treatment is based on proper debridement, disinfection and obturation of the root canal system. However, this procedure may be difficult or even impossible to achieve if the pulpal space is partially or completely calcified. The endodontic treatment performed under these circumstances pose the risk of perforating the root, a complication that seriously affects the long-term prognosis of the tooth. If calcified root canal treatment fails, the endodontic surgical intervention may be the only possible alternative other than extraction of the tooth. Although its importance could not be underestimated, there

* Corresponding author.

E-mail address: aashishkamboj@gmail.com (A. Kamboj).

is a lack in the literature regarding the optimum treatment of teeth showing signs of PCO. We herein report two cases of endodontic treatment in teeth with partial as well as complete PCO.

1.1. Case report-1

A 64 years old male presented with a history of pain involving tooth 14 since last one month. On clinical examination a mesial proximal caries was detected and the tooth was extremely tender to percussion. Pre-operative RVG revealed periodontal ligament widening and evidence of peri apical radiolucency at the periapex of the tooth. RVG also revealed presence of two roots with complete obliteration of the pulp chamber as well as the root canals. (Figure 1 A).

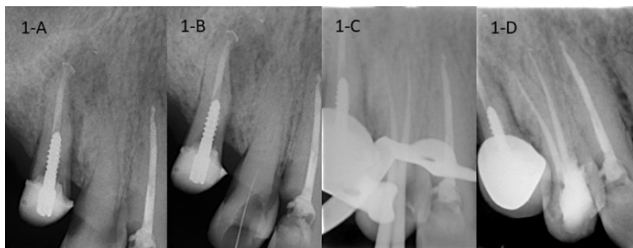


Fig. 1: A: Diagnostic RVG showing complete obliteration of pulp chamber and root canals B: Scouting of buccal canal C: RVG with master cones D: Post obturation RVG

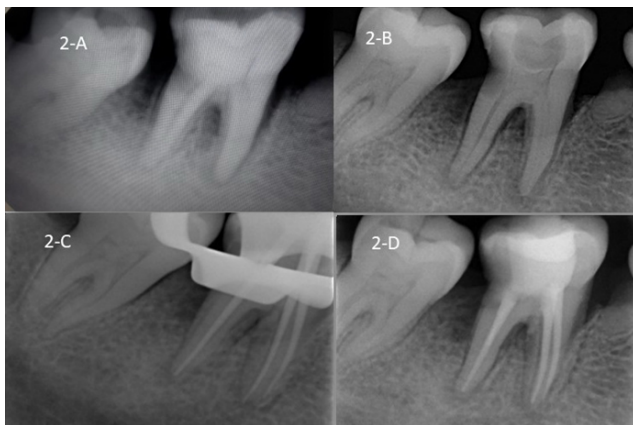


Fig. 2: A: Diagnostic RVG showing complete obliteration of pulp chamber B: RVG guided access cavity preparation C: Cone fit RVG D: Post obturation RVG

A diagnosis of symptomatic apical periodontitis with complete obliteration of the pulp canal was made, and a nonsurgical root canal treatment was advised to the patient. After obtaining consent, the patient was anesthetized, and a rubber dam was placed on the tooth. Access cavity was made till the level of CEJ using a round bur and caries was excavated. Scouting of the canal orifices was done

using a DG 16 explorer. The buccal canal was located first and radiographically confirmed using a no 10 C plus file. (Figure 1 B). Ultrasonic tips were used to trough the pulpal floor to uncover the palatal canal orifice. Once the patency was obtained a no 10 C Plus file was used with 17% EDTA (RCT Prep Waldent) to reach till the apex. Working length was measured using an electronic apex locator and was confirmed radiographically. (Figure 1 C). A glide path was made till the size of 2%20 using stainless steel K files (M- Access Dentsply). The root canals were irrigated thoroughly with 5.25% sodium hypochlorite (Prime dental products). An intra canal medicament of calcium hydroxide was given and patient was recalled after one week. In the next appointment chemo mechanical preparation was completed using Pro Taper Next (Dentsply) rotary files till master apical size of X2. Cone fit radiograph was taken and root canals were obturated by single cone technique (Figure 1 D).

1.2. Case report-2

An 18 years old female reported with the chief complaint of pain in the lower right back tooth since last one month. Patient gave a history of orthodontic treatment by fixed appliance one year back. On clinical examination periodontal pockets were detected both on the mesial and distal of tooth 46 and the tooth was also tender to percussion. Pre-operative RVG revealed periodontal ligament widening and evidence of peri apical radiolucency associated with the mesial root. RVG also revealed presence of complete obliteration of the pulp chamber however the root canals were patent (Figure 2 A).

A diagnosis of symptomatic apical periodontitis with obliteration of the pulp chamber was made, and a nonsurgical root canal treatment was advised to the patient. After obtaining consent, the patient was anesthetized, and a rubber dam was placed on the tooth. A round bur was used for access preparation, which was guided with intermittent radiographs (Figure 2 B) to ensure access preparation coinciding with the pulp chamber anatomy. This helped us to avoid unnecessary removal of tooth substance and preparation of a conservative access cavity. The calcification from the pulp chamber was removed conservatively using ultrasonic tips. The distal canal orifice had diffuse calcifications which had to be removed using ultrasonic tips. Once the access to canals were made a working length RVG was taken. Chemo mechanical preparation was completed using Pro Taper Next rotary files till master apical size of X2 using copious irrigation with 5.25% sodium hypochlorite. Cone fit radiograph was taken (Figure 2 C) and root canals were obturated by single cone technique (Figure 2 D).

2. Discussion

Aetiology of PCO is unclear in literature and factors like trauma, aging, orthodontic treatment, systemic diseases, and chronic irritation of the pulp due to deep caries and restorations have been implicated as the causative factors.

These teeth are generally asymptomatic and are often an incidental finding during routine clinical and radiographic examination.⁸ Most of these patients have the chief complaint of tooth discoloration when they report to the dental office. There is considerable disagreement in literature regarding the decision to treat cases of pulpal obliteration. It is recommended that root canal treatment should be initiated in teeth with PAI scores ≥ 3 and a negative response to pulp sensibility testing.⁸ In both our cases reported here, the teeth were tender on percussion and there were radiographic signs of periapical radiolucency. Complete or partial radiographic obliteration does not necessarily mean the absence of the pulp canal space.⁹ This was confirmed in our first case in which we managed to enlarge the canals till the size of Pyramidal Tract Neuron X2 file size.

The localization and access of calcified root canals are a challenge in endodontic practice which may cause serious problems such as severe loss of dentine and perforation. The knowledge of root canal anatomy is paramount for the clinical success. It has been established that if the access preparation remains well centred and aligned to the long axis of the tooth at the level of the cementum-enamel junction (CEJ), the root canal is normally easy to locate.⁶ In the cases herein described, low speed burs associated with ultrasonic tips were used to selectively remove the calcified dentin.

A variety of 'path finding' instruments with different designs are available. C Plus files are ideal for initial instrumentation of calcified canals. Their reduced flute and greater shaft strength with active cutting tip make them more likely to penetrate highly calcified canals.

3. Conclusion

We attribute the success observed in these cases to the localization of patent canals and their complete debridement and sealing in full extension. The protocols herein described permitted the avoidance of unnecessary cutting of dentin and perforation of the teeth. The results reinforce the importance of centered and angulated radiographs to evaluate the depth reached by instruments, slow speed burs and ultrasonic tips. Teeth with PCO requiring root canal treatment are very challenging and time-consuming but the use of new technologies, good knowledge of pulp anatomy and radiographic techniques and patience, are the keys to

success in solving cases of PCO.

4. Source of Funding

None.

5. Conflict of Interest

None.

References

1. Neville BW, Damm DD, Allen CM, Bouquet JE. Oral and Maxillofacial Pathology; 1995. p. 928.
2. Ngeow WC, Thong YL. Gaining access through a calcified pulp chamber: a clinical challenge. *Int Endod J.* 1998;31(5):367–71. doi:10.1046/j.1365-2591.1998.00176.x.
3. Yaacob HB, Hamid JA. Pulpal calcifications in primary teeth: A light microscope study. *J Pedod.* 1986;10(3):254–64. doi:10.1016/S0099-2399(06)81673-0.
4. Robertson A. A retrospective evaluation of patients with uncomplicated crown fractures and luxation injuries. *Endod Dent Traumatol.* 1998;14(6):245–56. doi:10.1111/j.1600-9657.1998.tb00848.x.
5. Pateron SS, Mitchell DF. Calcific metamorphosis of the pulp: its incidence and treatment. *Oral Surg Oral Med Oral Pathol.* 1965;24(6):94–101. doi:10.1016/0030-4220(67)90521-x.
6. Amir FA, Gutmann JL, Witherspoon DE. Calcific metamorphosis: a challenge in endodontic diagnosis and treatment. *Quintessence Int.* 2001;32(6):447–55.
7. De Cleen M. Obliteration of pulp canal spaces after concussion and subluxation: endodontic considerations. *Quintessence Int.* 2002;33(9):661–70. doi:10.1016/S0099-2399(06)80039-7.
8. Oginni AO, Sofowora CAA, Kolawole KA. Evaluation of radiographs, clinical signs and symptoms associated with pulp canal obliteration: an aid to treatment decision. *Dent Traumatol.* 2009;25(6):620–5. doi:10.1111/j.1600-9657.2009.00819.x.
9. Kuyk JK, Walton RE. Comparison of the radiographic appearance of root canal size to its actual diameter. *J Endod.* 1990;16(11):528–61. doi:10.1016/S0099-2399(07)80215-9.

Author biography

Nishant Sinha, Endodontist

Ashish Kamboj, Orthodontist

S S Chopra, Professor

Ashok Rathod, Endodontist

Pritam Mohanty, Professor

Prateek Mathur, Resident Officer

Cite this article: Sinha N, Kamboj A, Chopra SS, Rathod A, Mohanty P, Mathur P. Endodontic management of pulp canal obliteration: A case report of two cases. *IP Int J Maxillofac Imaging* 2022;8(1):13-15.