



Case Report

Endonyx onychomycosis due to *Trichophyton soudanense*: Rare case with successful treatment

Sana Islahi¹, Anupam Das^{2,*}, Abhilash Chandra³, Manodeep Sen², Jaya Garg², Kirti Maurya, Jyotsna Agarwal²

¹Dept. of Microbiology, All India Institute of Medical Sciences, Raebareli, Uttar Pradesh, India

²Dept. of Microbiology, Dr. Ram Manohar Lohia Institute of Medical Sciences, Lucknow, Uttar Pradesh, India

³Dept. of Nephrology, Dr. Ram Manohar Lohia Institute of Medical Sciences, Lucknow, Uttar Pradesh, India



ARTICLE INFO

Article history:

Received 01-03-2021

Accepted 04-03-2021

Available online 02-04-2021

Keywords:

Onychomycosis

Trichophyton soudanense

Epidemiology

ABSTRACT

Dermatophytoses are infections of the skin, hair and nails, caused by dermatophytes, namely *Trichophyton* spp, *Microsporum* spp and *Epidermophyton floccosum*. *Trichophyton soudanense* is an anthropophilic fungus, a frequent cause of tinea capitis in Africa though some imported cases are now been reported from Europe, Brazil, Australia and USA. Until now, 3 cases of *T.soudanense* causing tinea capitis, tinea unguium, tinea corporis from North India and 2 cases causing tinea corporis and tinea cruris from south India have been reported, but this is probably the first case report of onychomycosis caused by *T.soudanense* in India.

© This is an open access article distributed under the terms of the Creative Commons Attribution License (<https://creativecommons.org/licenses/by/4.0/>) which permits unrestricted use, distribution, and reproduction in any medium, provided the original author and source are credited.

1. Introduction

Dermatophytoses are infections of the skin, hair and nails, caused by dermatophytes, namely *Trichophyton* spp, *Microsporum* spp and *Epidermophyton floccosum*. Dermatophytes though have a worldwide distribution, yet few species are endemic in specific areas of the world.¹ *Trichophyton soudanense* is an anthropophilic fungus that is a frequent cause of tinea capitis in Africa and Asia. Besides Africa, some imported cases are now been reported from Europe, Brazil, Australia and USA. This is the first case report of onychomycosis caused by *T. soudanense* in India, however 3 cases of *T. soudanense* causing tinea capitis, tinea unguium, tinea corporis from North India² and 2 cases causing tinea corporis and tinea cruris from south India have been reported.³

2. Case Report

A 40-year-old male, software engineer residing in Philippines since four years, with no comorbidities developed a milky white growth of his left middle toe nail in October 2017. It gradually increased, but remained confined to single toe nail only. He is required to wear shoes for around 10-12 hours a day. He came back to India on August 2018 and the case was referred to our department for fungal microscopy and culture, from the outpatient department of Nephrology of our institution, where he visited for a minor complaint. There were no clinical signs of inflammation in the nail bed [Fig 3a]. Direct 10% KOH mount from the specimen was positive for fungal elements and culture of the specimens on Sabouraud's dextrose agar supplemented with 0.05% chloramphenicol and 0.5% cycloheximide yielded colonies of *T. soudanense* after 3 weeks of incubation at 25°C. Isolates were identified on the basis of colony morphology which was slow growing, initially flat, with a suede-like texture, a spidery edge and a distinctive orange-yellow color [Fig 1a and 1b]. Lactophenol cotton blue mount of the slide culture exhibited short, segmented hyphae,

* Corresponding author.

E-mail address: dranupam06@yahoo.co.in (A. Das).

reflexive branching and no macroconidia [Fig 2a and 2b]. On Lowenstein-Jensen medium, the isolates produced dark brown pigment. Urease test and hair perforation test were negative.¹ He was started with Itraconazole 200mg twice daily for first seven days of every month for three months, since August 2018. The fresh healthy nail started growing in his toe [Fig 3b and 3c].



Fig. 1: Colony morphology of *Trichophyton soudanense* on Sabouraud's Dextrose Agar

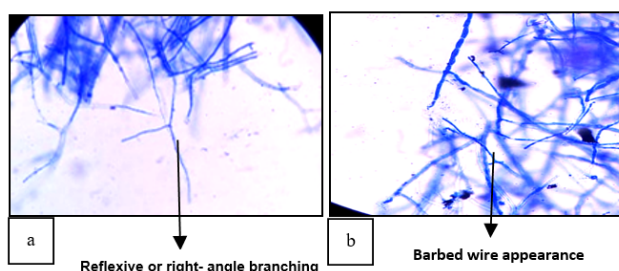


Fig. 2: Lactophenol cotton blue (LCB) mount of *Trichophyton soudanense* showing the characteristic segmented hyphae with no macroconidia (LCB×400).

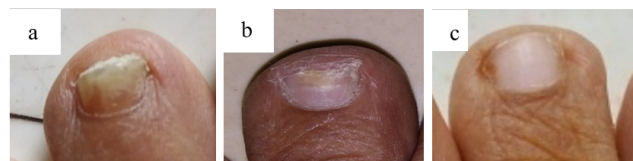

Fig. 3: **a:** Left Middle toenail, before treatment; **b:** Left Middle toe nail, after two months of treatment; **c:** Left middle toe nail, after three months of treatment

3. Discussion

Certain species of dermatophytes are worldwide in distribution whereas others are geographically restricted. Examples of these cosmopolitan species are *Epidermophyton floccosum*, *Microsporum audouinii*, *T. rubrum*, *T. tonsurans* and *T. violaceum* etc.⁴ These cosmopolitan species are able to establish themselves in new geographical areas when carriers move from original endemic areas.⁵

Onychomycosis has been classified into five clinical presentations according to the modes of invasion: distal and lateral subungual onychomycosis, proximal subungual onychomycosis (PSO), superficial white onychomycosis (SWO), endonyx onychomycosis and mixed onychomycosis (complete nail dystrophy, secondary onychomycosis and paronychia-associated onychomycosis).⁶ Recent literature classified endonyx as a distinct group of onychomycosis with a characteristic mechanism by which fungal elements reach the nail plate via the finger pulp and invade its superficial and deeper parts leading to lamellar splitting of the nail plate without causing onycholysis or subungual alteration. This characteristic mechanism of invasion of fungus usually occurs with dermatophytes that leads to endothrix-type of tinea capitis especially, *T. soudanense* and *T. violaceum*. Even though *T. tonsurans* has not been reported to cause endonyx onychomycosis, it is well known to cause distal and lateral subungual onychomycosis and endothrix type of tinea capitis. Thus, one may expect invasion of the nail plate causing endonyx onychomycosis. Clinically, this state is characterized by diffuse milky white discoloration of involved nail. The affected nail in endonyx onychomycosis does not show clinical signs of inflammation in the nail bed, such as onycholysis and subungual hyperkeratosis, which is in contrast to distal and lateral subungual onychomycosis.⁷ In spite of the milky color, endonyx type can be differentiated from superficial white onychomycosis by the presence of normal surface of the nail plate. Tosti et al. reported endonyx onychomycosis caused by *T. soudanense* in three cases.⁸ Nail biopsy specimens showed extensive fungal invasion through the nail plate without inflammation of the nail bed. *T. violaceum* has also been documented to cause the same clinicopathological features.⁸ Our case demonstrated the

classic nail lesion of endonyx onychomycosis, showing milky white discoloration in the nail plate without nail surface change therefore, superficial white onychomycosis was excluded. Unfortunately, the nail biopsy was not performed to reveal the histopathological changes in this case; but, the positive fungal culture from the affected nail confirmed *T. soudanense*.

Lamb and Rademaker have reported 68 isolates of *T. violaceum* and *T. soudanense* from 60 patients in Hamilton, New Zealand. Most of these patients had migrated from East Africa. Eight of them had tinea corporis due to *T. Magill* et al, reported a recent increase in recovery of *T. violaceum* and *T. soudanense* from skin, hair and nail specimens from Baltimore, Maryland, USA. These dermatophytes have only sporadically been reported from US previously. They attributed this rise to increasing immigration of African born individuals to that area thus changing population demographic affecting epidemiology of this organism.⁵ In this case the patient was successfully treated with Itraconazole 200mg twice daily for first seven days of every month for three months which was similar to the recent case report by Nenoff P et.al in which after 8 weeks oral fluconazole therapy, the dermatomycoses of skin, scalp, and thumbnail of two children caused by *T. soudanense* were completely healed.⁹

4. Conclusion

Our findings provide evidence for the ongoing evolution of dermatophytosis epidemiology related to international travel and shifts in population demographics. In the era of economic liberalization, when people have started travelling abroad more frequently, isolation of uncommon dermatophytes can occur anywhere in the world and medical microbiologist should keep themselves updated in diagnosing such isolates. It has been suggested that *T. soudanense* is more closely related to *T. rubrum* through microsatellite diversity. These evolutionary relationships are interesting and important in explaining the unexpected isolation of *T. soudanense* in nonendemic regions of the world. The introduction of traditionally geographically confined pathogens to areas where they are not endemic will continue to occur and may in some circumstances have important implications for proper diagnosis and treatment as well as disease control.

5. Source of Funding

None.

6. Conflict of Interest

The authors declare that there is no conflict of interest

References

- Rippon JW. Medical Mycology: The pathogenic fungi and the pathogenic actinomycetes. Philadelphia: W.B. Saunders; 1988.
- Sahai S, Mishra D, Tripathi P. Rare isolation of Trichophyton soudanense from three cases of superficial mycoses in Lucknow, India. *Indian J Pathol Microbiol.* 2010;53(4):896-7. doi:10.4103/0377-4929.72051.
- Patwardhan N, Dave R. Dermatophytosis in and around Aurangabad. *Indian J Pathol Microbiol.* 1999;42:455-62.
- Kwon-Chung KJ, Bennett JE. Medical Mycology. Philadelphia: Lea and Febiger; 1992.
- Magill SS, Manfredi L, Swiderski A, Cohen B, Merz WG. Isolation of Trichophyton violaceum and Trichophyton soudanense in Baltimore, Maryland. *J Clin Microbiol.* 2007;45(2):461-5. doi:10.1128/jcm.02033-06.
- Baran R, Hay RJ, Tosti A, Haneke E. A new classification of onychomycosis. *Br J Dermatol.* 1998;139(4):567-71. doi:10.1046/j.1365-2133.1998.02449.x.
- Tosti A, Baran R, Piraccini BM, Panti PA. A new modality of nail invasion by dermatophytes. *Acta Dermato-Venereologica.* 1999;79(1):52-3. doi:10.1080/000155599750011714.
- Sagher F. Histologic examinations of fungus infections of the nails. *J Invest Dermatol.* 1948;11:337-57.
- Nenoff P, Kruger C, Schulze I, Koch D, Rahmig N, Hipler U, et al. Tinea capitis and onychomycosis due to Trichophyton soudanense: Successful treatment with fluconazole-literature review. *Der Hautarzt.* 2018;69(9):737-50.

Author biography

Sana Islahi, Assistant Professor

Anupam Das, Professor (Jr)

Abhilash Chandra, Professor (Jr)

Manodeep Sen, Professor

Jaya Garg, Associate Professor

Kirti Maurya, Senior Resident

Jyotsna Agarwal, Professor & Head

Cite this article: Islahi S, Das A, Chandra A, Sen M, Garg J, Maurya K, Agarwal J. Endonyx onychomycosis due to *Trichophyton soudanense*: Rare case with successful treatment. *Indian J Microbiol Res* 2021;8(1):93-95.