



## Case Report

# Achondroplasia and emergency caesarean section: A case report

Urmila Palaria<sup>1,\*</sup>, Kamal Nayan Joshi<sup>1</sup>, Yeeti Upreti<sup>1</sup>

<sup>1</sup>Dept. of Anaesthesiology, Critical Care, Pain & Palliative Medicine, Government Medical College, Haldwani, Uttarakhand, India



### ARTICLE INFO

#### Article history:

Received 14-02-2020

Accepted 06-08-2020

Available online 15-03-2021

#### Keywords:

Achondroplasia

Dwarfism

Spinal anesthesia

Caesarean section

### ABSTRACT

**Background:** Achondroplasia is the commonest variety of rhizomelic dwarfism, which results from abnormal cartilage formation at epiphyseal growth plates. The peculiar facial features, bony deformities and systemic abnormalities often pose a difficulty in administration of anesthesia, particularly in the parturients. There are very few reported cases of spinal anesthesia in achondroplastic parturients, because of its feared high risks.

**Case Report:** We reported, two cases of achondroplastic parturients with short stature, planned for emergency lower segment caesarean section (LSCS), in view of cephalo-pelvic disproportion under spinal anesthesia.

**Conclusion:** We discussed the anesthetic issues to achondroplastic parturients and finally did under spinal anesthesia. Besides, a myriad of problems encountered in these patients warrant a careful pre-anesthetic evaluation to warrant patients' safety and affirmative procedure outcomes.

© This is an open access article distributed under the terms of the Creative Commons Attribution License (<https://creativecommons.org/licenses/by/4.0/>) which permits unrestricted use, distribution, and reproduction in any medium, provided the original author and source are credited.

## 1. Introduction

Achondroplasia is a form of short-limbed dwarfism. Regardless of the literal meaning of word achondroplasia "without cartilage formation", the cartilage formation is not a problem in these patients but its ossification is; particularly in the long bones of the arms and legs. Achondroplasia is the commonest form of rhizomelic dwarfism.<sup>1</sup> The mutations of fibroblast growth factor receptor 3 (FGFR3), results in diminished chondrocyte proliferation in the epiphyseal growth plate which leads to formation of small tubular bones.<sup>2</sup> It is an autosomal dominant disorder, although the majority of cases are sporadic, with female preponderance and an incidence of 1 per 15000-40000 live births.<sup>3</sup>

These achondroplastic people are short statured with an average height of about 4 feet in adult person but with normal intelligence. Their characteristic features include, an average-size trunk with short arms and legs, with limited range of motion at the elbows, and macrocephaly with a

prominent forehead. Fingers are short and the ring finger and middle finger may diverge, giving the hand a trident appearance.

It is really a great challenge to Anesthesiologists to administer anesthesia, due to the peculiar facial features, bony deformities and systemic abnormalities, particularly in the parturients. Anesthetic management in pregnant achondroplastic patients is difficult, owing to abnormal airway findings and co-existing deformities of vertebral column, which are further aggravated by the stress of pregnancy on body anatomy and physiology.

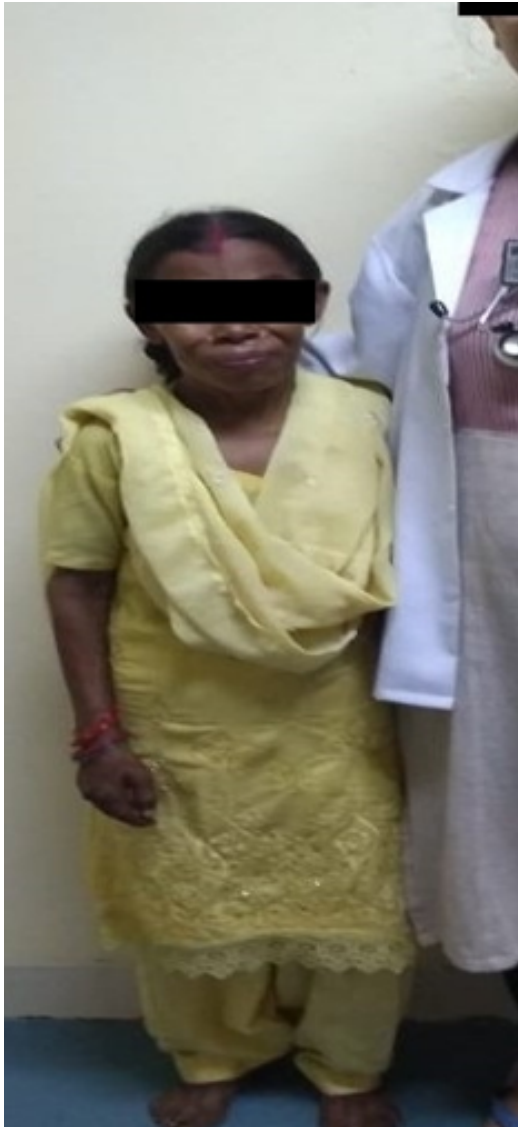## 2. Case Report 1

A 27 year G3P1L1A1 achondroplastic parturient (weight 41 kg, height 107cm) with 37-weeks of pregnancy, presented for emergency caesarean section for cephalo-pelvic disproportion with foetal distress. She had an unremarkable course of pregnancy and had no significant previous medical history. Her airway examination revealed bucked upper incisors and was placed in Mallampati grade

\* Corresponding author.

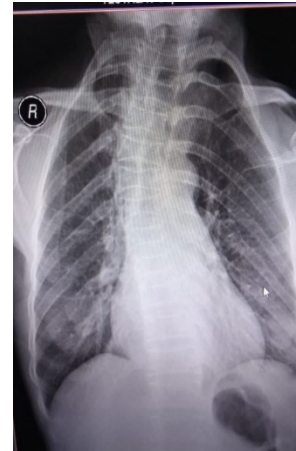
E-mail address: [urmila\\_palaria@rediffmail.com](mailto:urmila_palaria@rediffmail.com) (U. Palaria).

II. Her systemic examination was within normal limits except for mild thoracic kyphosis and scoliosis. (Figure 1 and Figure 2) Her preoperative baseline investigations were within normal limits.



**Fig. 1:** The short stature of achondroplastic female patient as compared to a female of normal stature

Chest X-ray of our patient showing thoracic scoliosis. In the operating room, all routine sensors were attached to monitor for pulse oximetry (SpO<sub>2</sub>), non-invasive blood pressure (NIBP), and electrocardiogram (ECG) and end tidal carbon dioxide (EtCO<sub>2</sub>). She was preloaded with 500 ml normal saline and aspiration prophylaxis with Inj Pantoprazole 40mg and Inj Metoclopramide 10mg was given. She was placed in the left lateral position and subarachnoid block was given with 1.8 ml of 0.5% bupivacaine (heavy), via 26 G Quincke's needle at L3-L4 interspace after confirming free flow of cerebrospinal fluid.



**Fig. 2:** Chest X-ray of our patient showing thoracic scoliosis.

Sensory analgesia up to T6 dermatome was achieved and surgery was commenced.

A male infant with normal phenotype, weighing 2.4 kg was delivered after 10 min, with APGAR score was 7 and 9 at 1 and 5 minutes.

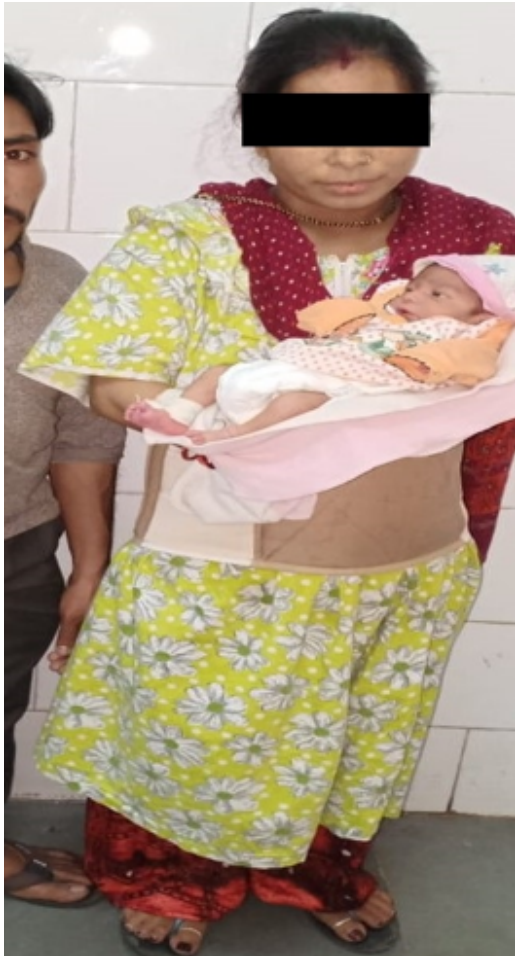### 3. Case Report 2

A 32yr old G2P1L1 achondroplastic parturient presented for an emergency caesarean section for 38-weeks of gestation with foetal distress with previous LSCS. On pre-anaesthetic assessment, past history was insignificant. Her family history was suggestive of similar short statured condition in her parents and her sister. Patient had a large head, short neck and short statured with a height of 110 cm and weight 45 kg. She had a large head with frontal bossing, a saddle nose and short neck. Her airway examination showed full range of neck movement, large mandible and tongue hence she was placed in Mallampati grade II. Examination of spine revealed thoracic scoliosis with pregnancy induced lumbar lordosis. (Figure 3) In the operating room, spinal anaesthesia was given using standard technique and surgery commenced. A 2.2 kg male child was delivered after 10 min, with Apgar scores of 7 and 9 at 1 and 5 minutes, respectively.

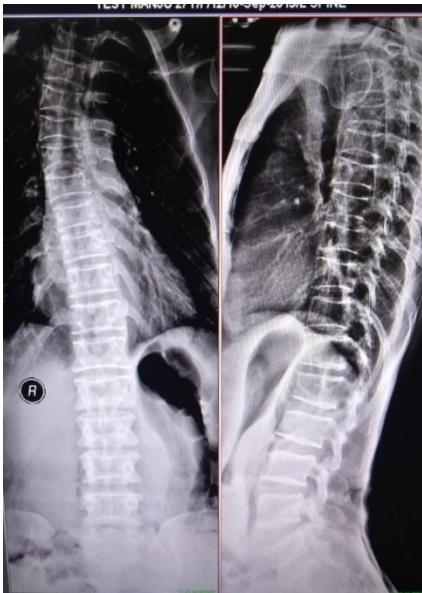Both the patients were stable throughout the intraoperative period, with an estimated blood loss of around 800 ml. At the end of the procedure patients were shifted to the post anaesthesia care unit (PACU). After an uneventful postoperative period, both the patients were discharged from the hospital 5 days later.

### 4. Discussion

Achondroplastic females characteristically have low fertility rate and those who do conceive, often require caesarean section because of cephalo-pelvic disproportion. The most common mode of delivery in achondroplastic parturients is



**Fig. 3:** The second patient with her achondroplastic husband



**Fig. 4:** Chest X-ray of our patient showing thoracic scoliosis and lumbar lordosis

an elective caesarean section due to pelvic abnormalities.<sup>4</sup> Placement of peripheral venous lines and arterial catheters may be difficult in these patients; owing to lax skin and excess subcutaneous tissues.<sup>5,6</sup>

These cases are difficult to manage peri-operatively and often pose a challenge to the attending anaesthesiologist. Selection of anesthetic modality is often a dilemma and requires consideration of various factors as mentioned below.

Securing airway, in particular, is risky in these patients due to the abnormal airway anatomy and might present as difficult airway during general anesthesia. Limited neck extension, foramen magnum stenosis, a large tongue, large mandible, and atlanto-axial instability can lead to increased difficulty of airway management can lead to difficult mask ventilation, difficulty in glottic opening visualisation and difficult intubation due to narrow nasal passages and nasopharynx.<sup>5,7,8</sup>

Cardiopulmonary problems are common in these patients (restrictive lung diseases, pulmonary hypertension, cor pulmonale etc.).<sup>9</sup> Restrictive lung disease presents at an early age due to thoracic dysplasia (rib hypoplasia), thoracic lordosis and thoracic kyphoscoliosis<sup>1,10,11</sup> and might necessitate further examinations.<sup>9</sup>

Achondroplastic dwarfs often develop neurological complications due to their bony deformities.<sup>12</sup> As far as neuraxial regional anesthesia is considered, it is also technically difficult in these patients because of anatomical abnormalities like narrow spinal canal/stenoses, reduced epidural space, kyphoscoliosis and vertebral body deformities. Any pre-existing neurological abnormalities must have to be documented, particularly before a planned regional anesthesia procedure.<sup>13</sup>

In addition to this, the known physiologic changes in pregnancy including enlarged breast, airway edema, upper airway capillary engorgement, aorto-caval compression due to a gravid uterus, expanded plasma volume and increased consumption of oxygen can considerably complicate the health status of such patients.<sup>14</sup>

Epidural anesthesia is a safer choice as compared to the spinal anesthesia because it allows titration of dose of local anesthetic agent. But there can be adverse events like accidental dural punctures, difficulties in advancing the catheter, increased risk of venous puncture, irregular or unpredictable (unpredictably high) spread of anesthesia.

That's why, sub arachnoid block is supposed to be a relatively better option for lower abdominal and lower limb surgeries in achondroplastic patients. It is easy to administer with slightly less steep learning curve, gives 100% profound block with a predictable level of block and is relatively safer for the patient of all adult age groups.

## 5. Conclusion

In spite of these possible difficulties, we were able to successfully manage the case in spinal anesthesia. Our objective was to minimize peri-operative complications while deciding the best course of management, for both maternal and neonatal well being. We concluded that the choice of anesthetic technique depends upon patient's factors and the anesthesiologist expertise. Besides, a multitude of problems encountered in such patients necessitates a careful pre-anesthetic evaluation to warrant patients' safety and affirmative outcomes. In our opinion, spinal anesthesia can be a tangible option for caesarean section in achondroplastic parturients.

## 6. Conflict of Interest

The authors declare that they have no conflicts of interests.

## References

- Shiang R, Thompson LM, Zhu YZ, Church DM, Fielder TJ, Bocian M. Mutations in the transmembrane domain of FGFR3 cause the most common genetic form of dwarfism, achondroplasia. *Cell*. 1994;78(2):335–42. doi:10.1016/0092-8674(94)90302-6.
- Aviezer D, Golembo M, Yayon A. Fibroblast Growth Factor Receptor-3 as a Therapeutic Target for Achondroplasia - Genetic Short Limbed Dwarfism. *Curr Drug Targets*. 2003;4(5):353–65. doi:10.2174/1389450033490993.
- Orioli IM, Castilla EE, Barbosa-Neto JG. The birth prevalence rates for the skeletal dysplasias. *J Med Genet*. 1986;23(4):328–32. doi:10.1136/jmg.23.4.328.
- Hunter AG, Bankier A, Rogers JG, Sillence D, Scott CI. Medical complications of achondroplasia: a multicentre patient review. *J Med Genet*. 1998;35(9):705–12. doi:10.1136/jmg.35.9.705.
- Monedero P, Garcia-Pedrajas F, Coca I, Fernandez-Liesa JI, Panadero A, de los Rios J. Is management of anesthesia in achondroplastic dwarfs really a challenge? *J Clin Anesth*. 1997;9(3):208–12. doi:10.1016/s0952-8180(97)00033-0.
- Mayhew JF, Katz J, Miner M, Leiman B, Hall ID. Anaesthesia for the achondroplastic dwarf. *Can Anaesth Soc J*. 1986;33(2):216–21. doi:10.1007/bf03010834.
- Hunter AG, Bankier A, Rogers JG, Sillence D, Scott CI. Medical complications of achondroplasia: a multicentre patient review. *J Med Genet*. 1998;35(9):705–12. doi:10.1136/jmg.35.9.705.
- Huang J, Babins N. Anesthesia for cesarean delivery in an achondroplastic dwarf: A case report. *AANA J*. 2008;76(6):435–6.
- Anesthesia recommendations for patients suffering from Achondroplasia. Available from: <https://www.orphananesthesia.eu/en/rare-diseases/published-guidelines/achondroplasia/671-achondroplasia.html>.
- Brimacombe JR, Caunt JA. Anaesthesia in a gravid achondroplastic dwarf. *Anaesth*. 1990;45(2):132–4. doi:10.1111/j.1365-2044.1990.tb14278.x.
- Stokes DC, Phillips JA, Leonard CO, Dorst JP, Kopits SE, Trojak JE, et al. Respiratory complications of achondroplasia. *J Pediatr*. 1983;102(4):534–41. doi:10.1016/s0022-3476(83)80180-2.
- Waltz LF, Finerman G, Wyatt GM. Anaesthesia for dwarfs and other patients of pathological small stature. *Can Anaesth Soc J*. 1975;22(6):703–9. doi:10.1007/bf03013319.
- Morrow MJ, Black IH. Epidural anaesthesia for caesarean section in an achondroplastic dwarf. *Br J Anaesth*. 1998;81(4):619–21. doi:10.1093/bja/81.4.619.
- Beilin Y, Leibowitz AB. Anesthesia for an achondroplastic dwarf presenting for urgent cesarean section. *Int J Obstet Anesth*. 1993;2(2):96–7. doi:10.1016/0959-289x(93)90087-x.

## Author biography

**Urmila Palaria**, Professor

**Kamal Nayan Joshi**, PG Junior Resident 2nd Year

**Yeeti Upreti**, PG Junior Resident 1st Year

**Cite this article:** Palaria U, Joshi KN, Upreti Y. Achondroplasia and emergency caesarean section: A case report. *Indian J Clin Anaesth* 2021;8(1):129-132.