



Original Research Article

Efficacy of amniotic membrane graft in ocular surface disorders

Rani Sujatha M A¹, Varsha A^{1,*}¹Dept. of Ophthalmology, Dr. B R Ambedkar Medical college, Bengaluru, Karnataka, India

ARTICLE INFO

Article history:

Received 05-03-2020

Accepted 15-04-2020

Available online 30-09-2020

Keywords:

Amniotic membrane transplantation

Ocular surface disorders

ABSTRACT

Amniotic membrane transplantation is the newest approach to limbal stem cell transplantation for the reconstruction of ocular surface disorders. Amniotic membrane grafting helps in promoting epithelialisation, decreasing inflammation and suppressing fibrosis.

Purpose: To evaluate the use of amniotic membrane graft in patients coming to Dr B.R. Ambedkar Medical college OPD and IPD with various ocular surface disorders.

Materials and Methods: The prospective interventional study was conducted over a period of 18 months from June 2017 to November 2018 at DR. B. R. Ambedkar medical college and hospital, Bengaluru.

A total of 46 eyes of 46 patients were taken into the study. Consecutive patients with ocular surface disorders including primary pterygia and chemical injury underwent amniotic membrane transplantation and were followed for 6 months.

Results: In our study, 46 patients were enrolled including 26 males and 20 females with mean age of 43.3 +/- 12.97 years. Of these, there were 40 patients with Pterygium (87%), 6 patient's had chemical burn (13%). Out of 40 cases with primary pterygium, 35 cases (87.5%) showed no recurrences at the 6th month of follow up, 5 cases (12.5%) showed superficial vascularisation and re-growth upto 2mm crossing the limbal margin. The recurrence was early in two cases (5%) and late in three cases (7.5%). Out of 6 cases with chemical injury, 4 patients (66.6%) had successful outcome.

Conclusion: Amniotic membrane transplantation is a safe and effective surgical technique for ocular surface disorders.

© 2020 Published by Innovative Publication. This is an open access article under the CC BY-NC license (<https://creativecommons.org/licenses/by-nc/4.0/>)

1. Introduction

Amniotic membrane transplantation is a recent approach for the reconstruction of ocular surface disorders. Amniotic membrane grafting helps in promoting epithelialisation, decreasing inflammation and suppressing fibrosis. Ocular surface disorders such as pterygium, chemical injuries, persistent corneal epithelial defects, conjunctival defects after removal of the ocular surface tumours, ocular cicatricial pemphigoid and Stevens–Johnson syndrome can be managed using amniotic membrane graft transplantation.

2. Aim of the Study

To evaluate the use of amniotic membrane graft in patients coming to Dr B.R. Ambedkar Medical college OPD and IPD with various ocular surface disorders.

3. Materials and Methods

A prospective interventional study was conducted from June 2017 to November 2018 at DR. B. R. Ambedkar Medical College and Hospital, Bangalore.

A total of 46 eyes of 46 patients were taken into the study. Informed consent was taken from the patients. Detailed history was taken and best corrected visual acuity, slit lamp examination, intraocular pressure with Goldman Applanation Tonometry, fundus examination using indirect ophthalmoscopy was done.

* Corresponding author.

E-mail address: varsapars@gmail.com (Varsha A).

Patients were enrolled in the study if they satisfied the following criteria:

3.1. Inclusion criteria

1. Age 18 to 75 years.
2. Primary progressive pterygium.
3. Chemical injury.

3.2. Exclusion criteria

1. Other ocular surface problems
2. Uncontrolled systemic illness.

Preserved amniotic membrane obtained from the eye bank was used for transplantation.

3.3. Amniotic membrane graft preparation

An informed consent was taken from donor undergoing caesarian section. Donor was screened to exclude risk of transmissible infections such as HIV, syphilis, Hepatitis B and Hepatitis C.

Under sterile condition amniotic membrane is thoroughly cleaned until the blood stain were removed with sterile Earle's balanced saline solution containing 50mg/ml of penicillin, 50mg/ml of streptomycin, 100mg/ml of neomycin and 2.5mg/ml of amphotericin. The amnion is separated from the chorion and placed with the epithelium side up on a nitrocellulose paper. The nitrocellulose paper is then cut in pieces 4 × 4 centimeters and stored at -80 degree Centigrade in a sterile vial containing Dulbecco's modified Eagle medium and glycerol in the ratio 1:1. From the preservation medium it is taken and when it obtained the room temperature, it was transferred to the surgical site.

4. Results

1. Mean age of study patients:

a) Age incidence

In our study, 46 patients were enrolled. Of these total there were 40 patients with Pterygium (87% of the total), 6 patient's had chemical burn (13%).

Table 1:

Category	No.of patients	Percentage (%)
Overall	46	
Pterygium	40	87%
Chemical injury	6	13%

Out of 40 cases, 35 cases(87.5%) showed no recurrences at the 6th month of follow up, 5 cases (12.5%) showed superficial vascularisation and re-growth upto 2mm crossing the limbal margin. The recurrence was early in two cases (5%) and late in three cases (7.5%).

3. Comparison of parameters in patients who underwent amniotic membrane transplantation for pterygium and

Table 2:

Category	No.of patients	Mean age	Range (Years)
Overall	46	46.5	18 to 75
Pterygium	40	44.5	20 to 69
Chemical injury	6	46.5	18 to 75

The mean age was 43.3 +/- 12.97 years.

Table 3: Surgical outcome in patients/ eyes with pterygium

Clinical details		Excision with AMG	Percentage
No. of eyes		40	
Affected eye	Right	19	47.5
	Left	21	52.5
Affected side	Nasal	40	100
	Temporal	0	0
	II	34	85
Grade	III	6	15
	IV	0	0
Duration (months)	Mean	9.4 +/- 7.4	
	Range	2 to 36	
Un successful outcome	Early recurrence	2	5
	Late recurrence	3	7.5
	Complication	0	0

chemical injuries.

35 patients with pterygium and 4 patients with chemical injury had successful outcome.

Table 4:

Parameter		Amniotic membrane transplantation	
		Pterygium	Chemical injury
Total No.		40	6
Age (Years)	Mean	46.5	44.5
	Range	20-69	18-75
Gender	Male	21	5
	Female	19	1
Outcome	Successful	35	4
	Unsuccessful	5	2

5. Discussion

In 1940, de Roth first described amniotic membrane transplantation and later in 1946, Sorbsy used amniotic membrane for conjunctival reconstruction for symblepharon or chemical burns. Lee et al. proposed the effect of amniotic membrane transplantation for the management of epithelial defects with corneal ulcer.¹ Thereafter, amniotic membrane transplantation was used to treat patients with pterygium, conjunctival reconstruction and other ocular

surface disorders with good results.

David et al.(2000) performed amniotic membrane graft for primary pterygium in 80 eyes of 71 patients. These workers concluded that amniotic membrane graft is successful and preferred grafting method for primary pterygium.²

In the current study, amniotic membrane transplantation was found efficacious in treatment of primary pterygium in 35 (87.5%) of 40 eyes. These results correlates to those of Pinnata et al., who achieved success in 89% of patients.³

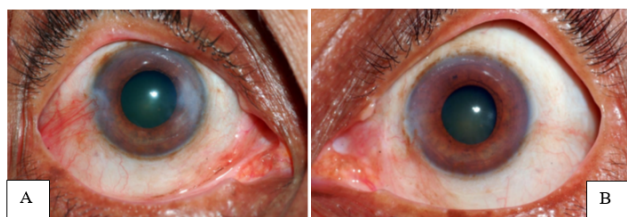


Fig. 1: A: Primary pterygium; **B:** Post amniotic membrane graft

Prabhasawat et al. reported that the recurrence rate after performing amniotic membrane transplantation on 46 eyes with primary pterygium and 8 with recurrent pterygium, was 10.9%, 37.5% and 14.8% for primary, in contrast, primary closure on 20 eyes with primary pterygium yielded a recurrence rate of 2.6%, 9.1% and 49%.⁴ The results of this study and our study suggests that amniotic membrane transplantation after pterygium excision is a safe and efficient procedure with lower recurrence rate.

Gomes et al., performed amniotic membrane transplantation for chemical injury. They concluded that amniotic membrane transplantation is effective alternative for restoration of ocular surface in chemical burns.⁵

In our study, out of 6 eyes treated for chemical injury, four eyes with Grade II Hughes classification and two eyes with Grade III. Graft was taken up by 4 eyes with grade II (66.6%) effectively with re-epithelialisation and no symblepharon. Other 2 eyes which belonged to Grade III, early degradation of membrane along with extensive corneal neovascularisation was observed in the first week of follow up.

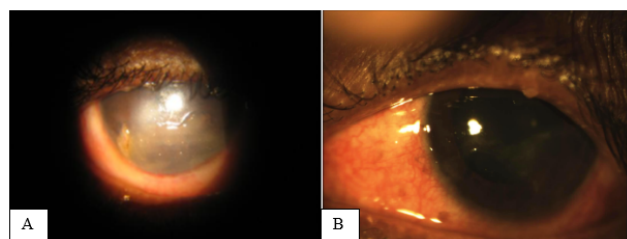


Fig. 2: A: Chemical injury; **B:** Amniotic membrane graft

6. Conclusion

In recent times, human amniotic membrane transplantation is being increasingly used for a wide spectrum of ocular surface disorders. The current study was conducted with the aim of determining the efficacy of amniotic membrane transplantation in ocular surface disorders like primary pterygium and chemical injuries. Amniotic membrane transplantation is found to be a safe and effective treatment in the management of ocular surface disorders.

7. Source of Funding

None.

8. Conflict of Interest

None.

References

1. Lee SH, Tseng CG. Amniotic membrane transplantation for persistent epithelial defects with ulceration. *Am J Ophthalmol.* 1997;123:303–12.
2. Ma DHK, See LC, Liao SB, Tsai RJF. Amniotic membrane graft for primary pterygium: Comparison with conjunctival autograft and topical mitomycin C treatment. *Br J Ophthalmol.* 2000;84(9):973–8.
3. Prabhasawat P, Tesavibul N, Komolsuradij W. Single and multilayered amniotic membrane transplantation for PED with or without stromal thinning and perforation. *Br J Ophthalmol.* 2001;85(12):1455–63.
4. Pinnata P, Barton K, Burkett G, Tseng SC. Comparison of conjunctival autografts, Amniotic membrane grafts, and primary closure for pterygium excision. *Ophthalmol.* 1997;104(6):974–85.
5. Gomes J, Santos MS, Cunha MC. Amniotic membrane transplantation for partial and total limbal stem cell deficiency secondary to chemical burn. *Ophthalmol.* 2004;110:466–73.

Author biography

Rani Sujatha M A Professor and HOD

Varsha A Post Graduate

Cite this article: Sujatha M A R, Varsha A . Efficacy of amniotic membrane graft in ocular surface disorders. *Indian J Clin Exp Ophthalmol* 2020;6(3):449–451.