

Reverse cross toe flap” from second toe for great toe tip reconstruction

Jyoshid R B

Senior Consultant, Dept. of Plastic Surgery, Sushrutha Institute of Plastic Surgery, Elite Mission Hospital, Thrissur, Kerala, India

*Corresponding Author: Jyoshid R B

Email: drjosh4u@gmail.com

Abstract

Reconstruction of the great toe is a challenging treat for any reconstructive surgeon. The goal of reconstruction is a good functional and aesthetically appealing reconstruction of the great toe tip. We report a 10 year old girl presented to us with right great toe tip defect with exposed distal phalanx. We reconstructed the defect with a “reverse cross toe flap” from the second toe. According to the authors best knowledge this is the first reported case of “reverse cross toe flap” for toe reconstruction.

Keywords: Great toe tip, Cross toe flap, Reverse cross toe flap, Reconstruction.

Introduction

The great toe has a major role in the function of the foot with impact on both aesthetic and psychological aspect of the individual. The location of the great toe is in the distal most part of the foot, without much flexibility. The options for the reconstruction of the tip of the great toe are limited. Unlike the great toe, the thumb tip reconstruction has multiple options due to its location and flexibility. The local options of reconstruction are plenty along with microsurgical options in case of thumb reconstruction. The microsurgical options of great toe are utilized when the defect size is more. The local flaps in the form of reverse metatarsal flap, reverse medial plantar artery flap are also utilized when the defect size is fairly large. In case of small distal tip defect around a centimeter size the reverse flaps looks overdoing and the feasibility of microsurgery looks less feasible especially post toe pulp harvest from the great toe. Even though the ante-grade cross toe flap is a described entity, the reach of the flap is limited especially for the distal tip defect. In such scenario the reverse cross toe flap from the second toe is a very good option for reconstruction. To the authors best knowledge this is the first reported case of a “reverse cross toe flap” for the great toe reconstruction.

Case Report

Our patient is a 10 years old girl presented to the emergency services with history of great toe injury sustained by fall of heavy object. Clinical examination revealed a defect of size 2X1.5 cm on the right great toe tip. There was exposed distal phalanx with partial nail bed loss (Fig. 1 A). The reconstructive option of “reverse cross toe flap” was planned in reverse. The distal most part of the flap was extending in to the first web space (Fig. 1 B). The flap markings were done and the elevation started in the web space including the digital artery along the axis of the flap. Inclusion of the digital vessel makes the flap axial flap. The elevation was continued distal to the distal inter-phalangeal joint where the cross anastomosis to the contralateral digital artery was visible. The inset of the flap was given without tension (Fig. 1 C). The donor site was closed primarily. The total duration of the surgery was one and half hours, and the surgery was done

under ankle block and under tourniquet control. The division of the flap was done in the third postoperative week. We could achieve good aesthetically impressive result without functional morbidity (Fig. 1 D). Diagrammatic representation of the flap planning (Fig. 2).

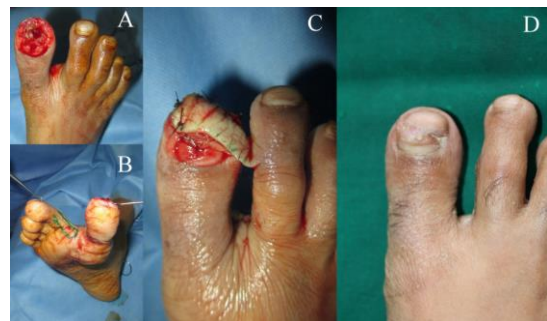

Fig. 1: A. Pre-operative photograph showing, great toe tip defect with exposed bone and partial nail bed loss. B. Flap markings showing the reverse direction and extension into the web space. C. Flap inset without tension reaching to the distal medial toe tip. D. Two months post op photograph showing well settled flap.

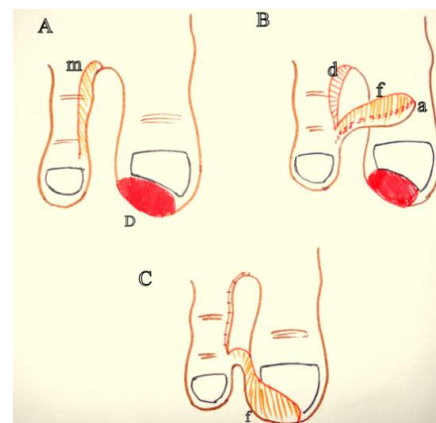


Fig. 2: A- Flap marking (m). (D- Defect). B- Elevated flap (f) with its artery (a) along the axis of the flap and donor defect d. C- Flap inset and the donor site closed primarily.

Discussion

The first reported case of the cross toe flap was way back in 1979 by Hamilton R B.¹ He used cross toe flap from second toe to cover the post free toe pulp flap great toe defects. He used the medially based flap from the second toe as the usual cross finger flap with the donor defects closed by means of skin grafting. In 1981 Hait G² used the medially based cross toe flap to cover the plantar aspect of the great toe defect with donor defect covered with skin grafting. The planning of the flap on the medial aspect like usual cross finger flap results in restriction of reach of the flap to the distal most part of the great toe. In our case the flap was elevated along with its blood supply and placing the axis along the digit makes the reach of the flap to the distal most part of the great toe. The inclusion of the vessel in the flap makes it amenable to take a fairly big flap based on its axially.

Homodigital reverse flow island flap for great toe defects are already been described in literature. Niranjana NS et al described this flap for distal great toe defects with success.³ The advantage of this procedure is that it is a single stage surgery. Demitras Y et al⁴ had tried these flaps in diabetic patients with plantar side defects. The use of homodigital reverse flow flap is impossible after toe pulp harvest. In our case the flap blood supply is based on the second toe which makes the flap amenable in reconstruction post toe pulp defects. Free tissue transfer has been advocated in great toe reconstruction for fairly big defect.⁵ The free medial plantar artery flap is a good option for reconstruction over other free flaps due to its likeness to the plantar tissue.⁶ The local options for the great toe are the reverse dorsal metatarsal artery flap,⁷ retrograde flow medialis pedis flap⁸ and distally based first webspace flap.⁹ The main disadvantages of these flaps are ugly donor site and the chance of venous problems. Once the defect is small these flap are not advisable due to its size and practical difficulty in execution. The tissue match is also not welcome in case of these local options. In our case the tissue match is ideal since we are using the similar tissue from the webspace for the replacement. Heterodigital flap from the second toe has been used for the reconstruction of the great toe tip by Sahin C et al.¹⁰ In their experience they used the flap in a grafted great toe tip for reconstruction. Usually the length of the second toe is shorter than the great toe, so it won't be always possible to cover the distal tip of the great toe with heterodigital antegrade flap from the second toe. In our case the reach of the flap is more due to the location of the pedicle at the distal part of the second toe. The reverse cross toe flap is a very viable option for the reconstruction of the great toe tip, especially when the part of

the great toe has been used for fingertip or finger reconstruction and in smaller defects.

Compliance with Ethical Standards

The study was done in such a manner that there is no violation of ethics and the informed consent from the study subject was taken.

Conflicts of Interest

There was no conflict of interest in this study. The patient gave informed consent for the publication of the case study.

Source of Funding

None.

References

1. Hamilton RB, O'Brien BM, Morrison WA. The cross toe flap. *Br J Plast Surg* 1979;32(3):213-6.
2. Hait G. cross-toe flap. *Plast Reconstr Surg* 1982;70(1):94-5
3. Niranjana NS, Vanstralen P. Homodigital reverse pedicle island flap for reconstruction of the great toe. *Br J Plast Surg* 2000;53(6):499-502
4. Demitras Y, Ayhan S, Latifoglu O, Atabay K, Celebei C. Homodigital reverse flow island flap for reconstruction of neuropathic great toe ulcers in diabetic patients. *Br J Plast Surg*. 2005;58(5):717-9
5. Hashimoto S, Nomura S, Yamauchi S, Shimamura K, Yoshimura M. Free peroneal artery coverage of the great toe defect resulting from a wrap around flap transfer. *Microsurg* 1986;7(4):199-202
6. Jyoshid RB, Vardhan H, Anto F. Free medial plantar artery flap for the reconstruction of the great toe pulp. *J Plast Reconstr Aesthet Surg* 2014;67(6):863-5
7. Balakrishnan C, Chang YJ, Balakrishnan A, Careaga D. Reversed dorsal metatarsal artery flap for reconstruction of a soft tissue defect of the big toe. *Can J Plast Surg*. 2009;17(3):e11-2
8. Mao H, Shi Z, Yin W, Dong W, Wapner KL. Reconstruction of great toe soft tissue defect with the retrograde- flow medial pedis island flap. *Plast Reconstr Surg*. 2014;134(1):120e-7e
9. Dreant N, Balaguer T, Norat F, Dannan E, Santi PL, Lebreton E. Distally based first webspace flap for coverage of the great toe. *Injury Extra*. 2005;36:121-2
10. Sahin C, Karagoz H, Sver C, Kulahci Y, Ulkur E. Reconstruction of the great toe tip defect with a pedicled heterodigital artery flap. *Aesth Plast Surg*. 2013;37(2):421-3.

How to cite: Jyoshid RB. Reverse cross toe flap" from second toe for great toe tip reconstruction. *IP Int J Aesthet Health Rejuvenation* 2020;3(2):50-1.