



## Case Report

## A rare case report on chronic osteomyelitis of fibula in a child of 6 years

Vipin Gupta<sup>1</sup>, Ruchit Shah<sup>1,\*</sup>, Abhishek Pandey<sup>1</sup>, Danish Khan<sup>1</sup>, Shervil Ayar<sup>1</sup><sup>1</sup>Dept. of Orthopaedics, ERA's Lucknow Medical College & Hospital, Lucknow, Uttar Pradesh, India

## ARTICLE INFO

## Article history:

Received 07-10-2019

Accepted 08-11-2019

Available online 06-01-2020

## Keywords:

Osteomyelitis

Infection

Sequestrectomy

Antibiotic

## ABSTRACT

Osteomyelitis is considered to be one of the traditional diseases. It involving the extremities remains the leading cause of morbidity and disability, throughout Indian pediatric population. The chronic word referred to when osteomyelitis progresses after a few months. According to the literature review, this is the fourth reported case of chronic osteomyelitis of fibula in the paediatric age group from the Indian subcontinent. We report a case of a 6-year-old female presenting with swelling, pain and discharge from the lateral aspect of the left leg which was diagnosed as chronic osteomyelitis of fibula and, treated thoroughly with sequestrectomy and oral antibiotic therapy resulting in full symptomatic relief. After 12 months follow up period, future recurrence was not observed. Because the condition is associated with a high rate of recurrence and catastrophic consequences, early diagnosis and treatment provide a favourable outcome.

© 2019 Published by Innovative Publication. This is an open access article under the CC BY-NC-ND license (<https://creativecommons.org/licenses/by/4.0/>)

## 1. Introduction

The French physician Chassaignac first ly used the word osteomyelitis in 1852.<sup>1</sup> Osteomyelitis is characterized as a bone marrow infection and resulting inflammation usually caused by pyogenic organisms or fungi.<sup>2</sup> When left untreated, fragments of dead sclerotic cortical bone forms called sequestra and underneath it, there is a new periosteal bone formation occurs called involucrum. Numerous openings form in the involucrum called "cloaca" through which pus and sequestrum come out of the bone mostly due to the avascular nature of sequestra. Osteomyelitis may be associated with high morbidity and potential mortality. Its treatment remains challenging According to the Wald Vogel classification, it is categorized in three forms: Hematogenic, contiguous and chronic.<sup>3</sup> Acute hematogenic osteomyelitis is highly predicted in the paediatric age group with the most beginning sites being metaphysis of long bones. Notably, local symptoms are also present including infected region tenderness, rise in temperature and systemic illness. Whereas, diagnosis symptoms of subacute

or chronic osteomyelitis include sinus tracts, deformation, and instability. Chronic osteomyelitis (COM) can occur secondary to trauma or via hematogenous spread from a distant focus of infection. Herein, we report a case of chronic osteomyelitis of the fibula in 6 years old child, having a positive history of trauma and delay of 6 months, before presented to us.

## 2. Case Report

A 6-year-old female child presented to our orthopedic outpatient department, Era's medical college, Lucknow, Uttarpradesh with a chief complaint of discharge through sinus over the middle lateral aspect of the left leg since last four months. History goes back to six months when the patient fell on the ground after being moved by her fellow friends while playing in an open field. At that time, the open wound with extreme pain and swelling appeared on the left leg. The patient began to complain of fever. Then, the victim was taken to a local hospital where incision and drainage were done. The general practitioner did the local dressing on the wound. The patient was started on oral antibiotics and, was advised for daily dressings with oral antibiotics being stopped after seven days. The wound did

\* Corresponding author.

E-mail address: [ruchit.academic@rediffmail.com](mailto:ruchit.academic@rediffmail.com) (R. Shah).

not heal and, a continuous serous discharge came out from it. Acute severe pain and swelling were started over the mid-lateral part of the leg, nearly 8 days before consulting to us. Initially, the pain was insidious in onset, on and off in nature, gradually progressive, mild to moderate in intensity, eventually progressed to severe, aggravated on movements and weight-bearing and eased on after taking oral medications and rest. On general examination, all vitals were normal and, other anomalies were unremarkable. Over the antero-lateral part of the middle third of the left leg, swelling, redness with pus discharge from the sinus and scar-forming was observed on local examination. The swelling was tense and shiny (Figure 1). The local rise in temperature, as well as bony irregularity, was also observed. Laboratory investigation showed an elevated level of erythrocyte sedimentation rate (ESR) and C-reactive protein level (CRP).

A radiograph of the involved extremity demonstrating the destruction of cortex and medulla involving diaphysis and metadiaphysis of the fibula with thick periosteal reaction (Figure 2).

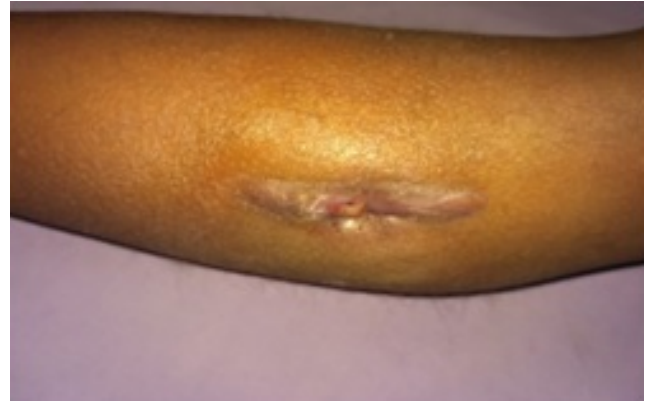A magnetic resonance imaging (MRI) was obtained, which revealed large sequestrum with secondary infective myositis was not involve tibia and adjacent joint (Figure 3).

A decision was made to operate the patient. After consent and pre-anaesthetic clearance, the fibula was laterally opened and, the free lying dead piece of sequestrum was removed with debridement and sinus tract was completely excised (Figure 4). All tissue that was dead and debrided was sent for culture sensitivity. The wound was closed with the negative suction drain in situ after extensive washing (Figure 5), which was removed 48 hours after the surgery procedure. The bony specimen was sent for histopathological examination. Culture sensitivity came out to *Staphylococcus Aureus* sensitive to cefazolin and linezolid. Histopathology findings revealed chronic inflammatory cells surrounding the necrotic bone, which proved to be chronic osteomyelitis.

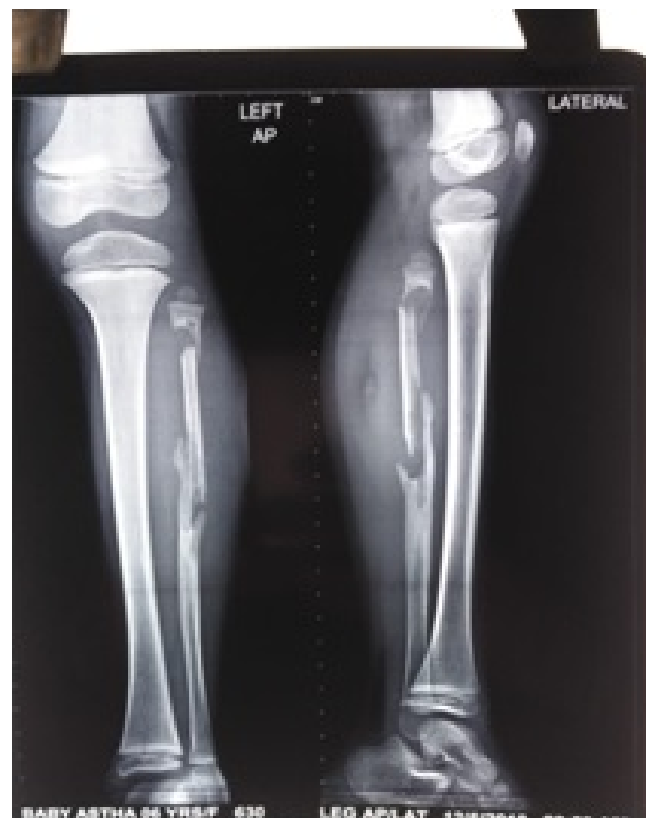The patient was treated with intravenous cefazolin of 2g i.v.q 8 hourly for 2 weeks followed by oral linezolid 600mg q12 hourly for 4 weeks. After treatment, sinus track was healed (Figure 6) and, the satisfactory improvement was observed. At 12 months follow up period, a relapse of symptoms were not observed and, she was ambulating with full weight bearing on the affected leg, having the full range of motion at the adjacent joint and had no residual deformity of the operated limb.

### 3. Discussion

COM is described as a long-standing infection of the bone, characterized by the growth of microorganisms, presence of a dead bone with surrounding unhealthy granulation tissue, inflammation and sinus discharge. Male patients were more affected than a female with a ratio of 2.7:1 and, most



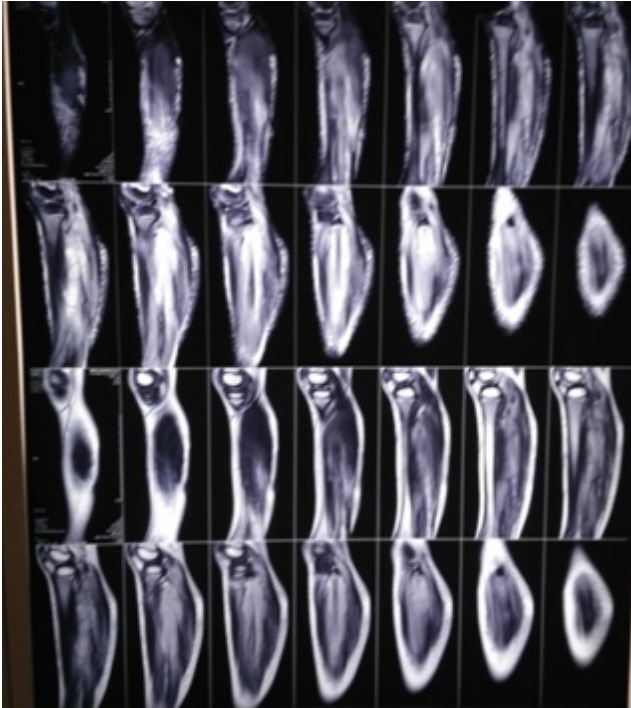
**Fig. 1:** Showing discharging sinus and scar over the lateral aspect of the leg.



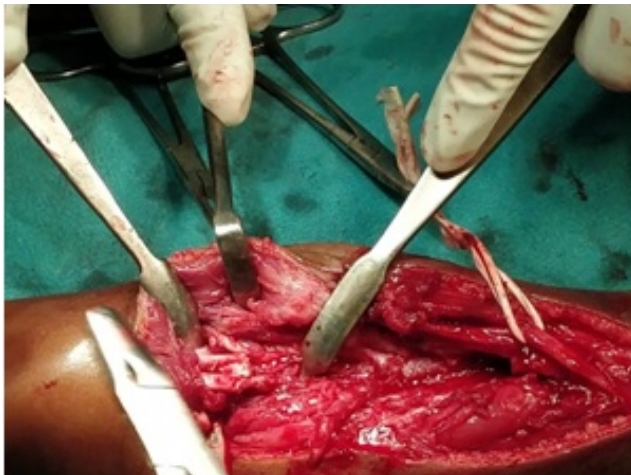
**Fig. 2:** Showing destruction of bone with thick periosteal reaction.

commonly the lower limbs with tibia, femur, calcaneus, and toes being involved. The incidence of COM in paediatric patients is around 2.9 per 1,00,000 children, and the fibula site is very rarely reported.<sup>4</sup> For developing countries, it remains a formidable problem.

After a vast literature search, it was found that only a few cases have been documented for the mentioned entity in the paediatric population. In the Indian scenario, until today, only three cases have been reported with a similar

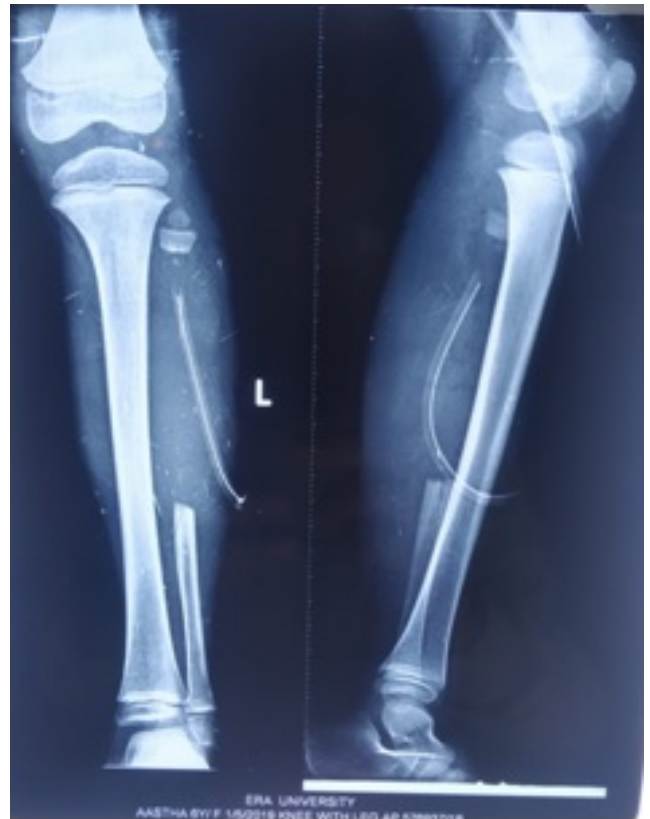

**Fig. 3:** Magnetic resonance imaging showing periosseous abscess formation with sequestra with the normal tibia and no adjacent joint involvement.

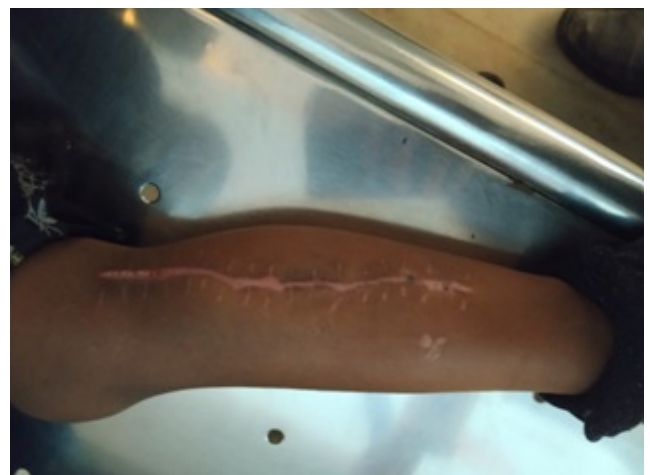

**Fig. 4:** Intraoperative photo showing the destruction of the fibula.

entity in the paediatric age group.<sup>5–7</sup> In the first reported case, a 6-year-old male child came into contact with a local shrub named Bichu grass (*Urtica Dioica*) while walking in Himalayan villages and subsequently developed cellulitis, blister formation and eventually osteomyelitis and was managed with debridement, sequestrectomy followed by an antibiotic course of 5 weeks.<sup>5</sup> In another scenario, the 8-year-old female child presented with pain and swelling over the left leg since last 6 months. She was prescribed for



**Fig. 5:** Postoperative x-ray showing drainage tube.



**Fig. 6:** Healing of sinus tract in situ.

antibiotics, yet no improvement was observed. Eventually, with debridement, removal of 13 cm long sequestrum was done followed by a course of antibiotic therapy.<sup>6</sup> In the last case, the 8-year-old male child presented with discharging sinus and granulation tissue over the lower lateral aspect of the left leg and treated with sequestrectomy along with debridement and excision of sinus tract followed by a course of intravenous and oral antibiotics.<sup>7</sup> The present case is the fourth reported case in a pediatric population from the Indian subcontinent.

A multimodal approach including history, physical examination with biochemistry and image modalities should be adopted, to properly support the diagnosis of COM. Recently; imaging modalities have emerged to provide detailed information on the state of infection. A highly elevated level of ESR and CRP are the most significant parameters in laboratory results. The value for ESR usually begins to rise at about 48-72 hours from the start of the infection process. Contrasted to ESR, CRP tends to be more reliable to monitor the treatment response as its concentration increases faster than the ESR, about six to ten hours after the onset of inflammation and returns to normal within a week of starting treatment.

A bone biopsy is a gold standard for diagnosis of COM. In the diagnosis of any osteomyelitis, isolating the causative pathogen is the most crucial step. The sample bone must be sent for aerobic, anaerobic, fungal, as well as mycobacterial cultures. The causative pathogens in osteomyelitis differ based on the age of the patient and the medical condition. *Staphylococcus aureus*, *Streptococcus agalactiae*, and *Escherichia coli* most common pathogens in infants. *Staphylococcus aureus*, *Streptococcus pyogenes*, and *Haemophilus influenzae* are most commonly isolated organisms in children more than one year of age. After age 4, the advent of *H.influenzae* as a cause of osteomyelitis has declined dramatically with the emergence of *H.influenzae* vaccine.<sup>8</sup> In the present case, the presence of *Staphylococcus aureus* was detected in laboratory findings.

Seldom, cultures of sinus tracts are not reliable to identify the causative pathogen in such situation conventional x-rays, bone scan, computed tomography as well as magnetic resonance imaging is supportive diagnostic aid. Bone destruction caused by osteomyelitis may occur after two weeks after the onset of infection can be seen in conventional x-rays. Soft tissue swelling, periosteal thickening and focal osteopenia are the typical representation observed in conventional x-rays. Computed tomography (CT) scan is particularly used to show a periosteal reaction, cortical bone destruction and presence of sequestration or involucrum if any. Besides, ring-enhancing soft tissue abscesses can also be found. MRI may be the imaging modality of choice for infections affecting the spine, pelvis, and limbs due to its ability to provide

fine details of the osseous changes and soft tissue extension in these regions. The main drawback of MRI is the high cost and requiring sedation or anaesthesia as pre-procedure for young children.<sup>9</sup> Technetium methylene diphosphonate, Tc-99 is the agent of choice for the bone scan.<sup>10</sup>

Differential diagnosis of this condition includes acute leukaemia, cellulitis, malignant bone tumours like Ewings sarcoma and osteosarcoma. With the aids of microbiological investigations like cultural sensitivity and radiological investigations such as x-rays, CT, and MRI, COM was detected at a very advanced stage before severe disability or deformity may occur. However, in our patient clinical findings of sinus discharge, high level of ESR and CRP, in radiograph the presence of sequestrum and destruction of cortex and medulla involving diaphysis and metadiaphysis of the fibula with thick periosteal reaction and chronic inflammatory cells surrounding the necrotic bone in histopathology, were all in favour of the diagnosis of COM.

COM treatment relies on appropriate antibiotic therapy and infected and necrotic tissue to be removed occasionally by surgery. Antibiotic therapy choice relies on culture and susceptibility findings. Management needs a multi-disciplinary workup of an orthopaedic surgeon, radiologist, pathologist and a microvascular surgeon. Removal of all non-viable skin, soft tissue and bone termed as radical debridement, may be quite challenging at times. Here, we performed sequestrectomy with radical debridement of non-viable soft tissue and bone with proper antibiotic coverage without bone grafting as the distal end of tibia and fibula was not involved.<sup>5</sup> At the end of 12 months follow up, the patient was full weight-bearing without any of the problems mentioned earlier.

#### 4. Conclusion

By early recognition and differentiation from other mimic conditions and, aggressive treatment of combining sequestrectomy and antibiotic therapy, COM can be treated effectively with out significant postoperative morbidity and complications.

##### 4.1. Acknowledgements

We are wholeheartedly gratitude to Mrs. Feral Daruwala for assisting with the writing of manuscripts.

##### 4.2. Abbreviations

**COM:** Chronic Osteomyelitis

**ESR:** Erythrocyte sedimentation rate

**CRP:** C-Reactive protein

**CT:** Computed Tomography

**MRI:** Magnetic Resonance Imaging

## 5. Conflicts of interest

None.

## References

1. Chassaignac E. De l'osteomyelitis. *Bull Mem Soc Chir*;1852:431–436.
2. Hunter J. A Treatise on the Blood, Inflammation and Gun-shot Wounds. *Clin Orthop Relat Res*. 1963;(28):521–567.
3. Waldvogel FA, Medoff G, Swartz MN. Osteomyelitis: a review of clinical features, therapeutic considerations and unusual aspects. *N Engl J Med*. 1970;282(4):198–206.
4. Jiang N, Ma YF, Jiang Y, Zhao XQ, Xie GP. Clinical characteristics and treatment of extremity chronic osteomyelitis in southern China: A Retrospective Analysis of 394 Consecutive Patients. *Med*. 2015;94(42):1874.
5. Singh G, Roy V. Isolated osteomyelitis of fibula following contact with *Urtica dioica* (Bichu Ghaas) in a child. *Sch J Med Case Rep*. 2014;2(4):297–298.
6. Vijay V, Srivastava N, Rastogi A, Kumar G, Srivastava S. Osteomyelitis of fibula in a child: A rare case report with a huge sequestrum. *Sch Acad J Biosci*. 2015;3(6):563–566.
7. Singh J, Kalia A, Virk J. Isolated chronic osteomyelitis of fibula in a child: A case report and review of literature. *Int J Orthop Sci*. 2017;3(4):923–926.
8. Jonghe MD, Glaesener G. Type B *Haemophilus influenzae* infections. Experience at the Paediatric Hospital of Luxembourg. *Bull Soc Sci Med Grand Duch Luxemb*. 1995;132(2):17–20.
9. Hatzenbuehler J, Thomas J. Diagnosis and Management of Osteomyelitis. *Am Fam Physician*. 2011;84(9):1027–1033.
10. Tumei SS, Tohmeh AG. Nuclear medicine techniques in septic arthritis and osteomyelitis. *Rheum Dis Clin North Am*. 1991;17(3):559–583.

## Author biography

**Vipin Gupta** Assistant Professor

**Ruchit Shah** Junior Resident

**Abhishek Pandey** Senior Resident

**Danish Khan** Junior Resident

**Shervil Ayar** Junior Resident

**Cite this article:** Gupta V, Shah R, Pandey A, Khan D, Ayar S. A rare case report on chronic osteomyelitis of fibula in a child of 6 years. *Indian J Orthop Surg* 2019;5(4):287–291.