



Case Report

An unusual case report of tardy ulnar nerve palsy following neglected fracture non-union of medial epicondyle humerus

T Bhavani Prasad¹, Sameer Chaitanya Sahini^{1,*}

¹Dept. of Orthopaedics, Andhra Medical College, Visakhapatnam, Andhra Pradesh, India



ARTICLE INFO

Article history:

Received 02-11-2019

Accepted 09-12-2019

Available online 06-01-2020

Keywords:

Tardy ulnar nerve palsy
medial epicondyle fracture non-union
ulnar nerve anterior transposition
tension band wiring

ABSTRACT

Tardy ulnar nerve palsy is a condition presented as late onset ulnar neuropathy. Most commonly occurred as a delayed complication of non-union of lateral epicondyle humerus with valgus deformity. Whereas tardy ulnar nerve palsy occurred as a complication of fracture non-union of medial epicondyle was rare and a very few cases were reported in literature. We report a case in a 15 year old boy with tardy ulnar nerve palsy after neglected fracture non-union of medial epicondyle of humerus on left side, patient presented with tingling and numbness of medial side two fingers with left hand weakness. We treated him operatively by tension band wiring and olecranon bone grafting for fracture non-union medial epicondyle of left humerus and ulnar nerve exploration and anterior transposition was also done.

© 2019 Published by Innovative Publication. This is an open access article under the CC BY-NC-ND license (<https://creativecommons.org/licenses/by/4.0/>)

1. Introduction

Tardy ulnar nerve palsy¹⁻³ is characterised by late onset ulnar neuropathy. Hunt¹ in 1916 coined the term 'Tardy Ulnar Nerve Palsy' to the late presenting ulnar nerve paralysis. Ulnar nerve originates from the medial cord of brachial plexus with nerve roots C8 & T1. At elbow it is posterior to the medial epicondyle of the humerus passed through cubital tunnel. The ulnar nerve is palpable and vulnerable to injury² at the medial epicondyle of humerus because of its peripheral location and proximity to elbow joint. When there was an anatomical disturbance of the elbow joint, then it causes stretching or irritation of the ulnar nerve, if it is continuous further without any intervention then finally it developed as ulnar nerve palsy. Fractures⁴ around the elbow joint were prime cause for tardy ulnar nerve palsy. Most commonly in the children with cubitus valgus deformity developed due to fracture non-union of lateral condyle humerus. Mouchet⁵ reported that the ulnar nerve stretched and it takes longer course at elbow in cubitus valgus deformity cases. These abnormal tensions with repeated micro movements finally cause

tension neuritis and intraneural fibrosis⁵ of the ulnar nerve. In some studies reported that children with cubitus varus deformity developed as a complication of supracondylar humerus fractures² can also cause tardy ulnar nerve palsy. Neglected fracture non-union of medial epicondyle^{4,6} without deformity seldom causes tardy ulnar nerve palsy, which was reported in very few studies. We report a tardy ulnar nerve palsy case in a 15 year old boy developed due to fracture non-union of medial epicondyle of left humerus.

2. Case Report

A 15-year-old boy presented to our clinic with complaining of pain over medial aspect of left elbow and weakness of left hand with decreased sensation in the medial side two fingers since one year. Pain, tingling and numbness were progressive in nature. Not associated with fever and no constitutional symptoms. History of trauma presents two years ago and it was treated initially by a native bone setter for a period of 2 months. Physical examination revealed tenderness over medial aspect of elbow, bony prominence on medial side and ulnar nerve sensitive to percussion. There was no thickening of nerve and there was no hypo pigmented patches. There was sensory loss over the ulnar

* Corresponding author.

E-mail address: sameerchaitanyasahini@gmail.com (S. C. Sahini).

nerve distribution of left hand and motor weakness of ulnar nerve supplied muscles of wrist and hand. His grip strength on the left side decreased compared to right. There was no cubitus varus or valgus deformity. Radiographs (x-ray) antero-posterior and lateral views shows fracture non-union of the medial epicondyle of left humerus with bony resorption (Figure 1 a). Nerve conduction studies revealed ulnar neuropathy at the level of elbow joint (Tables 1 and 2 Figure 2). We planned for surgical intervention, a curvilinear skin incision was given on medial aspect of elbow, superficial and deep fascia incised and ulnar nerve identified and exploration was performed (Figure 1 b). We transposed ulnar nerve anteriorly.² Non-union site exposed and edges were freshened and internal fixation done with tension band wiring and bone grafting also done (Figure 1c). Cancellous graft was taken from the ipsilateral olecranon bone because the size of defect was small. At 6 months follow-up period, hand grip strength was improved, 5⁰ – 140⁰ of elbow range of movements attained, pronation and supination were in normal range. Radiograph at 6 months follow-up period shows union (Figure 1d), without any instability.

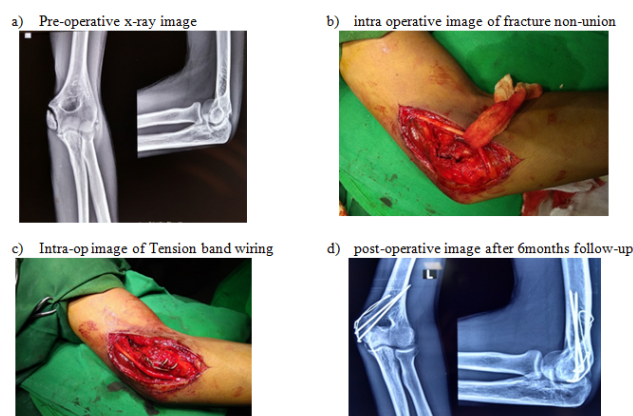


Fig. 1:

Table 1&2 : showing sensory and motor nerve conduction velocity in nerve conduction study report

Table 1: SNCV (sensory nerve conduction velocity)

Nerve	Latency (ms)	Amplitude (mm)	Distance (mm)	NCV (m/s)
Rt. Median	2.70	98.16	150.00	55.56
Rt. Ulnar	2.35	90.44	130.00	55.32
Lt. Median	2.43	90.79	150.00	61.23
Lt. Ulnar	0.00	0.00		

JAGADEESH EEG-NCV CENTER
D.NO.14-37-39/B, Beside MEDI WORLD, KRISHNA NAGAR,
VISAKHAPATNAM
Ph: 0891-6663336

EMG/NCV/EP Report

Mon Jul 30, 2018

ID: 4171
Name: Mr. L. JEEVAN
Age: Male/15y
Height/Weight: /
Dress: /
Physician: Dr. T. BHAVANI PRASAD, M.S. (Ortho)
Ref: /

Tests Performed

ICV: Rt. Median, Rt. Ulnar, Lt. Median, Lt. Ulnar
CV: Rt. Median, Rt. Ulnar, Lt. Median, Lt. Ulnar
Iv: Lt. Median, Lt. Ulnar, Rt. Median, Rt. Ulnar

Motor: Unrecordable CMAP in Left ulnar nerve
DL, CMAP amp were weak in R/L Median, (R) ulnar motor nerves

Sensory: Unrecordable SNAP in (L) ulnar sensory nerve
DL, SNAP amp were weak in R/L Median, (R) ulnar sensory

IMPRESSION:
L7 ulnar neuropathy.

Dr. K. Harish Kumar
MD, DPM, (Neuro NMB)
Asst. Professor of Gen. Medicine
K.G.H., Visakhapatnam.

Fig. 2: NCS study report

3. Discussion

Tardy ulnar nerve palsy² is caused by several pathological conditions which includes old or neglected fractures around the elbow,³⁻⁵ recurrent dislocations of the elbow, elbow arthritis, congenital anomalies and adhesions at cubital tunnel. Most commonly occurred due to delayed complications of fractures around the elbow^{3,5} among these most common is cubitus valgus deformity due to non-union of the lateral condyle fracture humerus. Ulnar neuropathy is caused by kinking, compression and stretching of the nerve and joint^{3,5} incongruities. Tardy nerve palsy infrequently occurred due to neglected fracture of medial epicondyle⁶⁻⁸ and very few literatures were reported. Patients with non-union of medial epicondyle need surgical intervention.^{6,9,10} Several factors are responsible for difficulty in surgical intervention in these cases which includes small size of bony fragment, displacement of fragment and bony resorption at non-union site and high tension and torsional forces^{8,11} due to constant pull of pronator and flexor muscles near attachment at bony fragment. In our case report the patient had injury to elbow, two years ago and initially treated by native bone setter for a period of 2 months, one year later he developed tingling, numbness of medial side two fingers and weakness of left hand, he presented to our clinic in this condition. Clinically there was no cubitus valgus or varus deformity. Radiograph (x-ray) shows the fracture non-union of medial epicondyle with bone resorption at

Table 2: MNCV (motor nerve conduction velocity)

Nerve	Latency (ms)		Amplitude (mv)			Duration (ms)			Dist. (mm)	NCV (m/s)	F-Min (ms)	F-Max (ms)
	D	P	D	P	%Dec	D	P	%Inc				
Rt. Median	3.11	7.27	27.71	26.12	5.74	9.60	11.59	20.73	270.0	64.9	25.69	30.75
Rt. Ulnar	2.59	7.99	22.32	20.33	8.92	11.40	13.28	16.49	290.0	53.7	0.06	0.06
Lt. Median	2.29	7.5	11.64	10.9	6.36	10.99	12.6	14.65	270.0	51.82	25.31	31.06
Lt. Ulnar					NaN			NaN			26.94	32.50

fracture ends. We have done surgical exploration and anterior transposition of ulnar nerve, internal fixation by tension band wiring¹⁰ to medial epicondyle and ipsilateral olecranon cancellous bone grafting done. The pins stabilize the bone and protect against rotation while the wire helps neutralize the forces from the flexor-pronator mass.¹⁰ Care was taken to make the final construct as low profile¹⁰ as possible, with the knots buried into the soft tissues along the medial humeral column above the prominence of the epicondyle.⁶ No complications related to the hardware or fixation method were observed in follow-up period. Patient's hand grip strength was improved and there was also subsidence of tingling and numbness.

4. Source of Funding

None.

5. Conflict of Interest

None.

References

1. Hunt JR. The thenar and hypothenar types of neural atrophy of the hand. *Am J Med Sci.* 1911;141:224–241.
2. James RG, Grafton L. Diagnosis and treatment of tardy paralysis of the ulnar nerve: based on a study of 100 cases. *J Bone Joint Surg.* 1947;29:1087–1097.
3. Woods GW, Tullos HS. Elbow instability and medial epicondyle fractures. *Am J Sports Med.* 1977;5:23–30.

4. Josefsson PO, Danielsson LG. Epicondylar elbow fracture in children. 35-year follow-up of 56 unreduced cases. *Acta Orthop Scand.* 1986;57:313–315.
5. Broca A, Mouchet A. Complications nerveuses des fractures de l'extre'mite' inferieure de l'humer'us. *Rev de Chir.* 1899;XIX:701.
6. Hines RF, Herndon WA, Evans JP. Operative treatment of medial epicondyle fractures in children. *Clin Orthop Relat Res.* 1987;223:170–174.
7. Duun PS, Ravn P, Hansen LB, Buron B. Osteosynthesis of medial humeral epicondyle fractures in children. 8-year follow-up of 33 cases. *Acta Orthop Scand.* 1994;65:439–441.
8. Wilson NI, Ingram R, Rymaszewski L, Miller JH. Treatment of fractures of the medial epicondyle of the humerus. *Injury.* 1988;19:342–344.
9. Smith JT, Mcfeely ED, Bae DS, Waters PM, Micheli LJ, et al. Operative fixation of medial humeral epicondyle fracture non-union in children. *J Pediatr Orthop.* 2010;30(7):644–648.
10. Shukla SK, Cohen MS. Symptomatic medial epicondyle non-union: treatment by open reduction and fixation with a tension band construct. *J Shoulder Elbow Surg.* 2011;20(3):455–460.
11. Farsetti P, Potenza V, Caterini R, Ippolito E. Long-term results of treatment of fractures of the medial humeral epicondyle in children. *J Bone Joint Surg Am.* 2001;83:1299–1305.

Author biography

T Bhavani Prasad Professor

Sameer Chaitanya Sahini MBBS, MS Ortho

Cite this article: Prasad TB, Sahini SC. An unusual case report of tardy ulnar nerve palsy following neglected fracture non-union of medial epicondyle humerus. *Indian J Orthop Surg* 2019;5(4):272–274.