



Original Research Article

Acquired perforating collagenosis: A clinico-pathological study of ten

Smita Sawant^{1,*}, Nirmala Gaikwad¹, Kalpana Hajirnis¹, Resham Vasani²¹Dept. of Pathology, K J Somaiya Medical College, Mumbai, Maharashtra, India²Dept. of Dermatology, K J Somaiya Medical College, Mumbai, Maharashtra, India

ARTICLE INFO

Article history:

Received 23-01-2019

Accepted 22-05-2019

Available online 22-11-2019

Keywords:

Acquired perforating dermatosis

Diabetes mellitus

Chronic renal failure.

ABSTRACT

Acquired perforating collagenosis, is a rare itchy, debilitating cutaneous disorder usually associated with diabetes mellitus and renal failure or both. The diagnosis is usually based on skin biopsy. The objective of our study is to review and co-relate the clinical and pathological features in acquired perforating. We present ten cases of histopathologically proven acquired perforating collagenosis, associated predominantly with diabetes mellitus. Seven out of ten patients had history of diabetes mellitus for more than ten years. Thyroid disorders were seen in three patients along with diabetes mellitus. Two had no underlying systemic diseases. Clinically skin eruptions were multiple, pruritic papules and nodules with central crust formation, located primarily on lower extremities and occasionally on back.

© 2019 Published by Innovative Publication. This is an open access article under the CC BY-NC-ND license (<https://creativecommons.org/licenses/by/4.0/>)

1. Introduction

Reactive perforating collagenosis is a rare form of cutaneous disorder characterised by transepidermal elimination of altered collagen through epidermis. It occurs in two forms. The classical one is inherited as an autosomal dominant or recessive trait. The skin eruptions are a response to superficial trauma, insect bite or exposure to cold. Koebnerization is common. Both genders are equally affected. The lesions healed spontaneously with superficial scars. The adult form, acquired perforating collagenosis is accompanied by systemic diseases like Diabetes Mellitus, renal failure, malignancy and infections.^{1,2} In recent years, it has been reported in various hepatic and endocrine disorder. It should be differentiated from other primary perforating dermatoses, namely, perforating folliculitis, elastosis perforans and Kyrle's disease. The histopathological diagnosis is primarily based on the nature of the eliminated material and the type of epidermal disruption. Patients with Acquired perforating dermatoses present with hyperkeratotic papule with central crust

formation mainly on extremities. Masson trichrome stain reveals perforating bundles of collagen extending to the surface.³ Our study describes ten patients of acquired perforating dermatoses, of which diabetes mellitus was the most commonest underlying systemic disease.

2. Aims and Objectives

1. To study and co-relate the clinical and histological features of acquired perforating dermatoses.
2. To review the literature and increase the awareness of recognition of this rare entity.

3. Materials and Materials

A retrospective study of ten skin biopsy proven, acquired perforating dermatoses, during the period of 2014 –2018 were reviewed (out of 2500 skin biopsies). All skin biopsies from Dermatology OPD received in Pathology Department, K J Somaiya hospital, sion, Mumbai were fixed in 10% formalin and step sectioned, stained with haematoxylin and eosin, Masson trichrome and van Geison. The available clinical data was retrieved and analysed.

* Corresponding author.

E-mail address: drsmita66@rediffmail.com (S. Sawant).

3.1. Inclusion criteria

All patients with clinical features of perforating cutaneous lesions were included in the study. Retrospectively, history of diabetes mellitus was noted.

3.2. Exclusion criteria

All skin biopsies other than perforating disorders were excluded in the study.

4. Results

All ten patients presented with itchy hyperkeratotic papules and nodules with central crusting, primarily in lower extremities [Table 1]. Four patients had clinical diagnosis of acquired perforating dermatoses. The differential diagnosis for two patients included perforating collagenosis, prurigo nodularis and papulonecrotic tuberculid. Kyrles disease was also suspected in other two. The lesions were predominantly seen in middle aged females. The age ranged from 28 to 65 years. The duration of the disease ranged from fifteen days to one and half year. Seven patients had diabetes mellitus for more than ten years as underlying systemic disease. Two patients had hyperthyroidism and hypothyroidism respectively, one had associated diabetes mellitus. However, their biochemical parameters were not available at the time of this study. The youngest patient had history of minor trauma with no systemic disease and the lesions healed spontaneously. All skin biopsies were diagnostic of acquired perforating dermatoses. Histologically, biopsy revealed cup shaped epidermal invagination filled with keratotic plug with perforating collagen fibres at the base the lesion were confirmed by Masson trichome stain. Verhoeff – van Gieson stain was negative for elastic fibres. The patients were treated by oral and topical retinoids.

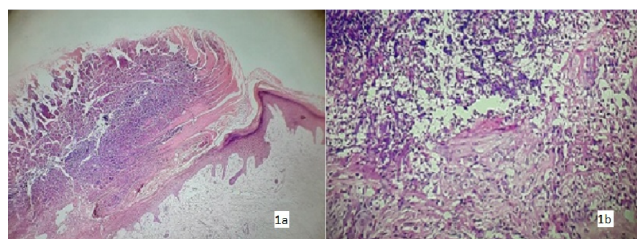


Fig. 1: Microphotograph of skin biopsy showing (a): Cup shaped epidermal invagination filled with basophilic material, (H&E, 100x). (b): Base of invagination shows perforation and inflammatory cells, (H&E, 400x).

5. Discussion

Perforating disorders are rare cutaneous lesions characterised by transepidermal elimination of altered collagen. The four classical forms are: Kyrles disease, Elastosis

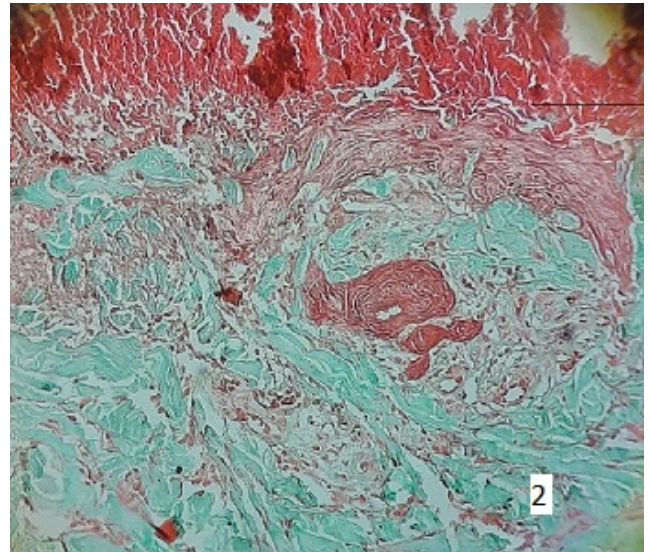


Fig. 2: (a): Altered collagen at the base of invagination, (Masson trichome, 100x). (b): Vertical collagen fibres perforating through the attenuated epidermis at the base, (Masson trichome, 400x)

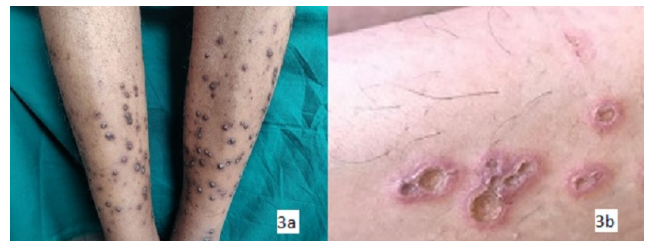


Fig. 3: (a): Acquired perforating dermatoses presenting with multiple hyperkeratotic papules or nodules on lower extremities. (b): Closer view showing umbilicated papules with central crusting

perforans, Perforating folliculitis and Reactive perforating collagenosis.⁴⁻⁶

Kyrle's disease was described by Kyrle in 1916 as "hyperkeratosis follicularis et follicularis in cutem penetrans". The skin eruptions present as numerous coalescing papules and plaques in young to middle aged individuals. It broadly overlaps clinically and histologically with other perforating disorders. The lesions are generally extrafollicular, some may involve the follicles. The histopathological findings essential for diagnosis are – (a) epidermal invagination with parakeratotic plug containing basophilic debris. (b) dyskeratotic epithelial cells (c) irregular epithelial hyperplasia (d) granulomatous inflammatory reaction (e) absence of demonstrable collagen and elastin.⁶ These findings result from disturbance of epidermal keratinisation and rapid production of abnormal keratin forming parakeratotic column which then perforates into the dermis, eliciting granulomatous reaction. The dermal connective tissue, inflammation and the keratin debris degenerate to form basophilic debris.

Table 1: Distribution of skin lesions according to age, sex and site with the clinical diagnosis and systemic disease in the present study

S. No.	Age/sex	Distribution	Clinical diagnosis	Systemic disease
1	35/F	Lower extremities	? perforating dermatosis	hyperthyroidism
2	44/F	Lower extremities back	? kyrles disease RPC	DM since 10 years, hyperthyroidism, on dialysis
3	50/F	Lower extremity	APD	DM since 10 years
4	28/F	Upper extremity	? Perforating collagenosis	NO systemic disease
5	40/F	Lower extremity	? perforating collagenosis	DM since 10 years
6	55/F	Lower extremity	APD	DM since 15 years
7	20/F	Lower & upper extremities	RPC / Prurigo nodularis / papulonecrotic tuberculid	Mild trauma
8	64/M	Lower extremity	APD	DM, hypertension, hypothyroid
9	45/F	Lower extremity, buttocks	APD	DM, hypertension
10	65/M	Lower extremity, trunk	PD	DM Since 10 years

DM: Diabetes Mellitus; RPC: Reactive Perforating Collagenosis; APD : Acquired Perforating Collagenosis; PD: Perforating Dermatoses.

Table 2: Case reports of acquired perforating dermatoses by various authors

S. No.	Authors	Age/sex	Symptom	Eruption	Common Disease
1	Satti et al (15 cases)	Middle/F	Pruritus	Papules, umbilicated nodules	DM, Renal failure
2	Kawakami T (9 cases)	Middle /F	Pruritus, koebner's	Umbilicated papules	DM
3	Faver et al (6 cases)	Middle/F	Pruritus	Umbilicated papules	DM
4	Present study (10 cases)	Middle /F	Pruritus	Umbilicated papules	DM

DM: Diabetes Mellitus

Elastosis perforans is a rare disorder more seen in males in the second decade. The papular eruptions are localised arranged in arcuate or serpiginous groups, commonly affect upper extremities, neck and face.⁷ The histological features are a narrow transepithelial channel with elimination of altered elastic fibres accompanied by inflammatory infiltrate. The epithelium is hyperplastic, but there is no degeneration of elastic fibres found. The thickened elastic fibres act as foreign bodies and are extruded through the channel as an epidermal response. Van Gieson's stain demonstrates elastic tissue in the dermal papillae.⁷

Perforating folliculitis is a relatively uncommon disorder observed in second to fourth decade. It has overlapping features of Kyrles disease. The lesions are erythematous follicular papules with central crusting. The pathologic features are (a) dilated follicular infundibulum with parakeratotic cells, basophilic material inflammatory cells and degenerated collagen (b) a portion of curled hair close to one or more follicular perforations (c) perifollicular mixed inflammatory infiltrate. It is most likely caused by irritation, and chronic rubbing resulting in abnormal follicular keratinization.

Reactive perforating collagenosis occurs in two forms – inherited seen in children and acquired forms in adults. The inherited form presents as autosomal dominant, autosomal recessive or sporadic cases and is probably caused due

to genetic abnormality of collagen in the upper dermis. The lesions heal spontaneously. Few respond well to long term oral isotretinoin as they have stabilizing effect on keratinocytes preventing damage of collagen and the epidermis.

The acquired form is seen in association with systemic diseases like diabetes mellitus, chronic renal failure, malignancies and liver disorders. The diagnosis is based on classic clinical and histological features. Clinically, they present with itchy hyperkeratotic papules or nodules with central crusting. The lesions involve primarily the extremities with or without trunk.⁷ Histologic features may vary even within different lesions from the same patient. The late stage of disease shows cup shaped invagination filled with keratotic plug admixed with parakeratotic cells and degenerated perforating collagen fibres at the base of the invagination. In our cases, vertical oriented collagen was positive by Masson trichrome while van Gieson's stain was negative for elastic fibres in the epidermis and in the crater. None of the skin biopsies reveal presence of hair in the invagination. When associated with follicles, they resemble perforating folliculitis. In absence of collagen and follicle involvement, the lesion is reminiscent of kyrles disease. However, Faver et al. proposed the following diagnostic criteria: 1) histopathologic findings of elimination of necrotic basophilic collagen tissue in a cup shaped invagination, 2) umbilicated papules or nodules with

central keratotic plug, 3) skin lesions after age of eighteen years.⁵

The pathogenesis is still unknown. However, some authors consider this disease as transepidermal elimination of histochemical altered collagen as a cutaneous response to superficial trauma.^{6,8} Thus patients of Acquired Perforating Dermatoses experience pruritus and koebner's phenomenon. In longstanding diabetes mellitus, microangiopathy along with trauma may lead to dermal necrosis and alteration in the connective tissue.⁹ Acquired perforating dermatoses has been reported in 5%-10% of patients with chronic renal failure associated with diabetic nephropathy, possibly uremic toxins, may be the causative factor. In addition an elevated serum phosphorus levels in the patients may also have a pathogenic role for the development of pruritic skin lesions. Thus, it may be considered as a cutaneous marker of chronic renal parenchymal disease in majority of the cases and increased occurrence is seen following inadequate and inefficient dialysis. Diabetic nephropathy was the most common cause associated with acquired perforating dermatoses. Non diabetic renal disorders like chronic glomerulonephritis, renal stones, renal tumors and hypertensive nephrosclerosis may also be responsible for occurrence of this disease. Our patients had long history of diabetes mellitus with no overt renal involvement. However, nephropathy could be ruled out in older patients. In the younger patient, there was no underlying systemic disease and the lesions were healed spontaneously.

Few studies have suggested overexpression of transforming growth factor increases epithelial proliferation and transepidermal elimination. Bhat et al. suggested genetic abnormality in collagen as a possible cause for inherited form of this disorder.¹⁰

At present there is no effective treatment for acquired perforating collagenosis. Symptomatic treatment includes topical corticosteroids and oral vitamin A. Other treatment modalities were systemic antihistaminics, PUVA therapy, and liquid nitrogen cryotherapy and keratolytic retinoids.¹¹

A review of literature revealed that acquired perforating dermatoses is seen in elderly patients suffering from systemic disease with classic skin eruption in the form of papules with central crusting primarily seen on extremities but also on the back and face.^{12,13} The first case reported by Mehrgan et al. Pruritus was common but koebner's phenomenon was not reported in many cases. Acquired perforating dermatosis was also triggered by minor trauma, insect bite, scabies infection. Moreover, autoimmune disorders and malignancies were also reported as co-existing diseases.¹⁴⁻¹⁶ A rare case of acquired perforating dermatoses, in absence of diabetes mellitus and renal failure, associated with oral cancer was reported.¹⁷ Others include, cutaneous neurofibroma and Addison's disease due to disseminated histoplasmosis.^{11,13} Few have suggested as a consequence of renal or peritoneal dialysis, possibly

because of disruption of vitamin and accumulation of fibronectin in the serum of uremic and diabetic patients. Clearance of acquired perforating dermatoses after renal transplant has been reported. Most of the studies describe the biochemical and immunological mechanism for transepidermal elimination of foreign material. The diagnosis was based on histopathological examination. Overlap of clinical features, such as koebnerisation or of histologic evidence of follicular involvement with or without collagen may mislead to the diagnosis of Kyrle's disease or perforating folliculitis. No specific treatment modalities have been described. Topical applications and management of underlying systemic disease were beneficial in few of the studies.¹⁵

Familial reactive perforating collagenosis reported by Bhat et al. reveals the lesion to occur in early childhood, the mean age was 5.3 years. Involvement of family members revealed autosomal dominant and autosomal recessive inheritance.¹⁰ Clinically eruptions were pruritic exhibiting koebner's phenomenon. There was no any underlying systemic disease in any of the cases reported. The common etiology was trauma and exposure to cold. A good response to oral and topical retinoids was seen. Skin biopsy had classical features of reactive perforating collagenosis which was confirmed by special stain.

Faver et al. reported association of acquired perforating dermatoses and hyperthyroidism, hypothyroidism liver disorders and neurodermatitis.⁶ They proposed diagnostic criteria for acquired perforating dermatoses. The emphasis on increasing the awareness of recognition of this entity was put forth by Satti et al.² Eight cases that met Faver's criteria were described by Kawakami et al. speculated that this disease is triggered by a cutaneous response to superficial trauma which synergistically act with vasculopathy, especially in diabetes mellitus. Acquired perforating dermatoses were also reported to be associated with oral carcinoma in absence of diabetes mellitus and chronic renal failure. Patient was a known operated case of well differentiated squamous cell carcinoma with no post-operative chemotherapy. The lesions were multiple, umbilicated papules on the lower extremities and back. Dermoscopy was helpful. Bhardwaj et al. described a case of acquired perforating dermatoses with cutaneous neurofibroma.¹² A solitary nodule was seen on the chest wall which exhibited the features of neurofibroma composed of proliferation of Schwann cells and fibroblasts. Acquired perforating dermatoses occurrence in patients with systemic mycosis with features of adrenal insufficiency was reported by Choudhary et al. The classical skin eruptions were found over the extensor surface of the extremities along with hepatosplenomegaly.

Our present study correlates well with Kawami et al., Faver et al. and Satti et al.^{1,2,5} [Table 2] The common systemic disease was Diabetes Mellitus with

itchy hyperkeratotic papules primarily on the lower extremities.^{16,18,19} Pruritus was the commonest symptom which impaired the quality of patients' life. Hence early recognition of this entity is necessary. Perforating dermatoses should be considered in a skin ulcer with keratotic plug and the diagnosis should be based on histopathology features along with special stain. Acquired perforating collagenosis should be differentiated from other perforating dermatoses.²⁰ In Kyrles disease, extrafollicular plug with deep seated perforation in the invagination is seen. While elastosis perforans there are thickened elastic fibres around epidermal invagination. In perforating folliculitis the epidermal invagination is seen in relation to vellus hair.

6. Conclusion

Acquired perforating dermatoses are rare forms of perforating dermatoses associated with systemic diseases. It is still misdiagnosed clinically and hence should be included in the differential diagnosis when ulcer with keratotic plug is noted. However, increase awareness for recognition of this entity is also necessary. The management of the coexisting disease is of prime importance as there is no effective treatment. Thus clinic-pathological co-relation is crucial for approach to the diagnosis of the disease.

7. Source of funding

None.

8. Conflict of interest

None.

References

1. Satti MB, Aref AH, Raddadi AA, Hamdi FAAG. Acquired reactive perforating collagenosis: a clinicopathological study of 15 cases. *J Euro Acad Dermatol Venerol*. 2010;24(2):223–227.
2. Kawakami T, Saito R. Acquired reactive perforating collagenosis associated with diabetes mellitus: eight cases that meet Favre's criteria. *Br J Dermatol*. 1999;140(3):521–524.
3. Ataseven S, Kayacetin. Acquired Reactive Perforating Collagenosis. *Eurasian J Med*. 2012;44(1):51–53.
4. Vashita R, Agrawal US, Mathur N. Acquired reactive perforating dermatosis. *Indian J Dermatol Venereol Leprol*. 1993;59:251–253.
5. Favre IR, Daoud MS, SuWP. Acquired reacting perforating collagenosis: Report of six cases and review of literature. *J An Acad Dermatol*. 1994;30:575–580.
6. Elder E, Elenitsas R, Murphy FG. *Levers Histopathology of the skin*; Tenth edition ; p. 391–396. Tenth edition.
7. Fel C, Wang Y, Gong Y. Acquired reactive perforating collagenosis: A report of typical case. *Med*. 2016;95(30):4305.
8. Dhillon K, Uroos F, Singh I. Reactive perforating collagenosis. *Int J Adv Medicine*. 2014;1:49–51.
9. M Kikuchi N OH, Yamamoto T. Acquired reacting collagenosis: a rare association with dermatomyositis. *Acta Derm Venereol*. 2013;93:735.
10. Bhat YJ, Manzoor S, Qayoom S. Familial reactive perforating collagenosis. *Indian J Dermatol*. 2009;54:334.
11. Karpouzis A, Giatromanolaki A, Sirvridis E. Acquired reacting perforating collagenosis: current status. *J Dermatol*. 2010;37:585–592.
12. Bhardwaj A, Kishore S, Thakur B, Kudesia S. Perforating collagenosis with cutaneous neurofibroma. *Egypt J Dermatol Venerol*. 2015;35:45–47.
13. Choudhary N, Aggarwal I, Dutta D. Acquired perforating dermatosis and Addison's disease due to disseminated histoplasmosis. *Dermato-Endocrinol*;2013(2):5–5.
14. Hong SB, Park JH, Ihm CG, Kim NI. Acquired Perforating Dermatoses in Patients with Chronic Renal Failure and Diabetes Mellitus. *J Korean Med Sci*;200419(2):283–288.
15. Yadav M, Sangal B, Bhargav P, Jai P, Goyal M. Reactive perforating collagenosis. *Indian J Pathol Microbiol*. 2009;52:106–107.
16. Lynde CB, Pratt MD. Acquired perforating dermatosis: association with diabetes and renal failure. *CMAJ*. 2009;181(9):615.
17. Kansaria J, Jerajani H, Udare S. Acquired perforating dermatosis associated with oral carcinoma: A rare association. *IOSR J Dental Medical Sciences*. 2016;15(3):13–16.
18. Imam HT, Patail H, Nabeela K, Hsu TP, and SDC. Acquired Perforating Dermatoses in a Patient on Peritoneal Dialysis: A Case Report and Review of the Literature. *Case Rep Nephrol*. 2018;.
19. Diagnosis at a Glance: Acquired Perforating Dermatoses. *Diabetes Care*. 2018;41(4):911–912.
20. Arora K, Hajirnis K, Sawant S, Gaikwad N. Perforating disorders of the skin. *Indian J Pathol Microbiol*. 2013;56(4):355–358.

Author biography

Smita Sawant Associate Professor

Nirmala Gaikwad Assistant Professor

Kalpna Hajirnis Professor

Resham Vasani Assistant Professor

Cite this article: Sawant S, Gaikwad N, Hajirnis K, Vasani R. Acquired perforating collagenosis: A clinico-pathological study of ten. *Indian J Pathol Oncol* 2019;6(4):677–681.